1 2 3 4 5 6 7 8 9 10 11 12 13 14 15 16 17 18 19 20 21 22 23 24 25 26 27 28 29 30

A 3-week-old-girl in the neonatal intensive care unit develops abdominal distension, vomiting, and blood-streaked stools. She had previously tolerated formula feeds and had normal stool and urine output. She was born at 27 weeks gestation to an 18-year-old-mother. The pregnancy was complicated by premature rupture of membranes and preterm delivery. Abdominal x-ray shows thin curvilinear areas of lucency that parallel the bowel wall lumen. Which of the following is the most likely diagnosis?

A. Duodenal atresia

B. Hirschsprung disease

C. Malrotation with volvulus

D. Necrotizing enterocolitis

E. Pyloric stenosis

Submit

A 3-week-old-girl in the neonatal intensive care unit develops abdominal distension, vomiting, and blood-streaked stools. She had previously tolerated formula feeds and had normal stool and urine output. She was born at 27 weeks gestation to an 18-year-old-mother. The pregnancy was complicated by premature rupture of membranes and preterm delivery. Abdominal x-ray shows thin curvilinear areas of lucency that parallel the bowel wall lumen. Which of the following is the most likely diagnosis?

- A. Duodenal atresia (3%)
- B. Hirschsprung disease (6%)
- C. Malrotation with volvulus (17%)
- ✓ D. Necrotizing enterocolitis (69%)
- E. Pyloric stenosis (2%)

Omitted
Correct answer
D

69%
Answered correctly

03 secs
Time Spent

02/06/2020
Last Updated

Explanation

Settings

1
2
3
4
5
6
7
8
9
10
11
12
13
14
15
16
17
18
19
20
21
22
23
24
25
26
27
28
29
30

Item 1 of 40
Question Id: 9920

Mark | Previous | Next | Full Screen | Tutorial | Lab Values | Notes | Calculator | Reverse Color | Text Zoom | Settings

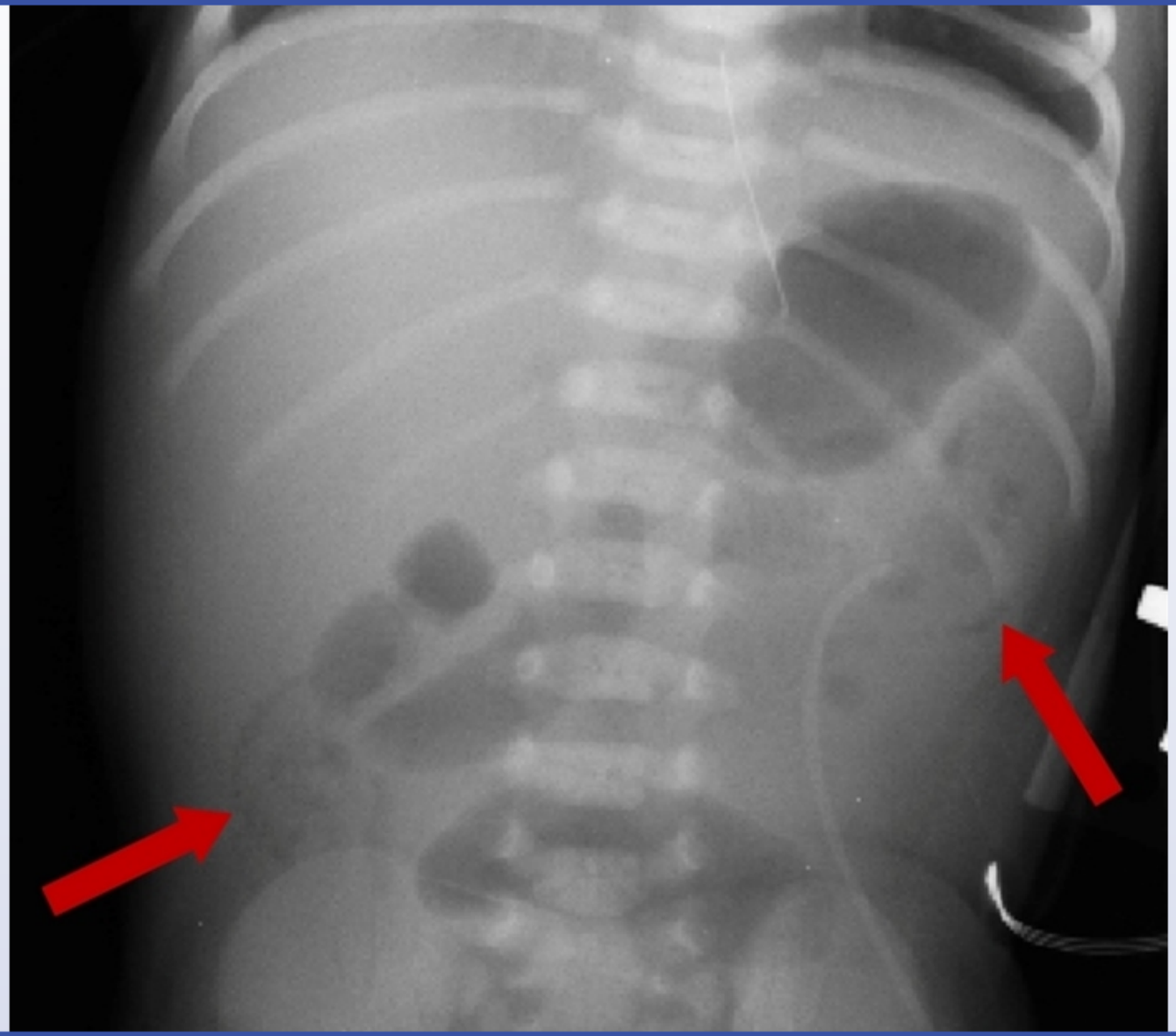

Block Time Remaining: 00:00:03
TUTOR

5 | Feedback | Suspend | End Block

This infant has **pneumatosis intestinalis** (ie, air in the bowel wall), which can be seen on abdominal x-ray as thin curvilinear areas of lucency (red arrows) that parallel the lumen. In an infant with abdominal distension and bloody stools, this finding is diagnostic for **necrotizing enterocolitis** (NEC).

NEC is one of the most frequent gastrointestinal emergencies affecting newborns. It occurs predominantly in **preterm infants** secondary to gastrointestinal and immunologic immaturity. Upon initiation of enteral feeding, bacteria are introduced into the bowel where they proliferate excessively due to compromised immune clearance. Impaired mucosal barrier function allows the bacteria to invade the bowel wall, causing inflammation and **ischemic necrosis** of the terminal ileum and colon. As the disease progresses, the bowel becomes congested and gangrenous with the formation of **intramural gas collections**.

Up to 30% of affected neonates die, especially when disease is complicated by intestinal perforation. Survivors are at risk for strictures and **bowel obstruction** secondary to fibrosis that occurs as the inflammation subsides.

(Choice A) Duodenal atresia classically presents with the double bubble sign of air in the stomach and proximal duodenal pouch. Affected infants generally have bilious emesis shortly after birth.

(Choice B) Hirschsprung disease manifests with failure to pass meconium in the first 48 hours after birth. On x-ray, the large intestine appears dilated proximal to the aganglionic portion of bowel; contrast enema will show a narrow-caliber transition zone.

(Choice C) Malrotation of the bowel occurs when the midgut does not rotate normally during the first trimester, leaving the small and large bowel malpositioned. Malrotated bowel is at high risk of obstruction and ischemia due to twisting around its blood supply (volvulus). However, the finding of pneumatosis intestinalis is more specific for necrotizing enterocolitis.

(Choice E) Pyloric stenosis is caused by hypertrophy of the pyloric sphincter and leads to gastric outlet obstruction. It presents with nonbilious vomiting after feeding and a palpable ball of muscle ("olive") in the abdomen. Pyloric stenosis is not associated with bloody stools or pneumatosis intestinalis.

Educational objective:
Necrotizing enterocolitis is one of the most common gastrointestinal emergencies affecting newborns. It is characterized by bacterial invasion and ischemic necrosis of the bowel wall, and is associated with prematurity and initiation of enteral feeding. Abdominal x-ray showing pneumatosis

Settings

Item 1 of 40
Question Id: 9920

Mark | Previous | Next | Full Screen | Tutorial | Lab Values | Notes | Calculator | Reverse Color | Text Zoom | Settings

with the formation of **intramural gas collections**.

Exhibit Display

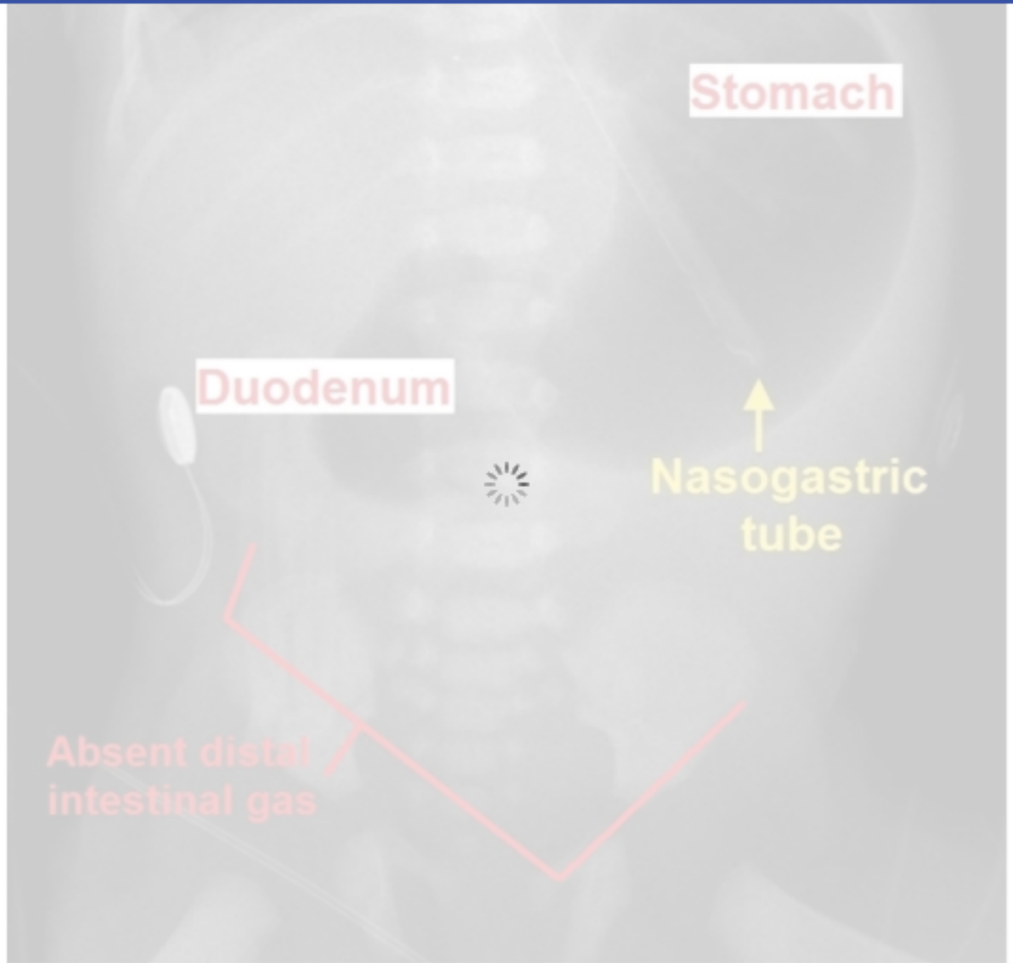

Zoom In | Zoom Out | Reset | Add To New Card | Existing Card

Block Time Remaining: 00:00:03
TUTOR

Feedback | Suspend | End Block

with the formation of **intramural gas collections**.

Up to 30% of affected neonates die, especially when disease is complicated by intestinal perforation. Survivors are at risk for strictures and **bowel obstruction** secondary to fibrosis that occurs as the inflammation subsides.

(Choice A) Duodenal atresia classically presents with the double bubble sign of air in the stomach and proximal duodenal pouch. Affected infants generally have bilious emesis shortly after birth.

(Choice B) Hirschsprung disease manifests with failure to pass meconium in the first 48 hours after birth. On x-ray, the large intestine appears dilated proximal to the aganglionic portion of bowel; contrast enema will show a narrow-caliber transition zone.

(Choice C) Malrotation of the bowel occurs when the midgut does not rotate normally during the first trimester, leaving the small and large bowel malpositioned. Malrotated bowel is at high risk of obstruction and ischemia due to twisting around its blood supply (volvulus). However, the finding of pneumatosis intestinalis is more specific for necrotizing enterocolitis.

(Choice E) Pyloric stenosis is caused by hypertrophy of the pyloric sphincter and leads to gastric outlet obstruction. It presents with nonbilious vomiting after feeding and a palpable ball of muscle ("olive") in the abdomen. Pyloric stenosis is not associated with bloody stools or pneumatosis intestinalis.

Educational objective:
Necrotizing enterocolitis is one of the most common gastrointestinal emergencies affecting newborns. It is characterized by bacterial invasion and ischemic necrosis of the bowel wall, and is associated with prematurity and initiation of enteral feeding. Abdominal x-ray showing pneumatosis intestinalis (ie, air in the bowel wall) confirms the diagnosis.

References

- A clinical perspective of necrotizing enterocolitis: past, present, and future.
- Necrotizing enterocolitis: review of state-of-the-art imaging findings with pathologic correlation.

Pathology	Gastrointestinal & Nutrition	Necrotizing enterocolitis
Subject	System	Topic

Settings

1 2 3 4 5 6 7 8 9 10 11 12 13 14 15 16 17 18 19 20 21 22 23 24 25 26 27 28 29 30

Item 1 of 40
Question Id: 9920

Mark | Previous | Next | Full Screen | Tutorial | Lab Values | Notes | Calculator | Reverse Color | Text Zoom | Settings

with the formation of **intramural gas collections**.

Exhibit Display

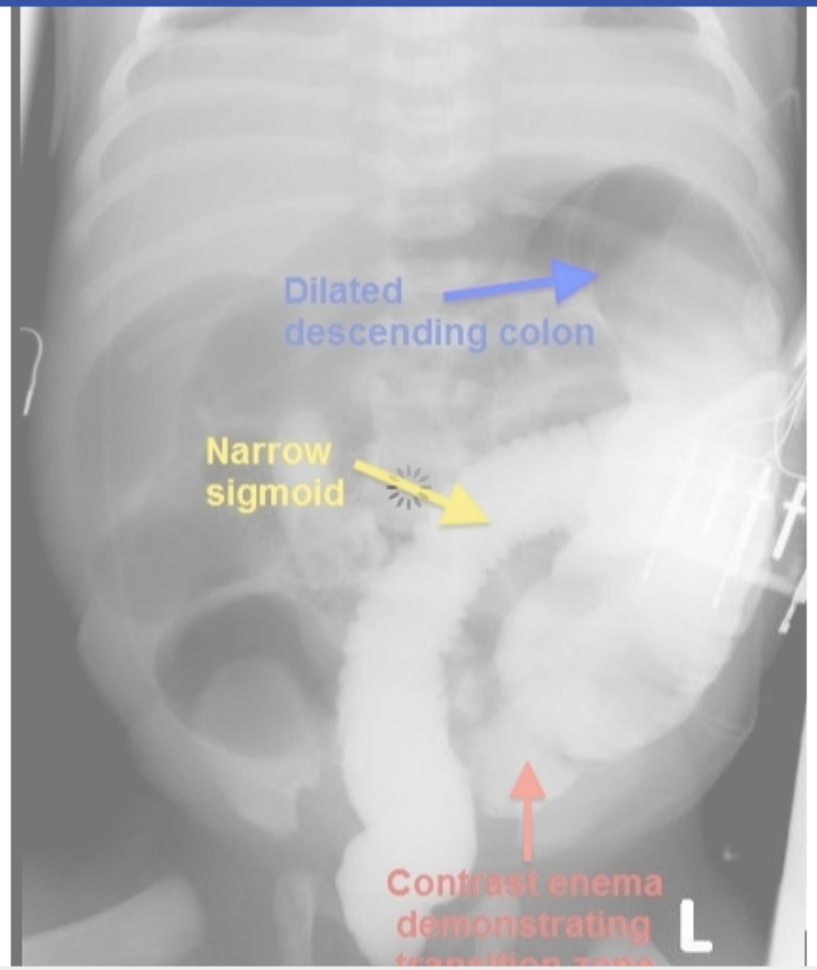

Zoom In | Zoom Out | Reset | Add To New Card | Existing Card

Block Time Remaining: 00:00:03
TUTOR

5 | Feedback | Suspend | End Block

A 21-year-old Caucasian male presents to your office with mild jaundice after a hiking trip. He had a similar episode two years ago after fasting for five days. His physical examination is unremarkable except for mild jaundice.

Liver studies

Albumin	4.2 mg/dL
Total protein, serum	6.8 g/dL
Total bilirubin	2.8 mg/dL
Direct bilirubin	0.2 mg/dL
Alkaline phosphatase	90 U/L
Aspartate aminotransferase (SGOT)	26 U/L
Alanine aminotransferase (SGPT)	32 U/L

This patient most likely suffers from:

A. Gilbert syndrome
B. Dubin-Johnson syndrome
C. Acute viral hepatitis B
D. Acute viral hepatitis C
E. Acute alcoholic hepatitis
F. Wilson's disease

Liver studies

Albumin	4.2 mg/dL
Total protein, serum	6.8 g/dL
Total bilirubin	2.8 mg/dL
Direct bilirubin	0.2 mg/dL
Alkaline phosphatase	90 U/L
Aspartate aminotransferase (SGOT)	26 U/L
Alanine aminotransferase (SGPT)	32 U/L

This patient most likely suffers from:

A. Gilbert syndrome
B. Dubin-Johnson syndrome
C. Acute viral hepatitis B
D. Acute viral hepatitis C
E. Acute alcoholic hepatitis
F. Wilson's disease

Submit

Liver studies

Albumin	4.2 mg/dL
Total protein, serum	6.8 g/dL
Total bilirubin	2.8 mg/dL
Direct bilirubin	0.2 mg/dL
Alkaline phosphatase	90 U/L
Aspartate aminotransferase (SGOT)	26 U/L
Alanine aminotransferase (SGPT)	32 U/L

This patient most likely suffers from:

- ✓ A. Gilbert syndrome (81%)
- B. Dubin-Johnson syndrome (11%)
- C. Acute viral hepatitis B (2%)
- D. Acute viral hepatitis C (1%)
- E. Acute alcoholic hepatitis (1%)
- F. Wilson's disease (1%)

Omitted
Correct answer

81%
Answered correctly

03 secs
Time Spent

02/03/2020
Last Updated

Explanation

The hepatic metabolism of bilirubin occurs in the following four stages: uptake from the bloodstream; storage within the hepatocyte; conjugation with glucuronic acid; and biliary excretion. In the normal individual, serum total bilirubin is 0.2-1 mg/dL, of which < 0.2 mg/dL is the direct fraction. Typically, elevated conjugated bilirubin levels are suggestive of hepatobiliary disease (eg, cirrhosis or hepatitis) because the bilirubin conjugates will reflux back into the plasma when the secretion of conjugated bilirubin into the bile is slowed. In contrast, elevated unconjugated bilirubin levels typically indicate increased bilirubin formation (such as that seen in hemolysis) or a slowing in bilirubin conjugation (such as that seen in this patient, who has Gilbert syndrome).

Gilbert syndrome is a common familial disorder of bilirubin glucuronidation in which the production of UDP glucuronyl transferases (enzymes that mediate glucuronidation of various substances) is reduced. Approximately 9% of individuals in Western countries are homozygous for this mutation, with another 30% heterozygous and asymptomatic. The diagnosis is suggested in those patients with no apparent liver disease who have mild unconjugated hyperbilirubinemia thought to be provoked by one of the classic triggers. Examples of such triggers include hemolysis, fasting, physical exertion, febrile illness, stress, and fatigue. Presumptive diagnosis can be made when the unconjugated hyperbilirubinemia persists with repeat testing, but liver function tests, complete blood count, blood smear, and reticulocyte count are normal.

(Choice B) Individuals with the rare Dubin-Johnson syndrome have predominantly conjugated chronic hyperbilirubinemia that is not associated with hemolysis. For the diagnosis to be made, conjugated hyperbilirubinemia with a direct bilirubin fraction of at least 50% and an otherwise normal liver function profile must be present.

(Choices C and D) Expected laboratory findings in a patient with acute viral hepatitis include significant elevations in ALT and AST (with ALT > AST), followed by rises in bilirubin and alkaline phosphatase.

(Choice E) Alcoholic hepatitis is typically associated with a significant drinking history and is commonly characterized by an AST:ALT ratio greater than 2:1.

(Choice F) Wilson's disease is the likely diagnosis in a patient younger than 30 years old with unexplained chronic hepatitis (elevated AST and ALT). The presence of low serum ceruloplasmin and increased urinary copper excretion or Kayser-Fleischer rings provides diagnostic confirmation.

Gilbert syndrome is a common familial disorder of bilirubin glucuronidation in which the production of UDP glucuronyl transferases (enzymes that mediate glucuronidation of various substances) is reduced. Approximately 9% of individuals in Western countries are homozygous for this mutation, with another 30% heterozygous and asymptomatic. The diagnosis is suggested in those patients with no apparent liver disease who have mild unconjugated hyperbilirubinemia thought to be provoked by one of the classic triggers. Examples of such triggers include hemolysis, fasting, physical exertion, febrile illness, stress, and fatigue. Presumptive diagnosis can be made when the unconjugated hyperbilirubinemia persists with repeat testing, but liver function tests, complete blood count, blood smear, and reticulocyte count are normal.

(Choice B) Individuals with the rare Dubin-Johnson syndrome have predominantly conjugated chronic hyperbilirubinemia that is not associated with hemolysis. For the diagnosis to be made, conjugated hyperbilirubinemia with a direct bilirubin fraction of at least 50% and an otherwise normal liver function profile must be present.

(Choices C and D) Expected laboratory findings in a patient with acute viral hepatitis include significant elevations in ALT and AST (with ALT > AST), followed by rises in bilirubin and alkaline phosphatase.

(Choice E) Alcoholic hepatitis is typically associated with a significant drinking history and is commonly characterized by an AST:ALT ratio greater than 2:1.

(Choice F) Wilson's disease is the likely diagnosis in a patient younger than 30 years old with unexplained chronic hepatitis (elevated AST and ALT). The presence of low serum ceruloplasmin and increased urinary copper excretion or Kayser-Fleischer rings provides diagnostic confirmation.

Educational Objective:
Gilbert syndrome is the likely diagnosis in patients with no apparent liver disease who have mild unconjugated hyperbilirubinemia that appears provoked by one of the classic triggers.

Pathology	Gastrointestinal & Nutrition	Gilbert syndrome
Subject	System	Topic

Copyright © UWorld. All rights reserved.

A 32-year-old man with mild abdominal discomfort and anorexia admits consuming large amounts of alcohol recently. He undergoes a liver biopsy, which shows the light microscopy findings seen in the image below.

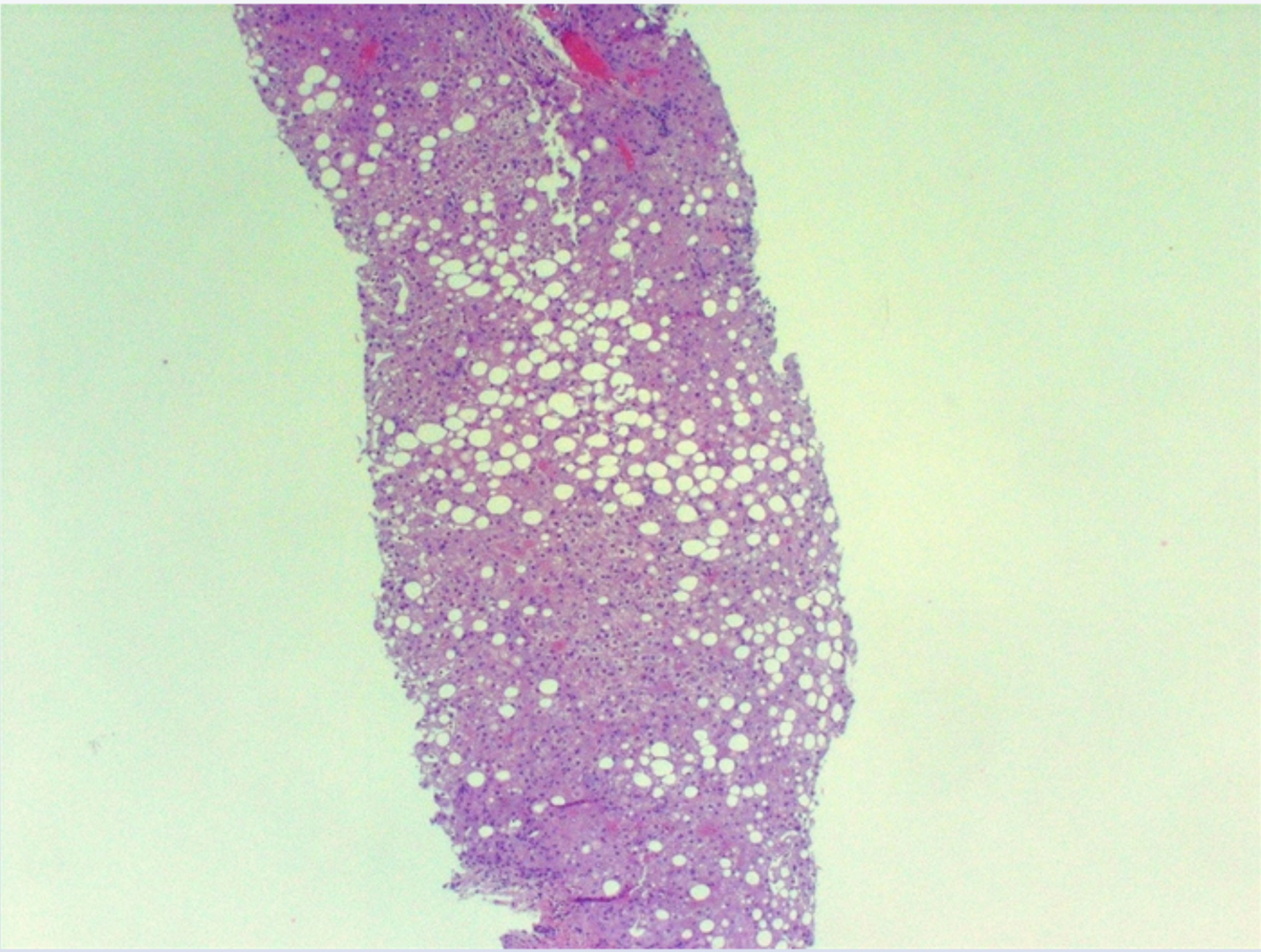

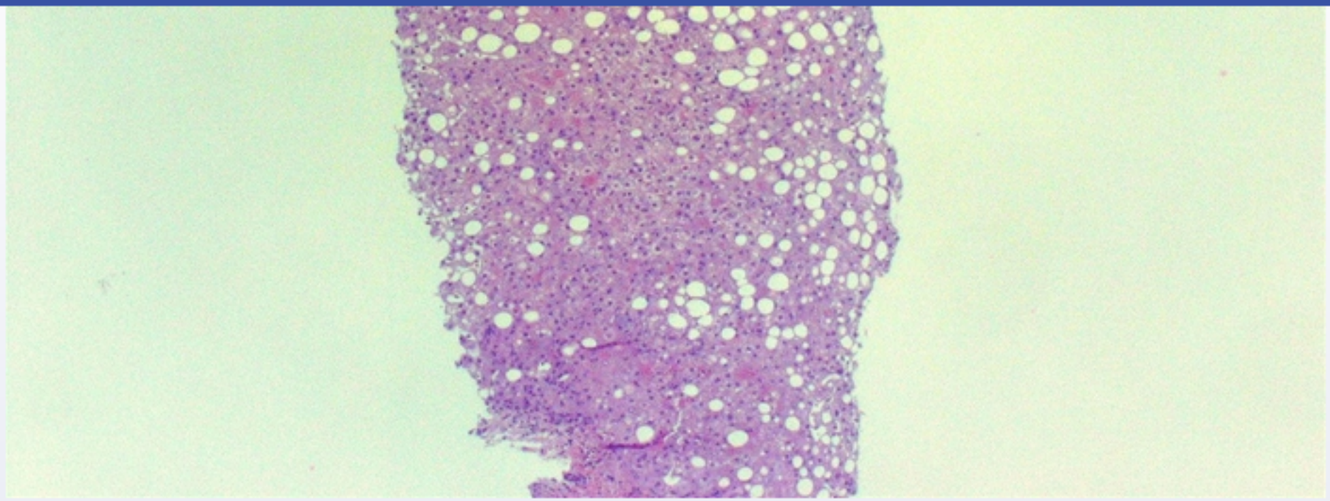

Which of the following is the most likely cause of this patient's condition?

- A. Decreased triglyceride synthesis
- B. Decreased free fatty acid oxidation
- C. Increased phospholipid catabolism
- D. Enhanced lipoprotein assembly
- E. Increased gluconeogenesis
- F. Increased glucose uptake into cells

Submit

1 2 3 4 5 6 7 8 9 10 11 12 13 14 15 16 17 18 19 20 21 22 23 24 25 26 27 28 29 30

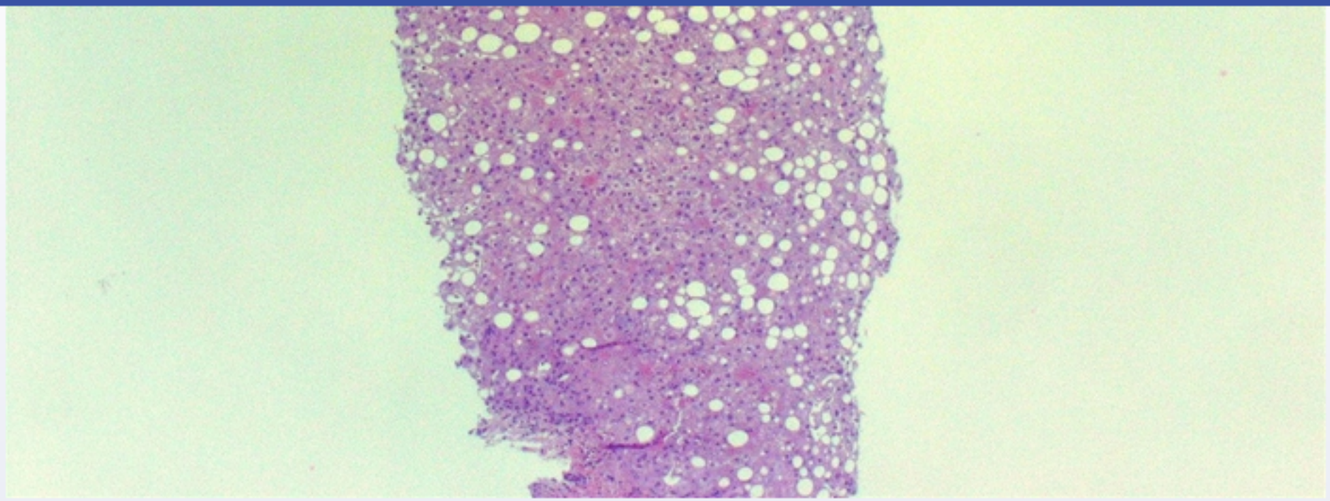

Which of the following is the most likely cause of this patient's condition?

- A. Decreased triglyceride synthesis (5%)
- ✓ B. Decreased free fatty acid oxidation (68%)
- C. Increased phospholipid catabolism (6%)
- D. Enhanced lipoprotein assembly (13%)
- E. Increased gluconeogenesis (3%)
- F. Increased glucose uptake into cells (2%)

Omitted
Correct answer

68%
Answered correctly

04 secs
Time Spent

04/10/2020
Last Updated

Explanation

Hepatic steatosis is a nonspecific condition characterized by triglyceride accumulation within the hepatocellular cytoplasm. The pathogenesis of alcohol-induced hepatic steatosis appears related primarily to a decrease in free fatty acid oxidation secondary to excess NADH production by the 2 major alcohol metabolism enzymes, alcohol dehydrogenase and aldehyde dehydrogenase. Contributing pathogenetic factors include impaired lipoprotein assembly and secretion and an increase in peripheral fat catabolism. As seen in the image, fatty tissue that is routinely fixed will microscopically demonstrate cytoplasmic vacuoles as the lipid is dissolved during histologic processing. In frozen sections, lipids can be demonstrated by staining with oil red O or Sudan black.

(Choice A) Alcohol-induced hepatic steatosis is associated with increased (not decreased) triglyceride synthesis.

(Choice C) Increased peripheral fat (not phospholipid) catabolism is associated with alcohol-induced hepatic steatosis.

(Choice D) Impaired (not enhanced) lipoprotein assembly is associated with alcohol-induced hepatic steatosis.

(Choice E) The alteration of the hepatic NAD/NADH ratio in alcoholics induces fatty liver through inhibition of gluconeogenesis and fatty acid oxidation.

(Choice F) Increased glucose uptake into cells occurs when high insulin levels are circulating; this condition is not associated with hepatic steatosis.

Educational objective:
The pathogenesis of alcohol-induced hepatic steatosis appears related primarily to a decrease in free fatty acid oxidation secondary to excess NADH production by the 2 major alcohol metabolism enzymes, alcohol dehydrogenase and aldehyde dehydrogenase.

Pathology	Gastrointestinal & Nutrition	Alcoholic liver disease
Subject	System	Topic

Copyright © UWorld. All rights reserved.

A 73-year-old man comes to the clinic with epigastric pain that starts 30-40 minutes after meals and does not respond to antacids. The pain is non-radiating and is graded 6/10 in intensity. The patient has lost more than 4.5 kg (10 lb) over the last few months, which he attributes to eating less due to his fear of the pain. He has no vomiting, diarrhea, or urinary symptoms. His past medical history is significant for hypertension, hyperlipidemia, coronary artery bypass grafting, and right-sided carotid endarterectomy. He has smoked a pack of cigarettes daily for 32 years. Upper gastrointestinal endoscopy shows no abnormalities. The underlying pathophysiology of this patient's disease process is most similar to which of the following conditions?

- A. Aortic dissection
- B. Diffuse esophageal spasm
- C. Peptic ulcer disease
- D. Pulmonary embolism
- E. Stable angina

Submit

A 73-year-old man comes to the clinic with epigastric pain that starts 30-40 minutes after meals and does not respond to antacids. The pain is non-radiating and is graded 6/10 in intensity. The patient has lost more than 4.5 kg (10 lb) over the last few months, which he attributes to eating less due to his fear of the pain. He has no vomiting, diarrhea, or urinary symptoms. His past medical history is significant for hypertension, hyperlipidemia, coronary artery bypass grafting, and right-sided carotid endarterectomy. He has smoked a pack of cigarettes daily for 32 years. Upper gastrointestinal endoscopy shows no abnormalities. The underlying pathophysiology of this patient's disease process is most similar to which of the following conditions?

A. Aortic dissection (2%)

B. Diffuse esophageal spasm (9%)

C. Peptic ulcer disease (35%)

D. Pulmonary embolism (3%)

✓ E. Stable angina (49%)

Omitted
Correct answer
E

49%
Answered correctly

01 sec
Time Spent

02/05/2020
Last Updated

Explanation

This patient's **postprandial epigastric pain** and associated **food aversion/weight loss** in the setting of generalized atherosclerosis (eg, coronary and carotid artery disease) is consistent with **chronic mesenteric ischemia**.

When atherosclerosis involves the mesenteric arteries, the bowel can suffer from **diminished blood supply**. Intestinal hypoperfusion, which can

This patient's **postprandial epigastric pain** and associated **food aversion/weight loss** in the setting of generalized atherosclerosis (eg, coronary and carotid artery disease) is consistent with **chronic mesenteric ischemia**.

When atherosclerosis involves the mesenteric arteries, the bowel can suffer from **diminished blood supply**. Intestinal hypoperfusion, which can be very painful, is especially pronounced within an hour after meals when more blood is needed for the digestion/absorption of nutrients (intestinal angina). This is **analogous to stable cardiac angina**, chest pain that occurs with physical exertion due to increased myocardial oxygen demand. The diagnosis can be made with duplex ultrasonography or angiography showing high-grade stenosis in the celiac and mesenteric arteries.

(Choice A) Aortic dissection results from an aortic intimal tear with formation of a false lumen that can propagate and obstruct the vessels branching off the aorta (eg, renal, splanchnic, spinal, lower limb). A similar process would be more likely to cause acute end-organ damage (eg, cerebral infarction) rather than chronic, episodic ischemia.

(Choice B) Diffuse esophageal spasm is a motility disorder characterized by episodic, painful, non-propulsive esophageal smooth muscle contraction. Biliary colic is similar to esophageal spasm in that gallbladder contraction against an obstructed cystic duct results in postprandial epigastric pain.

(Choice C) Peptic ulcer disease is characterized by gastrointestinal erosions/ulcerations and is typically due to *Helicobacter pylori* infection or nonsteroidal anti-inflammatory drug use. This patient's pain did not respond to antacids and his upper endoscopy is normal, so he is unlikely to have a condition associated with peptic ulcers.

(Choice D) Pulmonary embolism is often due to an embolic blood clot lodging in the branches of the pulmonary artery, resulting in acute pulmonary ischemia/infarction. A similar pathogenesis accounts for acute mesenteric ischemia, which can occur with superior mesenteric artery embolism. This condition is more likely to cause sudden, severe abdominal pain rather than recurrent postprandial abdominal pain with food aversion.

Educational objective:
Chronic mesenteric ischemia is characterized by atherosclerosis of the mesenteric arteries, resulting in diminished blood flow to the intestine after meals. This causes postprandial epigastric pain (intestinal angina) with associated food aversion/weight loss. Its pathogenesis is similar to angina pectoris.

(Choice A) Aortic dissection results from an aortic intimal tear with formation of a false lumen that can propagate and obstruct the vessels branching off the aorta (eg, renal, splanchnic, spinal, lower limb). A similar process would be more likely to cause acute end-organ damage (eg, cerebral infarction) rather than chronic, episodic ischemia.

(Choice B) Diffuse esophageal spasm is a motility disorder characterized by episodic, painful, non-propulsive esophageal smooth muscle contraction. Biliary colic is similar to esophageal spasm in that gallbladder contraction against an obstructed cystic duct results in postprandial epigastric pain.

(Choice C) Peptic ulcer disease is characterized by gastrointestinal erosions/ulcerations and is typically due to *Helicobacter pylori* infection or nonsteroidal anti-inflammatory drug use. This patient's pain did not respond to antacids and his upper endoscopy is normal, so he is unlikely to have a condition associated with peptic ulcers.

(Choice D) Pulmonary embolism is often due to an embolic blood clot lodging in the branches of the pulmonary artery, resulting in acute pulmonary ischemia/infarction. A similar pathogenesis accounts for acute mesenteric ischemia, which can occur with superior mesenteric artery embolism. This condition is more likely to cause sudden, severe abdominal pain rather than recurrent postprandial abdominal pain with food aversion.

Educational objective:

Chronic mesenteric ischemia is characterized by atherosclerosis of the mesenteric arteries, resulting in diminished blood flow to the intestine after meals. This causes postprandial epigastric pain (intestinal angina) with associated food aversion/weight loss. Its pathogenesis is similar to angina pectoris.

References

- Chronic mesenteric ischemia: diagnosis and management.

Pathology	Gastrointestinal & Nutrition	Mesenteric ischemia
Subject	System	Topic

Copyright © UWorld. All rights reserved.

A 44-year-old man with a history of heavy alcohol consumption comes to the emergency department with a nosebleed after getting into a fight while intoxicated. Continuous local pressure is applied and his bleeding resolves within 30 minutes. A detailed physical examination is performed after the bleeding subsides and shows distended paraumbilical veins, ascites, and a flapping hand tremor on wrist extension. Which of the following laboratory findings would be most indicative of a poor prognosis for this patient?

A. High aspartate aminotransferase

B. High fibrinogen levels

C. High gamma glutamyl transferase

D. Prolonged bleeding time

E. Prolonged prothrombin time

Submit

A 44-year-old man with a history of heavy alcohol consumption comes to the emergency department with a nosebleed after getting into a fight while intoxicated. Continuous local pressure is applied and his bleeding resolves within 30 minutes. A detailed physical examination is performed after the bleeding subsides and shows distended paraumbilical veins, ascites, and a flapping hand tremor on wrist extension. Which of the following laboratory findings would be most indicative of a poor prognosis for this patient?

- A. High aspartate aminotransferase (19%)
- B. High fibrinogen levels (3%)
- C. High gamma glutamyl transferase (14%)
- D. Prolonged bleeding time (5%)
- ✓ E. Prolonged prothrombin time (56%)

Omitted
Correct answer
E

56%
Answered correctly

01 sec
Time Spent

05/02/2020
Last Updated

Explanation

Laboratory abnormalities in cirrhosis	
Indicators	**Impaired biosynthetic capacity** • Elevated prothrombin time • Hypoalbuminemia

Laboratory abnormalities in cirrhosis	
Indicators of liver function	**Impaired biosynthetic capacity** • Elevated prothrombin time • Hypoalbuminemia **Impaired transport and metabolic capacity** • Elevated bilirubin
Indicators of liver injury	**Markers of hepatocyte injury** • Elevated aspartate & alanine aminotransferases (AST usually >ALT) **Markers of cholestasis** • Elevated alkaline phosphatase • Elevated gamma-glutamyl transpeptidase
Other	• Thrombocytopenia (due to splenic sequestration of platelets)

©USMLEWorld, LLC

This patient has clinical findings consistent with alcoholic cirrhosis, namely signs of portal hypertension (ascites/caput medusa) and hepatic encephalopathy (asterixis). Alcohol-associated hepatic injury evolves through the stages of alcoholic steatosis (reversible), alcoholic hepatitis (reversible), and alcoholic cirrhosis (irreversible).

Laboratory findings in cirrhosis reflect both hepatocellular/biliary injury and loss of hepatic function. Hepatocyte injury causes a release of intracellular enzymes and an increase in serum transaminases; biliary injury is reflected by increases in alkaline phosphatase and gamma-glutamyl transpeptidase (GGT). Although these laboratory studies are indicative of ongoing hepatobiliary injury, they do not provide information on the liver's functional reserve, a key determinant of prognosis in patients with cirrhosis. Serum albumin levels and prothrombin time (PT) are better

© USMLEWorld, LLC

This patient has clinical findings consistent with alcoholic cirrhosis, namely signs of portal hypertension (ascites/caput medusa) and hepatic encephalopathy (asterixis). Alcohol-associated hepatic injury evolves through the stages of alcoholic steatosis (reversible), alcoholic hepatitis (reversible), and alcoholic cirrhosis (irreversible).

Laboratory findings in cirrhosis reflect both hepatocellular/biliary injury and loss of hepatic function. Hepatocyte injury causes a release of intracellular enzymes and an increase in serum transaminases; biliary injury is reflected by increases in alkaline phosphatase and gamma-glutamyl transpeptidase (GGT). Although these laboratory studies are indicative of ongoing hepatobiliary injury, they do not provide information on the liver's functional reserve, a key determinant of prognosis in patients with cirrhosis. Serum albumin levels and prothrombin time (PT) are better indicators of the liver's biosynthetic function, and its ability to transport and metabolize organic anions is reflected by the serum bilirubin level. Hypoalbuminemia, elevated bilirubin levels, and prolonged PT are signs of inadequate liver function (eg, liver failure) and indicate a poor prognosis in cirrhotic patients. For this reason, they are included in multiple scoring systems used to assess the severity of liver failure and need for transplantation.

(Choice A) A high aspartate aminotransferase (AST) indicates hepatocellular injury and release of intracellular enzymes into the blood. AST is classically elevated to more than 2 times the level of alanine aminotransferase in alcoholic liver disease. Transaminase elevations do not reflect liver function and do not predict outcomes; these enzymes can be transiently elevated by a number of self-limited processes.

(Choice B) Fibrinogen is a coagulation factor and an acute phase protein. Liver fibrinogen synthesis is increased in response to infection or acute inflammation and diminished in liver failure. Therefore, low fibrinogen levels would be expected in liver failure.

(Choice C) When the alkaline phosphatase is elevated, serum GGT measurements can differentiate whether the cause is biliary disease or an alternate cause such as bone disease. GGT elevations are more specific for biliary injury.

(Choice D) The bleeding time is a measure of platelet function (not liver synthetic function) and is often prolonged in severe alcoholic liver disease, although with a fair degree of variance. Thrombocytopenia in alcoholism develops due to both direct toxic effects of alcohol on the bone marrow and hypersplenism with splenic sequestration of platelets.

Educational objective:

Increased aspartate aminotransferase and alanine aminotransferase are indicators of hepatocellular damage, and increased alkaline phosphatase

the liver's functional reserve, a key determinant of prognosis in patients with cirrhosis. Serum albumin levels and prothrombin time (PT) are better indicators of the liver's biosynthetic function, and its ability to transport and metabolize organic anions is reflected by the serum bilirubin level. Hypoalbuminemia, elevated bilirubin levels, and prolonged PT are signs of inadequate liver function (eg, liver failure) and indicate a poor prognosis in cirrhotic patients. For this reason, they are included in multiple scoring systems used to assess the severity of liver failure and need for transplantation.

(Choice A) A high aspartate aminotransferase (AST) indicates hepatocellular injury and release of intracellular enzymes into the blood. AST is classically elevated to more than 2 times the level of alanine aminotransferase in alcoholic liver disease. Transaminase elevations do not reflect liver function and do not predict outcomes; these enzymes can be transiently elevated by a number of self-limited processes.

(Choice B) Fibrinogen is a coagulation factor and an acute phase protein. Liver fibrinogen synthesis is increased in response to infection or acute inflammation and diminished in liver failure. Therefore, low fibrinogen levels would be expected in liver failure.

(Choice C) When the alkaline phosphatase is elevated, serum GGT measurements can differentiate whether the cause is biliary disease or an alternate cause such as bone disease. GGT elevations are more specific for biliary injury.

(Choice D) The bleeding time is a measure of platelet function (not liver synthetic function) and is often prolonged in severe alcoholic liver disease, although with a fair degree of variance. Thrombocytopenia in alcoholism develops due to both direct toxic effects of alcohol on the bone marrow and hypersplenism with splenic sequestration of platelets.

Educational objective:
Increased aspartate aminotransferase and alanine aminotransferase are indicators of hepatocellular damage, and increased alkaline phosphatase and gamma-glutamyl transpeptidase indicate biliary injury. Serum albumin levels, bilirubin levels, and prothrombin time are reflective of liver function and are of greatest prognostic significance in patients with cirrhosis.

Pathology	Gastrointestinal & Nutrition	Cirrhosis
Subject	System	Topic

Copyright © UWorld. All rights reserved.

Exhibit Display

Clinical features of cirrhosis	
Symptoms	• Nonspecific symptoms (eg, anorexia, fatigue, muscle cramps) • Jaundice & pruritus • Upper gastrointestinal bleeding • Encephalopathy (eg, confusion, sleep disturbances) • **Women**: Amenorrhea, irregular menses, anovulation • **Men**: Hypogonadism (eg, decreased libido, erectile dysfunction, loss of axillary & pubic hair)
Physical examination	• **Skin**: Telangiectasias, caput medusae • **Breast**: Gynecomastia (usually bilateral but can be unilateral) • **Abdomen**: Ascites, firm or nodular liver, splenomegaly • **Genitourinary**: Testicular atrophy • **Extremities**: Palmar erythema, Muehrcke &/or Terry nails, Dupuytren contracture, clubbing

©UWorld

Zoom In | Zoom Out | Reset | Add To New Card | Existing Card

classically elevated to more than 2 times the level of alanine aminotransferase in alcoholic liver disease. Transaminase elevations do not reflect

A 68-year-old woman is evaluated after recurrent episodes of bright red blood per rectum. She has had no abdominal pain, nausea, vomiting, or hematemesis. Her medical conditions include hypertension and obesity. She is a smoker, has a sedentary lifestyle, and consumes processed food and red meat frequently. Abdominal examination shows no abnormalities. Colonoscopy reveals numerous mucosal outpouchings in the sigmoid colon, and sigmoid colectomy is performed. Histopathology of this patient's colonic lesions is most likely to reveal which of the following findings?

- A. Absence of muscularis propria
- B. Ectopic gastric mucosa
- C. Neoplastic mucosal growth
- D. Neural plexus lacking ganglion cells
- E. Normal colonic layers

Submit

A 68-year-old woman is evaluated after recurrent episodes of bright red blood per rectum. She has had no abdominal pain, nausea, vomiting, or hematemesis. Her medical conditions include hypertension and obesity. She is a smoker, has a sedentary lifestyle, and consumes processed food and red meat frequently. Abdominal examination shows no abnormalities. Colonoscopy reveals numerous mucosal outpouchings in the sigmoid colon, and sigmoid colectomy is performed. Histopathology of this patient's colonic lesions is most likely to reveal which of the following findings?

- ✓ A. Absence of muscularis propria (47%)
- B. Ectopic gastric mucosa (3%)
- C. Neoplastic mucosal growth (25%)
- D. Neural plexus lacking ganglion cells (1%)
- E. Normal colonic layers (21%)

Omitted
Correct answer
A

47%
Answered correctly

02 secs
Time Spent

02/23/2020
Last Updated

Explanation

True & false diverticula

True diverticulum	Pseudodiverticulum

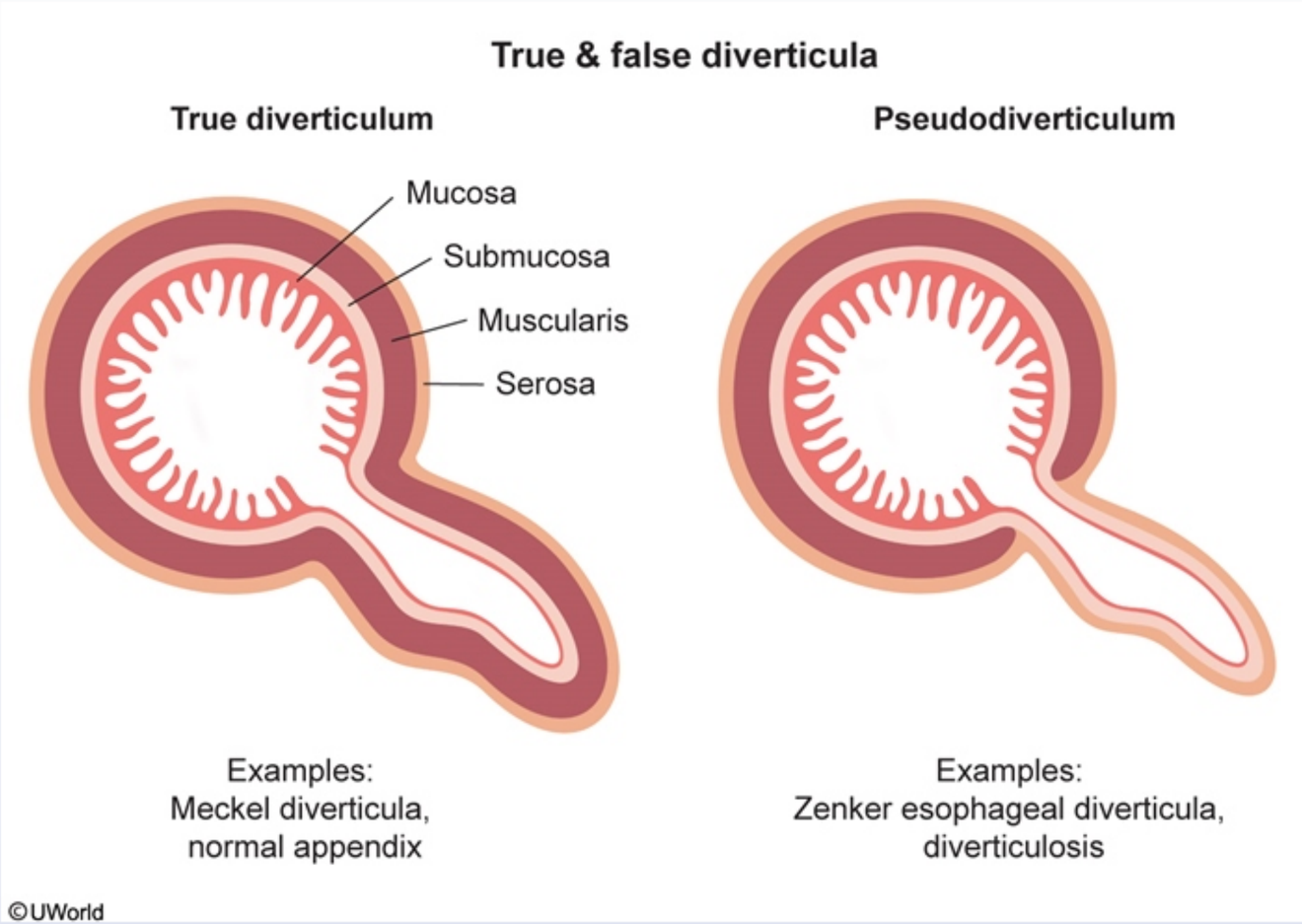

This elderly patient with hematochezia and abnormal outpouchings from the colonic lumen has diverticulosis. **Diverticulosis** most commonly affects the sigmoid colon and is usually seen in individuals age >60. Most patients are asymptomatic, but some may present with **painless hematochezia** due to disruption of the arterioles (vasa recta) adjacent to the diverticula. Diverticula can also become inflamed (ie, diverticulitis), causing left lower quadrant abdominal pain, low-grade fever, and constipation or diarrhea.

Diverticula of the gastrointestinal tract may be classified according to morphology: true diverticula include all 3 layers of the gut wall and are often

©UWorld

This elderly patient with hematochezia and abnormal outpouchings from the colonic lumen has diverticulosis. **Diverticulosis** most commonly affects the sigmoid colon and is usually seen in individuals age >60. Most patients are asymptomatic, but some may present with **painless hematochezia** due to disruption of the arterioles (vasa recta) adjacent to the diverticula. Diverticula can also become inflamed (ie, diverticulitis), causing left lower quadrant abdominal pain, low-grade fever, and constipation or diarrhea.

Diverticula of the gastrointestinal tract may be classified according to morphology; true diverticula include all 3 layers of the gut wall and are often formed during embryologic development. **False diverticula** occur when the **mucosa and submucosa herniate** through areas of **focal weakness in the muscularis**. Exaggerated contractions of colonic smooth muscle segments are responsible for colonic diverticulosis; the resultant increased intraluminal pressure causes herniation and false diverticula formation. Most diverticula acquired during adult life are false (eg, Zenker diverticulum of the upper esophagus).

(Choices B and E) Congenital colonic diverticulosis and Meckel diverticula are formed during embryologic development and are true diverticula containing all three layers of the gut wall. Congenital colonic diverticula are extremely rare and typically occur as a single, large diverticulum. Meckel diverticula often contain heterotopic gastric or pancreatic mucosa, and may cause bleeding, but are located in the small intestine; symptoms (ie, pain, nausea, vomiting) typically present in early childhood.

(Choice C) Neoplastic mucosal growth causes colonic polyps, which are solid protuberances into the colonic lumen (rather than the outpouching away from the lumen seen in diverticulosis).

(Choice D) Congenital aganglionic megacolon (Hirschsprung disease) results from the failure of neural crest cells to migrate to the colon, resulting in an aganglionic segment and severe constipation. This disease manifests in infancy with failure to pass meconium.

Educational objective:
Colonic diverticula often involve the sigmoid colon and develop due to exaggerated contractions of colonic smooth muscle segments. This results in increased intraluminal pressure, causing outpouching of the mucosa and submucosa through the muscularis (false diverticula). Individuals (typically age >60) may be asymptomatic or have hematochezia or diverticulitis.

Pathology | Gastrointestinal & Nutrition | Diverticular disease

A 56-year-old man comes to the office for upper abdominal pain occurring with meals for the last month. His symptoms improve when fasting. The patient's other medical problems are coronary artery disease and osteoarthritis. His medications include aspirin, simvastatin, and acetaminophen as needed. The patient drinks 1 or 2 beers daily but does not use tobacco or illicit drugs. Upper endoscopy is performed and reveals a gastric ulcer with a smooth, rounded border and an exudative base. A biopsy of the ulcer is taken and placed into a urea-containing solution that includes phenol red, a pH indicator. Thirty minutes later, the solution has turned pink, indicating a pH increase. This test result suggests that which of the following processes is occurring?

A. Clonal proliferation of glandular cells

B. Cyclooxygenase inhibition leading to mucosal damage

C. Enzymatic production of ammonia

D. Gastrin hypersecretion leading to acid overproduction

E. Parietal cell destruction due to autoimmune disease

Submit

A 56-year-old man comes to the office for upper abdominal pain occurring with meals for the last month. His symptoms improve when fasting. The patient's other medical problems are coronary artery disease and osteoarthritis. His medications include aspirin, simvastatin, and acetaminophen as needed. The patient drinks 1 or 2 beers daily but does not use tobacco or illicit drugs. Upper endoscopy is performed and reveals a gastric ulcer with a smooth, rounded border and an exudative base. A biopsy of the ulcer is taken and placed into a urea-containing solution that includes phenol red, a pH indicator. Thirty minutes later, the solution has turned pink, indicating a pH increase. This test result suggests that which of the following processes is occurring?

- A. Clonal proliferation of glandular cells (1%)
- B. Cyclooxygenase inhibition leading to mucosal damage (6%)
- ✓ C. Enzymatic production of ammonia (83%)
- D. Gastrin hypersecretion leading to acid overproduction (5%)
- E. Parietal cell destruction due to autoimmune disease (3%)

Omitted
Correct answer
C

83%
Answered correctly

02 secs
Time Spent

04/28/2020
Last Updated

Explanation

Rapid urease test

Rapid urease test

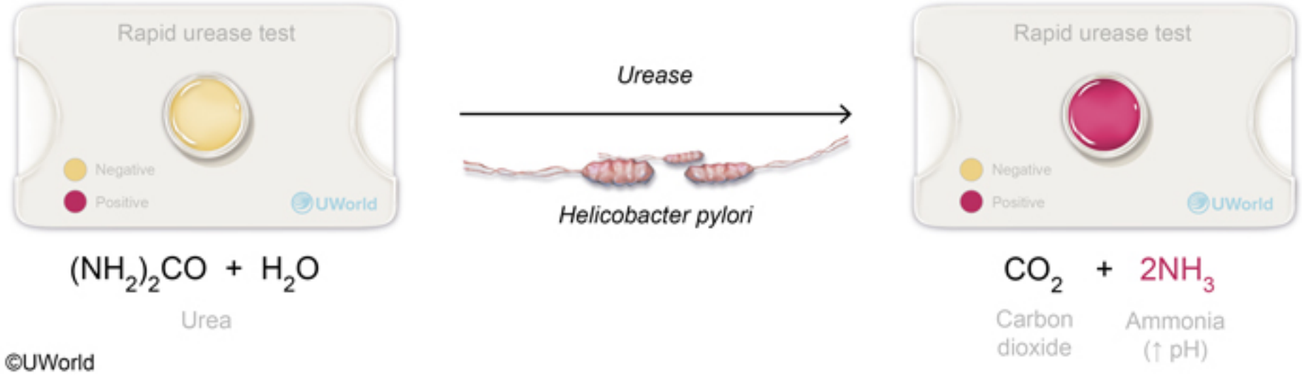

Helicobacter pylori infection is a common cause of **peptic ulcers**. During endoscopy, biopsy specimens are often obtained for direct tissue diagnosis. In contrast to the time-intensive task of culturing the bacteria, the rapid urease test can be used to quickly diagnose an active infection.

The **rapid urease test** is an indirect test for *H pylori* and relies on the bacterial production of the enzyme **urease**, which splits gastric urea into ammonia and CO_2. **Ammonia production** increases the local pH and allows the bacteria to survive in the acidic stomach environment. Biopsy specimens are evaluated in the presence of urea and a pH indicator; evidence of **alkalinization** (due to active ammonia formation) confirms active *H pylori* infection. **Phenol red** is a common reagent that changes from yellow to pink in the presence of an alkaline pH.

(Choice A) Gastric adenocarcinoma (ie, clonal proliferation of glandular cells) can present as a gastric ulcer; therefore, gastric ulcers should be biopsied to rule out malignancy. However, malignant ulcers do not cause a color change on urease testing.

(Choice B) Nonsteroidal anti-inflammatory drugs (NSAIDS) (eg, aspirin, ibuprofen) are another common cause of peptic ulcers due to their inhibition of the enzyme cyclooxygenase, which is responsible for the synthesis of gastroprotective prostaglandins. However, urease would not be present in an NSAID-induced ulcer.

(Choice D) Zollinger-Ellison syndrome is due to gastrin hypersecretion, leading to overproduction of gastric acid and peptic ulcer formation. However, the ulcers would not produce a color change on urease testing.

(Choice E) Autoimmune gastritis is due to T-cell mediated destruction of parietal cells. Patients are typically asymptomatic, but prolonged

ammonia and CO_2. **Ammonia production** increases the local pH and allows the bacteria to survive in the acidic stomach environment. Biopsy specimens are evaluated in the presence of urea and a pH indicator; evidence of **alkalinization** (due to active ammonia formation) confirms active *H pylori* infection. **Phenol red** is a common reagent that changes from yellow to pink in the presence of an alkaline pH.

(Choice A) Gastric adenocarcinoma (ie, clonal proliferation of glandular cells) can present as a gastric ulcer; therefore, gastric ulcers should be biopsied to rule out malignancy. However, malignant ulcers do not cause a color change on urease testing.

(Choice B) Nonsteroidal anti-inflammatory drugs (NSAIDS) (eg, aspirin, ibuprofen) are another common cause of peptic ulcers due to their inhibition of the enzyme cyclooxygenase, which is responsible for the synthesis of gastroprotective prostaglandins. However, urease would not be present in an NSAID-induced ulcer.

(Choice D) Zollinger-Ellison syndrome is due to gastrin hypersecretion, leading to overproduction of gastric acid and peptic ulcer formation. However, the ulcers would not produce a color change on urease testing.

(Choice F) Autoimmune gastritis is due to T-cell mediated destruction of parietal cells. Patients are typically asymptomatic, but prolonged disease leads to pernicious anemia (B12 deficiency due to intrinsic factor destruction) characterized by megaloblastic anemia and neurologic dysfunction. Gastric pH is increased due to loss of parietal cells, but ulcers do not occur in this condition.

Educational objective:
Helicobacter pylori produces the enzyme urease, which splits urea into CO_2 and ammonia and neutralizes the local acidic gastric pH. Active infection can be confirmed through rapid urease testing, in which gastric mucosa is evaluated in the presence of urea and a pH indicator. Evidence of alkalization (due to ammonia formation) is confirmatory.

References

- Diagnosis of Helicobacter pylori using the rapid urease test.

Pathology	Gastrointestinal & Nutrition	Peptic ulcer disease
Subject	System	Topic

Copyright © UWorld. All rights reserved.

A 10-year-old girl is brought to the office due to abdominal discomfort and bloating for several months. She also has loose stools and excessive flatulence a few times each week. The patient eats a well-balanced diet and takes no medications or vitamins. She traveled to Africa a year ago during the summer with her family. Her last well-child visit was prior to the trip, during which physical examination findings were normal. Review of her growth chart shows a 1.8-kg (4-lb) weight loss since her last well visit and minimal height growth; her current weight and height are at the 5th percentile. Examination reveals a mildly distended abdomen without hepatosplenomegaly or tenderness. Serologic tests show autoantibodies that react with tissue transglutaminase. Which of the following tests can best establish a definite diagnosis in this patient?

A. Duodenal biopsy

B. Hydrogen breath test

C. Rectal suction biopsy

D. Stool ova and parasite test

E. Terminal ileum biopsy

Submit

A 10-year-old girl is brought to the office due to abdominal discomfort and bloating for several months. She also has loose stools and excessive flatulence a few times each week. The patient eats a well-balanced diet and takes no medications or vitamins. She traveled to Africa a year ago during the summer with her family. Her last well-child visit was prior to the trip, during which physical examination findings were normal. Review of her growth chart shows a 1.8-kg (4-lb) weight loss since her last well visit and minimal height growth; her current weight and height are at the 5th percentile. Examination reveals a mildly distended abdomen without hepatosplenomegaly or tenderness. Serologic tests show autoantibodies that react with tissue transglutaminase. Which of the following tests can best establish a definite diagnosis in this patient?

- ✓ A. Duodenal biopsy (61%)
- B. Hydrogen breath test (2%)
- C. Rectal suction biopsy (1%)
- D. Stool ova and parasite test (12%)
- E. Terminal ileum biopsy (21%)

Omitted
Correct answer
A

61%
Answered correctly

01 sec
Time Spent

03/16/2020
Last Updated

Explanation

Celiac disease	

Celiac disease	
Symptoms	• Gastrointestinal: ○ Abdominal pain ○ Nausea &/or vomiting ○ Diarrhea (rarely, constipation) ○ Flatulence & bloating • Extraintestinal: ○ Short stature & weight loss ○ Iron deficiency anemia ○ Dermatitis herpetiformis
Diagnosis	• ↑ Tissue transglutaminase IgA • ↑ Antiendomysial antibodies • Duodenal biopsy showing ↑ intraepithelial lymphocytes & flattened villi

©UWorld

Celiac disease (gluten-sensitive enteropathy or celiac sprue) is a chronic, malabsorptive disease caused by an immune-mediated reaction to ingested **gluten**, the major protein complex in wheat, barley, and rye. In healthy individuals, gluten is broken down into several proteins, including gliadin, and absorbed. In patients with celiac disease, **gliadin** triggers an inflammatory reaction that causes small intestinal villus atrophy/flattening and lymphocyte infiltration of the intraepithelial cells. The **duodenum** and **jejunum** are exposed to the highest concentration of gliadin, and biopsy of these areas is required for diagnosis. If there is a clinical suspicion of celiac disease, laboratory evaluation is performed initially and will show an elevated antibody level of **tissue transglutaminase IgA**, a small intestinal enzyme required for appropriate gluten metabolism.

Clinical manifestations of celiac disease in older children and adults include abdominal pain, nausea, vomiting, flatulence, and diarrhea. Due to malabsorption, weight loss and short stature may also be presenting symptoms. Additional extraintestinal symptoms include iron deficiency

Clinical manifestations of celiac disease in older children and adults include abdominal pain, nausea, vomiting, flatulence, and diarrhea. Due to malabsorption, weight loss and short stature may also be presenting symptoms. Additional extraintestinal symptoms include iron deficiency anemia and dermatitis herpetiformis.

(Choice B) The hydrogen breath test can be used to diagnose lactose intolerance. Malabsorbed lactose is fermented by bacteria, thereby increasing the amount of hydrogen exhaled and confirming a diagnosis. In a patient with an elevated antibody against tissue transglutaminase, the gastrointestinal symptoms are attributed to celiac disease.

(Choice C) Rectal suction biopsy is the gold standard in diagnosing Hirschsprung disease, or congenital aganglionic megacolon. Neonates classically present with failure to pass meconium in the first 48 hours of life; less severe disease may present later in life with chronic constipation and failure to thrive.

(Choice D) Stool ova and parasite (eg, *Taenia solium, Giardia lamblia*) testing should be performed in patients with prolonged gastrointestinal symptoms (eg, abdominal pain, nausea, vomiting, diarrhea) and recent travel abroad. This patient's serology result and symptom onset are not suggestive of infection.

(Choice E) Terminal ileum biopsy is performed in the evaluation of Crohn disease. Clinical manifestations include abdominal pain, bloody diarrhea, and weight loss. Diagnostic workup reveals leukocytosis, elevated inflammatory markers, and biopsy showing focal inflammation and ulceration.

Educational objective:
Celiac disease is caused by an immune-mediated reaction to gluten and can present with bloating, diarrhea, and flatulence, as well as short stature and weight loss. Screening tests show an elevated level of IgA against tissue transglutaminase. Duodenal biopsy is confirmatory, showing villus flattening and intraepithelial lymphocyte infiltration.

References

- Sampling of proximal and distal duodenal biopsies in the diagnosis and monitoring of celiac disease.
- Pathology of celiac disease: a brief review.

Settings

1
2
3
4
5
6
7
8
9
10
11
12
13
14
15
16
17
18
19
20
21
22
23
24
25
26
27
28
29
30

Item 8 of 40
Question Id: 326

Mark | Previous | Next | Full Screen | Tutorial | Lab Values | Notes | Calculator | Reverse Color | Text Zoom | Settings

Clinical manifestations of celiac disease in older children and adults include abdominal pain, nausea, vomiting, flatulence, and diarrhea. Due to

Exhibit Display

Zoom In | Zoom Out | Reset | Add To New Card | Existing Card

Block Time Remaining: 00:00:17
TUTOR

3 | Feedback | Suspend | End Block

1 2 3 4 5 6 7 8 9 10 11 12 13 14 15 16 17 18 19 20 21 22 23 24 25 26 27 28 29 30

Clinical manifestations of celiac disease in older children and adults include abdominal pain, nausea, vomiting, flatulence, and diarrhea. Due to

Exhibit Display

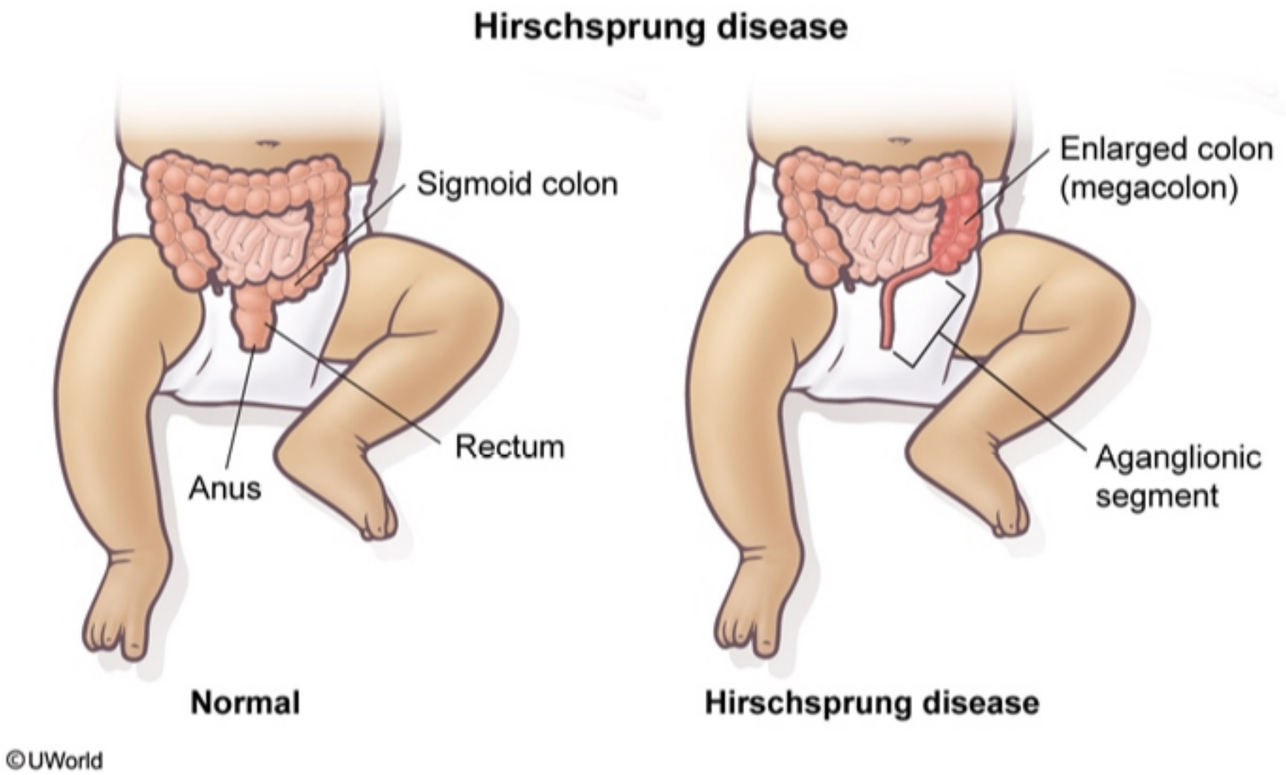

Zoom In | Zoom Out | Reset | Add To New Card | Existing Card

Clinical manifestations of celiac disease in older children and adults include abdominal pain, nausea, vomiting, flatulence, and diarrhea. Due to

Exhibit Display

Crohn disease

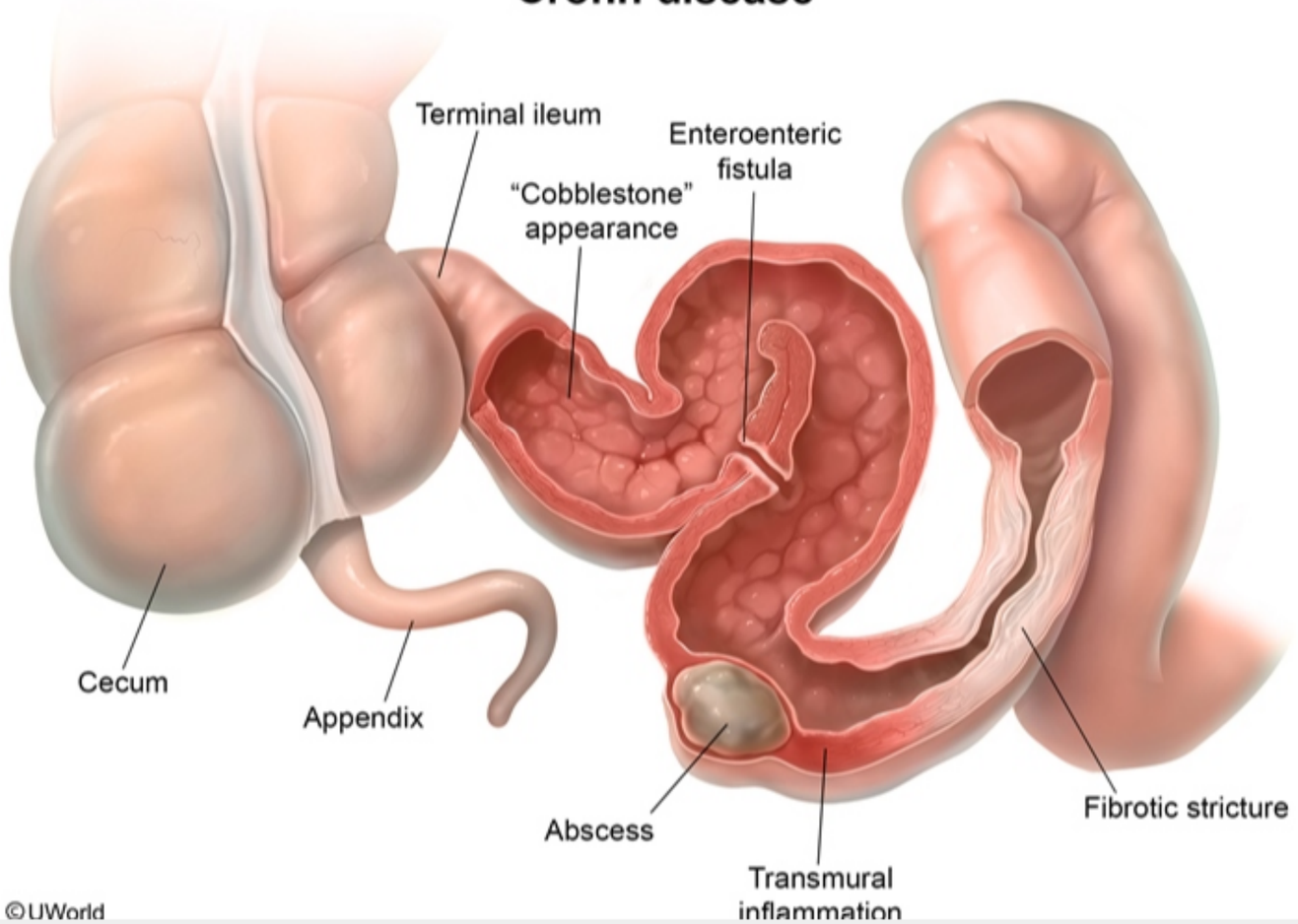

©UWorld

Zoom In | Zoom Out | Reset | Add To New Card | Existing Card

A 22-year-old Caucasian male presents to the ER with abdominal pain that started around his bellybutton, then moved to the right lower abdominal quadrant. After initial evaluation, laparotomy is performed, which reveals the following findings (see the slide below).

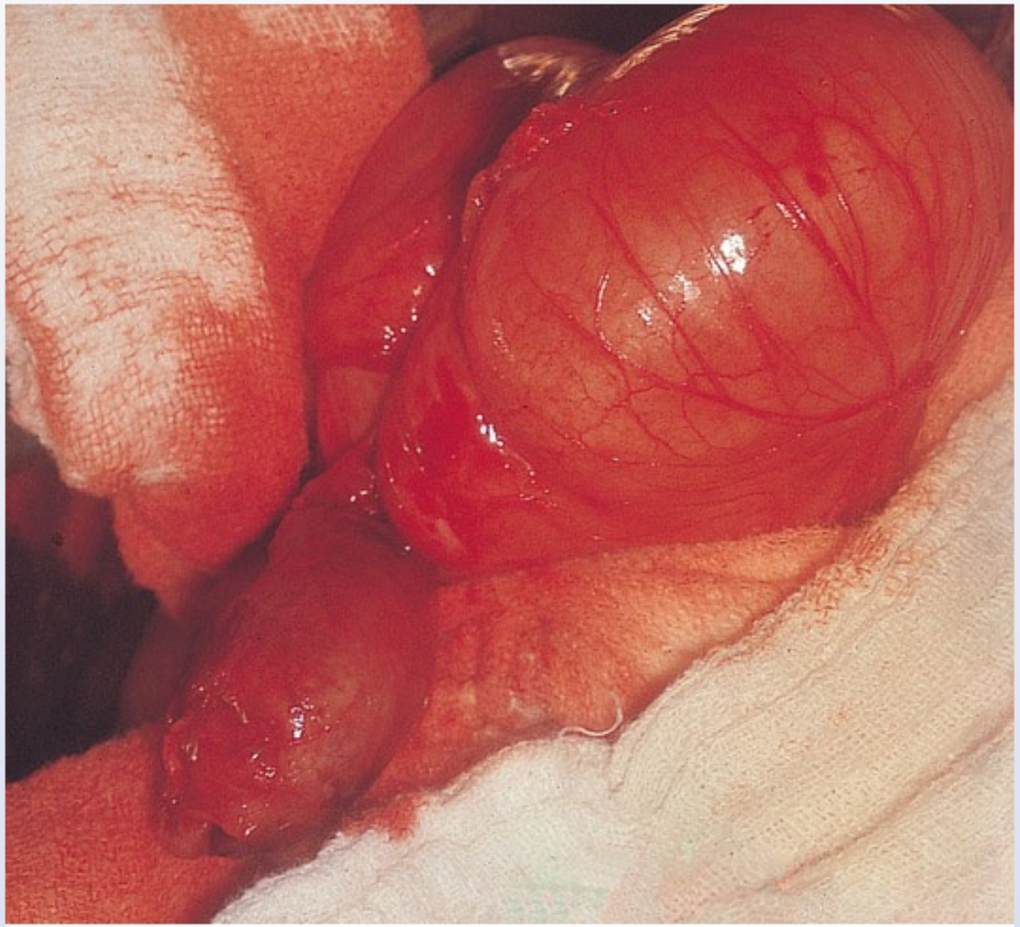

Displayed with permission from Springer Healthcare Ltd. © Copyright 1997 by Current Medicine

Which of the following most likely initiated this patient's condition?

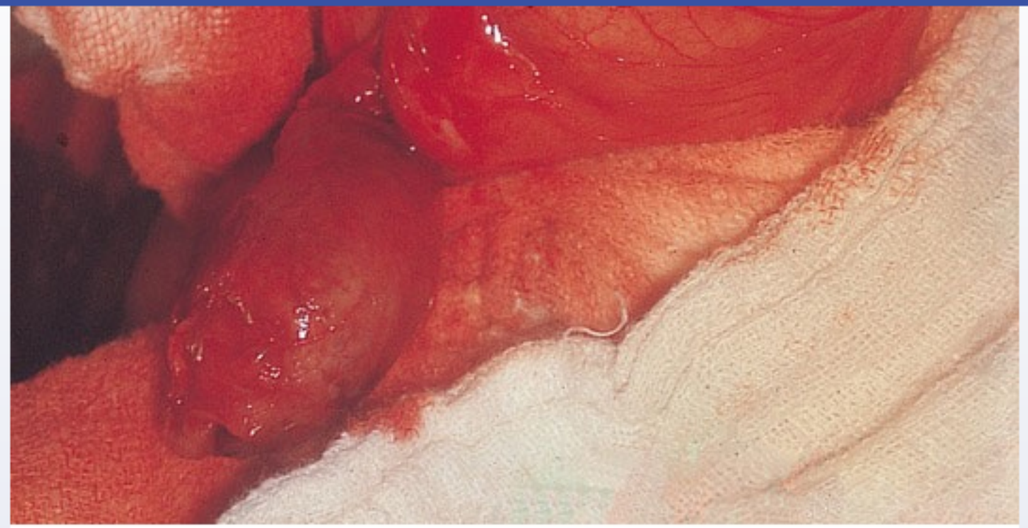

Displayed with permission from Springer Healthcare Ltd. © Copyright 1997 by Current Medicine

Which of the following most likely initiated this patient's condition?

- A. Bacterial infection
- B. Peptic ulceration
- C. Lumen obstruction
- D. Venous thrombosis
- E. Arterial spasm

Submit

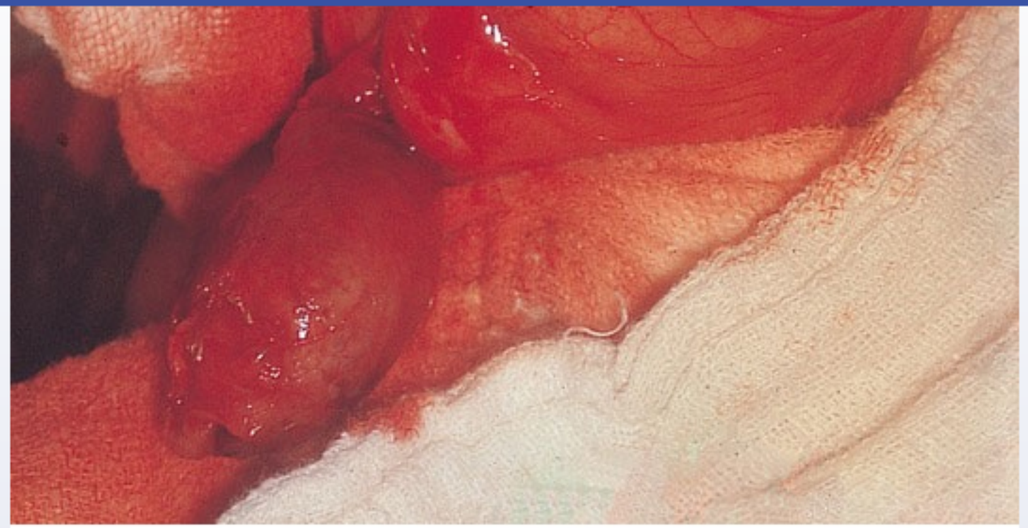

Displayed with permission from Springer Healthcare Ltd. © Copyright 1997 by Current Medicine

Which of the following most likely initiated this patient's condition?

- A. Bacterial infection (19%)
- B. Peptic ulceration (1%)
- ✓ C. Lumen obstruction (74%)
- D. Venous thrombosis (2%)
- E. Arterial spasm (1%)

Omitted
Correct answer

74%
Answered correctly

05 secs
Time Spent

02/03/2020
Last Updated

Explanation

An inflamed, hyperemic, and edematous appendix is shown above. This macroscopic appearance, along with periumbilical pain that migrates to the right lower quadrant, is classic for acute appendicitis. This condition occurs in all age groups, with peak incidence in children 6-10 years old. The abdominal pain tends to appear in the periumbilical area (visceral pain) and shifts to the right lower quadrant a few hours later.

Acute appendicitis is caused by an obstruction of the appendicular lumen. The most common obstructing agents are fecaliths. Obstruction by hyperplastic lymphoid follicles, foreign bodies, nematodes, and carcinoids may also cause acute appendicitis. Retained mucus causes the appendicular wall to distend, which impairs venous outflow. The resulting hypoxia causes ischemia and associated bacterial invasion. Inflammation and edema of the appendicular wall occur, causing further distention. Necrosis of the wall with rupture may follow. In this case, inflammatory fluid and bacterial contents spill into the peritoneal cavity, causing peritonitis.

(Choice A) Bacterial infection plays an important role in the pathogenesis of acute appendicitis. It is not, however, the initiating event.

(Choice B) Peptic ulceration is implicated in the development of lower intestinal bleeding due to Meckel diverticulum, not acute appendicitis.

(Choices D and E) Both venous thrombosis and arterial spasm can cause mesenteric ischemia; however, neither of these factors lead to acute appendicitis.

Educational Objective:
Obstruction of the lumen of the appendix is the first event in pathogenesis of acute appendicitis. Fecaliths, hyperplastic lymphoid follicles, foreign bodies, or tumors may cause the obstruction. Right lower quadrant abdominal pain, nausea, vomiting, diarrhea, and fever are the typical manifestations of acute appendicitis.

Pathology	Gastrointestinal & Nutrition	Appendicitis
Subject	System	Topic

Copyright © UWorld. All rights reserved.

A 60-year-old man is found to have a 5-cm exophytic mass in the ascending colon during a screening colonoscopy. Biopsy of the mass shows adenocarcinoma. The patient has no personal or family history of malignancy or colonic polyps. His medical problems include hypertension, and he does not use tobacco or alcohol. CT scan of the chest and abdomen reveals no metastatic lesions in the lungs or liver. A right colectomy is performed. The presence of which of the following indicates a poor prognosis in this patient?

A. Abundant, well-formed glands in the tumor

B. Cytokeratin expression by the malignant cells

C. Malignant cells invading the lamina propria

D. Prominent lymphocyte infiltration of the tumor

E. Tumor cell deposits in the regional lymph nodes

Submit

A 60-year-old man is found to have a 5-cm exophytic mass in the ascending colon during a screening colonoscopy. Biopsy of the mass shows adenocarcinoma. The patient has no personal or family history of malignancy or colonic polyps. His medical problems include hypertension, and he does not use tobacco or alcohol. CT scan of the chest and abdomen reveals no metastatic lesions in the lungs or liver. A right colectomy is performed. The presence of which of the following indicates a poor prognosis in this patient?

- A. Abundant, well-formed glands in the tumor (0%)
- B. Cytokeratin expression by the malignant cells (1%)
- C. Malignant cells invading the lamina propria (22%)
- D. Prominent lymphocyte infiltration of the tumor (0%)
- ✓ E. Tumor cell deposits in the regional lymph nodes (74%)

Omitted
Correct answer
E

74%
Answered correctly

01 sec
Time Spent

03/08/2020
Last Updated

Explanation

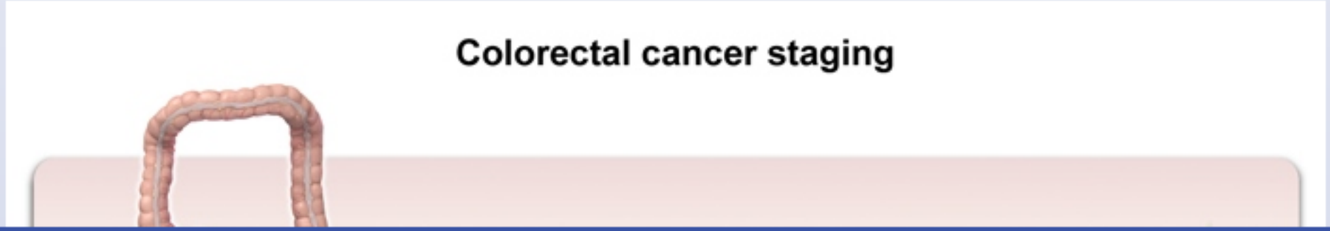

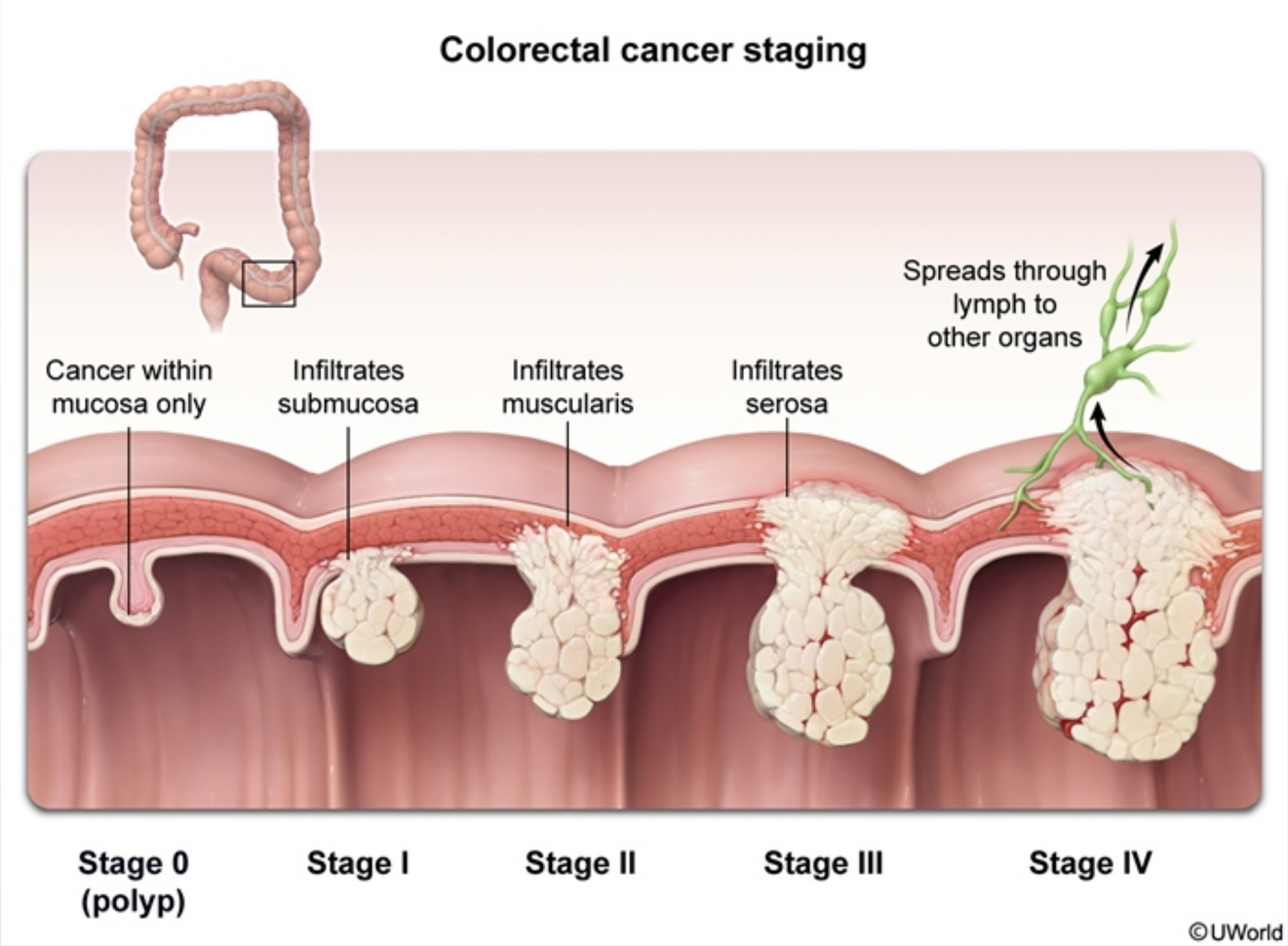

The **prognosis of colorectal cancer** is most tightly correlated with tumor stage at diagnosis. Stage reflects the **degree of tumor invasion and spread** from the initial site of formation. Colorectal tumors confined to the basement membrane or lamina propria are considered to be carcinoma in situ and have an excellent 5-year survival rate (>90%). Invasion of the tumor into the muscularis propria, the location of the colonic lymphatic

©UWorld

The **prognosis of colorectal cancer** is most tightly correlated with tumor stage at diagnosis. Stage reflects the **degree of tumor invasion and spread** from the initial site of formation. Colorectal tumors confined to the basement membrane or lamina propria are considered to be carcinoma in situ and have an excellent 5-year survival rate (>90%). Invasion of the tumor into the muscularis propria, the location of the colonic lymphatic channels, is associated with a slightly worse prognosis (5-year survival rate of 70%-80%) due to elevated rates of tumor spread through lymphatics or to adjacent organs.

The prognosis of colon cancer deteriorates when tumor cells are identified in regional lymph nodes (5-year survival rate of 50%-80%). **Lymph node spread** is thought to be one of the strongest predictors of metastatic potential and, therefore, indicates an **increased risk** for incurable, distant disease. Metastatic spread to distant organs (eg, lungs, liver) is associated with the worst 5-year survival rates (<15%).

(Choice A) Tumor grade, the degree of cellular differentiation of tumor cells, also affects prognosis. Well-differentiated (low-grade) colonic tumors have glandular structure and are associated with a better prognosis than poorly differentiated (high-grade) colonic tumors, which appear as sheets or cords of cells with pleomorphism, high mitotic rates, and other signs of significant cellular aberration. Grade is a less important prognostic indicator than stage.

(Choice B) Cytokeratin 20 is a marker of intestinal cell differentiation. Testing for the presence of this structural protein helps confirm that adenocarcinomas are of intestinal origin; it is not a prognostic indicator.

(Choice C) The invasion of colorectal cancer into the lamina propria is considered to be carcinoma in situ because lymphatic channels do not arise until the subsequent layer (muscularis propria). Patients with colorectal tumors confined to the basement membrane or lamina propria have an excellent prognosis.

(Choice D) Cytotoxic T-cell (lymphocytic) invasion of tumor cells is a favorable prognostic indicator as it signifies immune recognition. It is associated with a lower risk of metastases and improved survival.

Educational objective:
Tumor stage (degree of invasion/spread) is the most important prognostic determinant for colorectal cancer. Tumors confined to the basement membrane and lamina propria are early stage and have the best prognosis. Outcomes generally deteriorate as the stage advances: spread of tumor into the muscularis propria → regional lymph nodes → distant sites.

1 2 3 4 5 6 7 8 9 10 11 12 13 14 15 16 17 18 19 20 21 22 23 24 25 26 27 28 29 30

lymphatics or to adjacent organs.

The prognosis of colon cancer deteriorates when tumor cells are identified in regional lymph nodes (5-year survival rate of 50%-80%). **Lymph node spread** is thought to be one of the strongest predictors of metastatic potential and, therefore, indicates an **increased risk** for incurable, distant disease. Metastatic spread to distant organs (eg, lungs, liver) is associated with the worst 5-year survival rates (<15%).

(Choice A) Tumor grade, the degree of cellular differentiation of tumor cells, also affects prognosis. Well-differentiated (low-grade) colonic tumors have glandular structure and are associated with a better prognosis than poorly differentiated (high-grade) colonic tumors, which appear as sheets or cords of cells with pleomorphism, high mitotic rates, and other signs of significant cellular aberration. Grade is a less important prognostic indicator than stage.

(Choice B) Cytokeratin 20 is a marker of intestinal cell differentiation. Testing for the presence of this structural protein helps confirm that adenocarcinomas are of intestinal origin; it is not a prognostic indicator.

(Choice C) The invasion of colorectal cancer into the lamina propria is considered to be carcinoma in situ because lymphatic channels do not arise until the subsequent layer (muscularis propria). Patients with colorectal tumors confined to the basement membrane or lamina propria have an excellent prognosis.

(Choice D) Cytotoxic T-cell (lymphocytic) invasion of tumor cells is a favorable prognostic indicator as it signifies immune recognition. It is associated with a lower risk of metastases and improved survival.

Educational objective:
Tumor stage (degree of invasion/spread) is the most important prognostic determinant for colorectal cancer. Tumors confined to the basement membrane and lamina propria are early stage and have the best prognosis. Outcomes generally deteriorate as the stage advances: spread of tumor into the muscularis propria → regional lymph nodes → distant sites.

Pathology	Gastrointestinal & Nutrition	Colorectal cancer
Subject	System	Topic

Copyright © UWorld. All rights reserved.

A 45-year-old woman comes to the office due to several months of episodic right upper quadrant abdominal pain associated with nausea. The pain is often brought on by fatty meals and subsides in 1-2 hours. The patient has no fever, vomiting, diarrhea, melena, or bright red blood per rectum. Her BMI is 31.2 kg/m^2. Physical examination is unremarkable. A cholecystokinin stimulation test is performed and shows slow and incomplete gallbladder emptying. This patient is most likely to have which of the following pathologic findings?

A. Biliary sludge

B. Black pigment stones

C. Brown pigment stones

D. Cystine stones

E. Uric acid stones

Submit

A 45-year-old woman comes to the office due to several months of episodic right upper quadrant abdominal pain associated with nausea. The pain is often brought on by fatty meals and subsides in 1-2 hours. The patient has no fever, vomiting, diarrhea, melena, or bright red blood per rectum. Her BMI is 31.2 kg/m^2. Physical examination is unremarkable. A cholecystokinin stimulation test is performed and shows slow and incomplete gallbladder emptying. This patient is most likely to have which of the following pathologic findings?

- ✓ A. Biliary sludge (50%)
- B. Black pigment stones (16%)
- C. Brown pigment stones (30%)
- D. Cystine stones (1%)
- E. Uric acid stones (0%)

Omitted
Correct answer
A

50%
Answered correctly

02 secs
Time Spent

03/03/2020
Last Updated

Explanation

Biliary sludge

Mucin
Cholesterol crystals
Calcium bilirubinate
Other calcium salts
} Future stone

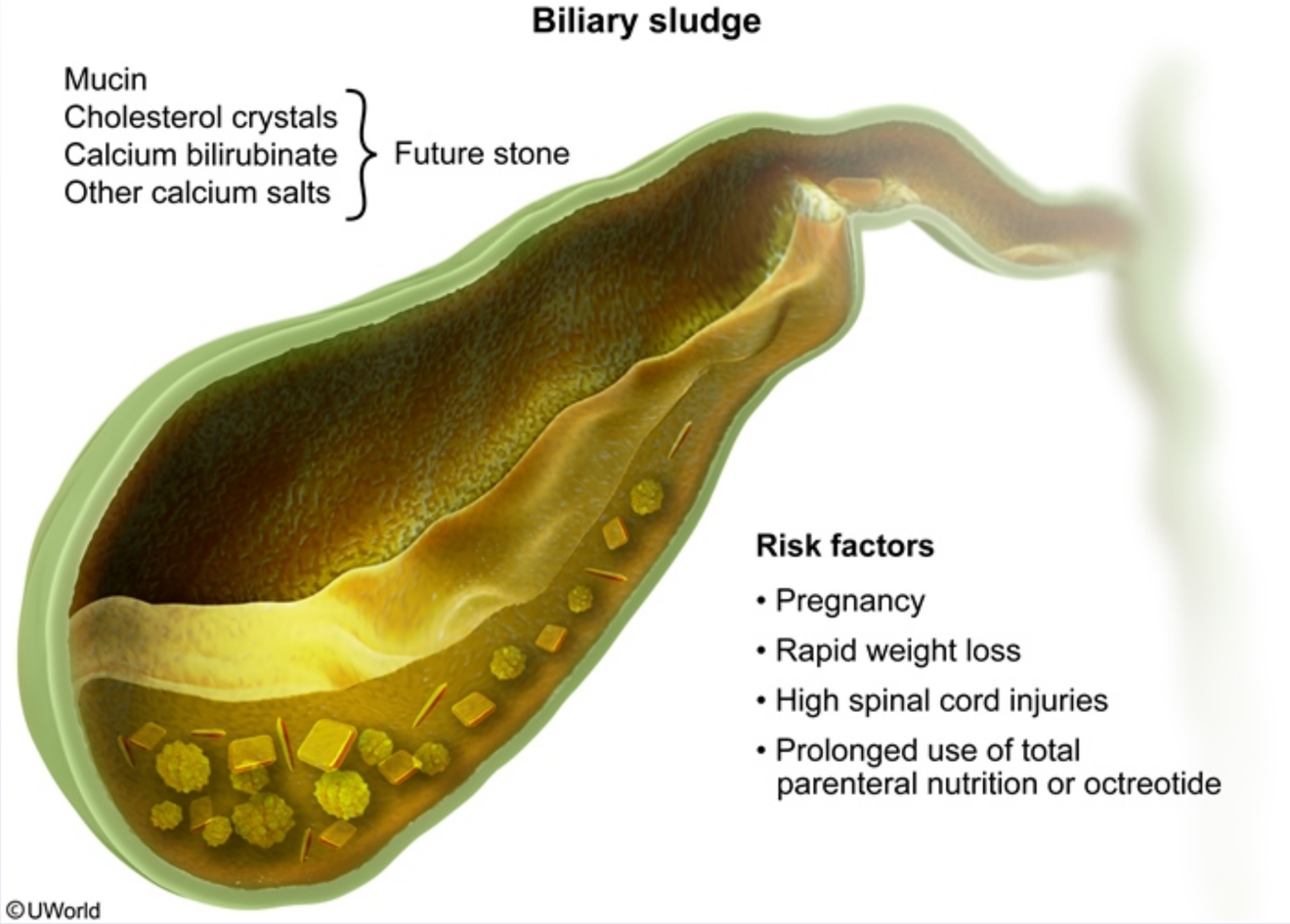

This patient's slow/incomplete gallbladder emptying in response to cholecystokinin stimulation is consistent with **gallbladder hypomotility**. The gallbladder functions to actively absorb water from bile; conditions that cause gallbladder hypomotility result in excessive dehydration of bile. This promotes the precipitation and accumulation of particulate material (eg, cholesterol monohydrate crystals, calcium bilirubinate, mucus) in bile, forming viscous **biliary sludge**. Sludge formation may be asymptomatic or cause biliary colic (right upper quadrant abdominal pain associated

This patient's slow/incomplete gallbladder emptying in response to cholecystokinin stimulation is consistent with **gallbladder hypomotility**. The gallbladder functions to actively absorb water from bile; conditions that cause gallbladder hypomotility result in excessive dehydration of bile. This promotes the precipitation and accumulation of particulate material (eg, cholesterol monohydrate crystals, calcium bilirubinate, mucus) in bile, forming viscous **biliary sludge**. Sludge formation may be asymptomatic or cause biliary colic (right upper quadrant abdominal pain associated with nausea) and is a known precursor to stone formation (particularly cholesterol stones). Complications such as acute cholecystitis and cholangitis can also occur in patients with biliary sludge.

(Choices B and C) Pigment gallstones can be brown or black and arise from conditions that increase the amount of unconjugated bilirubin in bile. Brown pigment stones are associated with biliary tract infections (microbes producing β-glucuronidases), whereas black stones occur with chronic hemolytic anemias (eg, sickle cell disease) and increased enterohepatic cycling of bilirubin (eg, Crohn disease, which also decreases enterohepatic cycling of bile acids). This patient has no risk factors for pigment stones, and her gallbladder dysmotility makes biliary sludge a more likely diagnosis.

(Choice D) Cystinuria is an autosomal recessive condition characterized by a defect in an amino acid transporter gene, resulting in elevated urinary cystine concentrations. Patients typically present with cystine kidney stones during childhood or adolescence.

(Choice E) Individuals with high serum uric acid levels are at increased risk of developing uric acid kidney stones. Hyperuricemia can be caused by uric acid underexcretion (eg, thiazide diuretics) or overproduction (eg, tumor lysis syndrome).

Educational objective:
The gallbladder functions to actively absorb water from bile. Gallbladder hypomotility causes the bile to become concentrated, promoting precipitation and accumulation of particulate material. This forms a viscous biliary sludge that can cause transient bile duct obstruction (biliary colic) and promote cholesterol gallstone formation.

References

- Biliary sludge: the sluggish gallbladder.
- Gallbladder sludge: what is its clinical significance?
- Lithogenesis and bile metabolism.

The following vignette applies to the next **2** items. The items in the set must be answered in sequential order. Once you click **Proceed to Next Item**, you will not be able to add or change an answer.

A 42-year-old man with HIV comes to the emergency department with 3 days of abdominal pain, decreased appetite, and diarrhea. Temperature is 38 C (100.4 F), blood pressure is 98/60 mm Hg, and pulse is 110/min. Abdominal examination shows tenderness over the left lower quadrant without guarding or rebound tenderness. CD4 count is 38/mm^3. Colonoscopy shows erythematous, friable mucosa with superficial ulcerations in the sigmoid and descending colon. Biopsy from the ulcers reveals inflammatory infiltrate, mucosal necrosis, and enlarged endothelial cells with large, ovoid nuclei containing prominent basophilic deposits.

Item 1 of 2

Which of the following is the most likely cause of this patient's gastrointestinal symptoms?

- A. Disseminated mycobacterial infection
- B. Infection by a modified acid-fast protozoan
- C. Mucosal invasion by a commensal yeast
- D. Reactivation of a herpesvirus
- E. Toxin from an anaerobic bacteria

Submit

The following vignette applies to the next **2** items. The items in the set must be answered in sequential order. Once you click **Proceed to Next Item**, you will not be able to add or change an answer.

A 42-year-old man with HIV comes to the emergency department with 3 days of abdominal pain, decreased appetite, and diarrhea. Temperature is 38 C (100.4 F), blood pressure is 98/60 mm Hg, and pulse is 110/min. Abdominal examination shows tenderness over the left lower quadrant without guarding or rebound tenderness. CD4 count is 38/mm^3. Colonoscopy shows erythematous, friable mucosa with superficial ulcerations in the sigmoid and descending colon. Biopsy from the ulcers reveals inflammatory infiltrate, mucosal necrosis, and enlarged endothelial cells with large, ovoid nuclei containing prominent basophilic deposits.

Item 1 of 2

Which of the following is the most likely cause of this patient's gastrointestinal symptoms?

- A. Disseminated mycobacterial infection (8%)
- B. Infection by a modified acid-fast protozoan (34%)
- C. Mucosal invasion by a commensal yeast (11%)
- ✓ D. Reactivation of a herpesvirus (33%)
- E. Toxin from an anaerobic bacteria (12%)

Omitted
Correct answer
D

33%
Answered correctly

01 sec
Time Spent

02/27/2020
Last Updated

Common opportunistic causes of diarrhea in HIV patients	
Pathogen	**Histopathologic findings**
Cytomegalovirus	• Multiple ulcers & mucosal erosions • Large cells with basophilic intranuclear & intracytoplasmic inclusions
Cryptosporidium	• Nonulcerative inflammation • Basophilic clusters seen on the surface of intestinal mucosal cells
Microsporidium	• Distortion of villus architecture without inflammation • Small spores with a diagonal or equatorial belt-like structure
Mycobacterium avium complex	• Necrotizing & non-necrotizing granulomas • Acid-fast staining bacilli are present

Cytomegalovirus (CMV) is the most common viral opportunistic infection of the gastrointestinal tract in patients with advanced AIDS. Initial infection with CMV is usually asymptomatic or similar to Epstein-Barr virus-induced mononucleosis. As with all members of the **herpesvirus family**, latent infection is established after resolution of the initial infection. Reactivation can occur at any time but is most common in the setting of immunosuppression. In patients with HIV, **CMV colitis** is the second most common reactivation syndrome after CMV retinitis. Patients with CMV colitis have fever, anorexia, weight loss, and abdominal pain. The pain may be vague initially but becomes more localized as the disease progresses. Colonoscopy shows mucosal erythema, erosions, and ulcerations. Histologic examination of biopsy specimens will reveal acute and chronic inflammatory changes, vasculitis, and giant cells with large, ovoid nuclei containing **centralized intranuclear basophilic inclusions** (owl's eye appearance).

avium complex	• Acid-fast staining bacilli are present

Cytomegalovirus (CMV) is the most common viral opportunistic infection of the gastrointestinal tract in patients with advanced AIDS. Initial infection with CMV is usually asymptomatic or similar to Epstein-Barr virus-induced mononucleosis. As with all members of the **herpesvirus family**, latent infection is established after resolution of the initial infection. Reactivation can occur at any time but is most common in the setting of immunosuppression. In patients with HIV, **CMV colitis** is the second most common reactivation syndrome after CMV retinitis. Patients with CMV colitis have fever, anorexia, weight loss, and abdominal pain. The pain may be vague initially but becomes more localized as the disease progresses. Colonoscopy shows mucosal erythema, erosions, and ulcerations. Histologic examination of biopsy specimens will reveal acute and chronic inflammatory changes, vasculitis, and giant cells with large, ovoid nuclei containing **centralized intranuclear basophilic inclusions** (owl's eye appearance).

(Choice A) Patients with advanced AIDS are at risk for disseminated *Mycobacterium avium* complex, which is often associated with diarrhea, abdominal pain, and weight loss. However, necrotizing and non-necrotizing granulomas and acid-fast staining organisms are typically seen on biopsy.

(Choice B) *Cryptosporidium* is a protozoan parasite that causes watery diarrhea in both immunocompromised and immunocompetent patients. However, it primarily affects the small intestine, not the colon. Oocytes can be identified using microscopy with modified acid-fast stain; biopsy will show basophilic parasites attached to the mucosal brush border.

(Choice C) *Candida albicans* is a normal part of human flora that often causes oropharyngeal and esophageal infections in patients with advanced AIDS. However, *Candida* and other yeasts (eg, *Histoplasma capsulatum*) are a rare cause of colitis.

(Choice E) *Clostridium difficile* is an exotoxin-producing, anaerobic bacterium that can cause severe colitis, most commonly after antibiotic use. Patients usually have fever, abdominal pain, leukocytosis, and diarrhea. Endoscopy is not usually needed but often reveals mucosal pseudomembranes.

Educational objective:
Cytomegalovirus (CMV) is a common cause of colitis in patients with advanced AIDS. It is the second most common CMV reactivation disease in this population (CMV retinitis is the most common). Patients with CMV colitis often have abdominal pain, fever, diarrhea, and weight loss. Colonoscopy usually shows erythema, erosions, and ulcerations; colonic biopsy typically reveals large cells with prominent basophilic intranuclear inclusions.

Settings

1 2 3 4 5 6 7 8 9 10 11 12 13 14 15 16 17 18 19 20 21 22 23 24 25 26 27 28 29 30

Item 12 of 40
Question Id: 7228

Mark | Previous | Next | Full Screen | Tutorial | Lab Values | Notes | Calculator | Reverse Color | Text Zoom | Settings

avium complex

- Acid-fast staining bacilli are present

Exhibit Display

CMV in a lymph node CMV pneumonitis

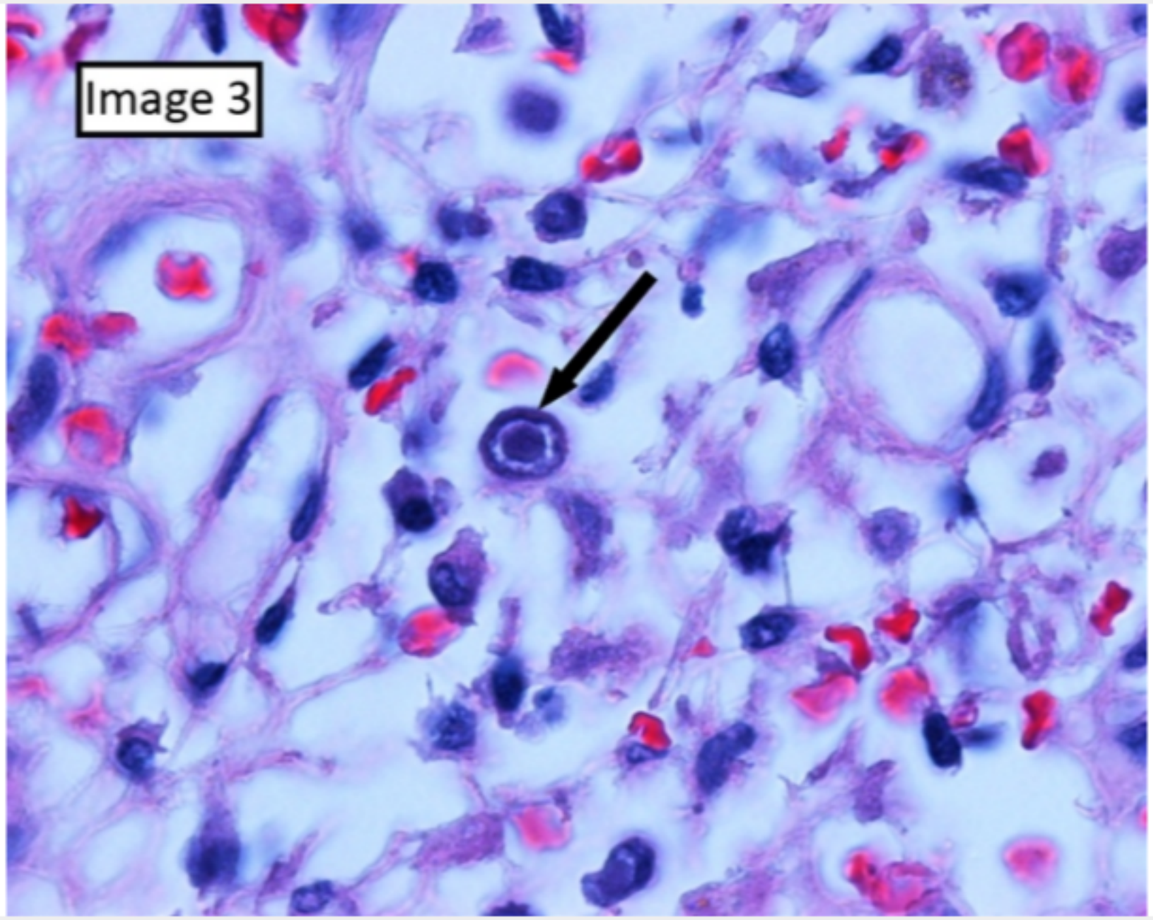

Zoom In | Zoom Out | Reset | Add To New Card | Existing Card

inclusions

Block Time Remaining: 00:00:26
TUTOR

6 | Feedback | Suspend | End Block

Settings

1 2 3 4 5 6 7 8 9 10 11 12 13 14 15 16 17 18 19 20 21 22 23 24 25 26 27 28 29 30

Item 12 of 40
Question Id: 7228

Mark | Previous | Next | Full Screen | Tutorial | Lab Values | Notes | Calculator | Reverse Color | Text Zoom | Settings

avium complex

- Acid-fast staining bacilli are present

Exhibit Display

CMV in a lymph node CMV pneumonitis

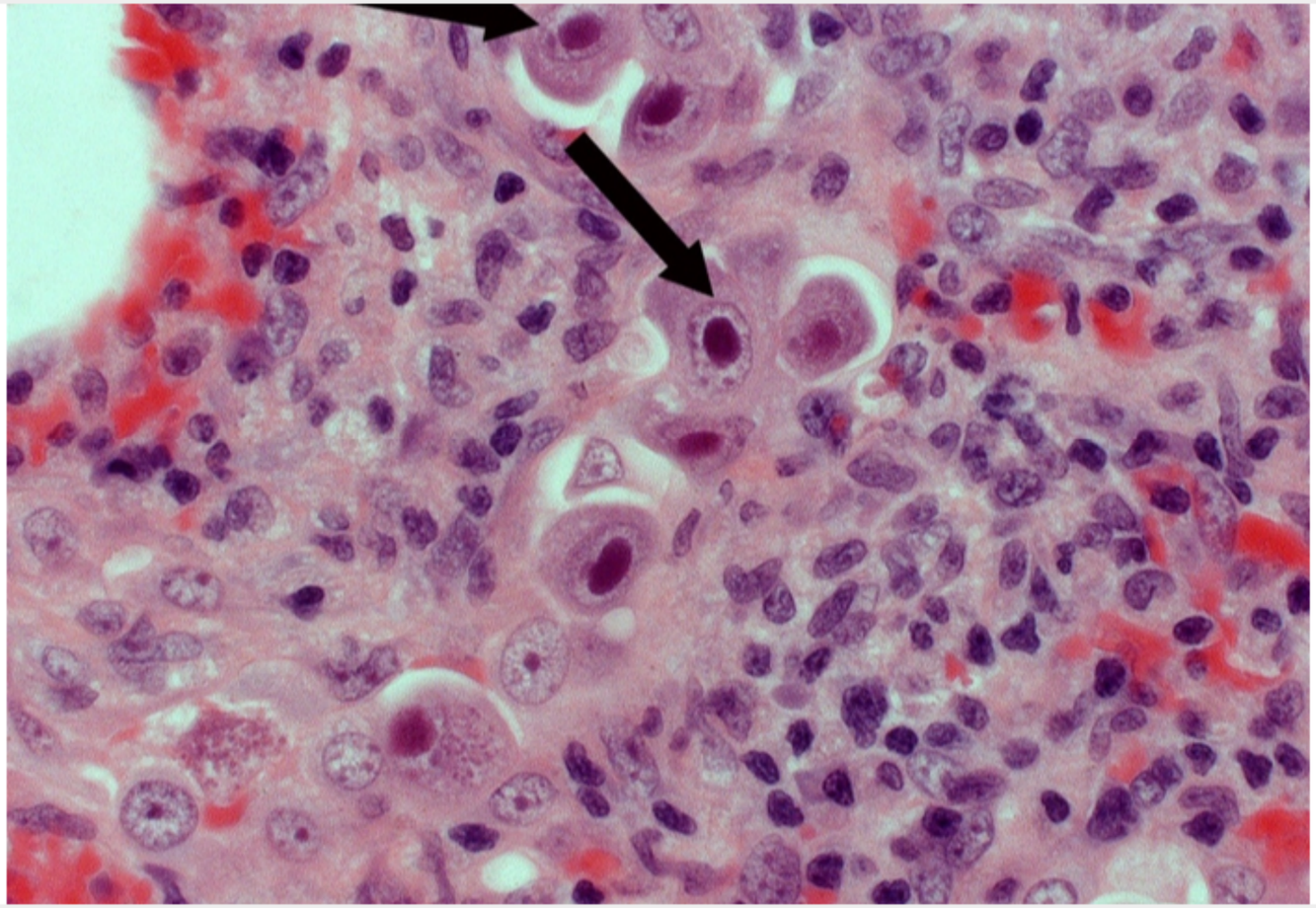

Zoom In | Zoom Out | Reset | Add To New Card | Existing Card

inclusions

Block Time Remaining: 00:00:26
TUTOR

6 | Feedback | Suspend | End Block

progresses. Colonoscopy shows mucosal erythema, erosions, and ulcerations. Histologic examination of biopsy specimens will reveal acute and chronic inflammatory changes, vasculitis, and giant cells with large, ovoid nuclei containing **centralized intranuclear basophilic inclusions** (owl's eye appearance).

(Choice A) Patients with advanced AIDS are at risk for disseminated *Mycobacterium avium* complex, which is often associated with diarrhea, abdominal pain, and weight loss. However, necrotizing and non-necrotizing granulomas and acid-fast staining organisms are typically seen on biopsy.

(Choice B) *Cryptosporidium* is a protozoan parasite that causes watery diarrhea in both immunocompromised and immunocompetent patients. However, it primarily affects the small intestine, not the colon. Oocytes can be identified using microscopy with modified acid-fast stain; biopsy will show basophilic parasites attached to the mucosal brush border.

(Choice C) *Candida albicans* is a normal part of human flora that often causes oropharyngeal and esophageal infections in patients with advanced AIDS. However, *Candida* and other yeasts (eg, *Histoplasma capsulatum*) are a rare cause of colitis.

(Choice E) *Clostridium difficile* is an exotoxin-producing, anaerobic bacterium that can cause severe colitis, most commonly after antibiotic use. Patients usually have fever, abdominal pain, leukocytosis, and diarrhea. Endoscopy is not usually needed but often reveals mucosal pseudomembranes.

Educational objective:
Cytomegalovirus (CMV) is a common cause of colitis in patients with advanced AIDS. It is the second most common CMV reactivation disease in this population (CMV retinitis is the most common). Patients with CMV colitis often have abdominal pain, fever, diarrhea, and weight loss. Colonoscopy usually shows erythema, erosions, and ulcerations; colonic biopsy typically reveals large cells with prominent basophilic intranuclear inclusions.

Pathology	Gastrointestinal & Nutrition	Cytomegalovirus
Subject	System	Topic

Copyright © UWorld. All rights reserved.

Settings

1 2 3 4 5 6 7 8 9 10 11 12 13 14 15 16 17 18 19 20 21 22 23 24 25 26 27 28 29 30

Item 12 of 40
Question Id: 7228

Mark | Previous | Next | Full Screen | Tutorial | Lab Values | Notes | Calculator | Reverse Color | Text Zoom | Settings

progresses. Colonoscopy shows mucosal erythema, erosions, and ulcerations. Histologic examination of biopsy specimens will reveal acute and

Exhibit Display

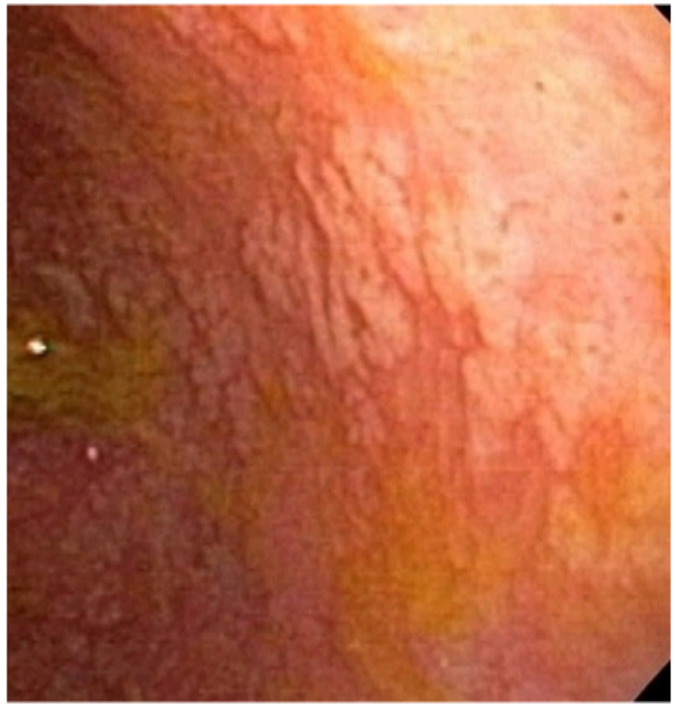

Zoom In | Zoom Out | Reset | Add To New Card | Existing Card

Block Time Remaining: 00:00:26
TUTOR

6 | Feedback | Suspend | End Block

Item 2 of 2

The patient is hospitalized, and appropriate treatment is begun. After discussing the underlying cause of his condition—immunosuppression due to HIV infection—the patient agrees to take antiretroviral therapy consistently. One of the medications in his treatment regimen leads to the production of immature, noninfectious virions containing large polyproteins. Which of the following viral processes is most likely directly inhibited by this agent?

A. Expression of glycoproteins on the virus cell surface

B. Integration of the viral DNA molecule into the host genome

C. Production of functional viral-encoded enzymes

D. Removal of viral template RNA from the RNA-DNA hybrid

E. Translation of virus-encoded regulatory proteins

Submit

Item 2 of 2

The patient is hospitalized, and appropriate treatment is begun. After discussing the underlying cause of his condition—immunosuppression due to HIV infection—the patient agrees to take antiretroviral therapy consistently. One of the medications in his treatment regimen leads to the production of immature, noninfectious virions containing large polyproteins. Which of the following viral processes is most likely directly inhibited by this agent?

A. Expression of glycoproteins on the virus cell surface (13%)

B. Integration of the viral DNA molecule into the host genome (12%)

✓ C. Production of functional viral-encoded enzymes (56%)

D. Removal of viral template RNA from the RNA-DNA hybrid (5%)

E. Translation of virus-encoded regulatory proteins (11%)

Omitted
Correct answer
C

56%
Answered correctly

02 secs
Time Spent

02/27/2020
Last Updated

Explanation

HIV antiviral drugs

HIV virion

HIV antiviral drugs

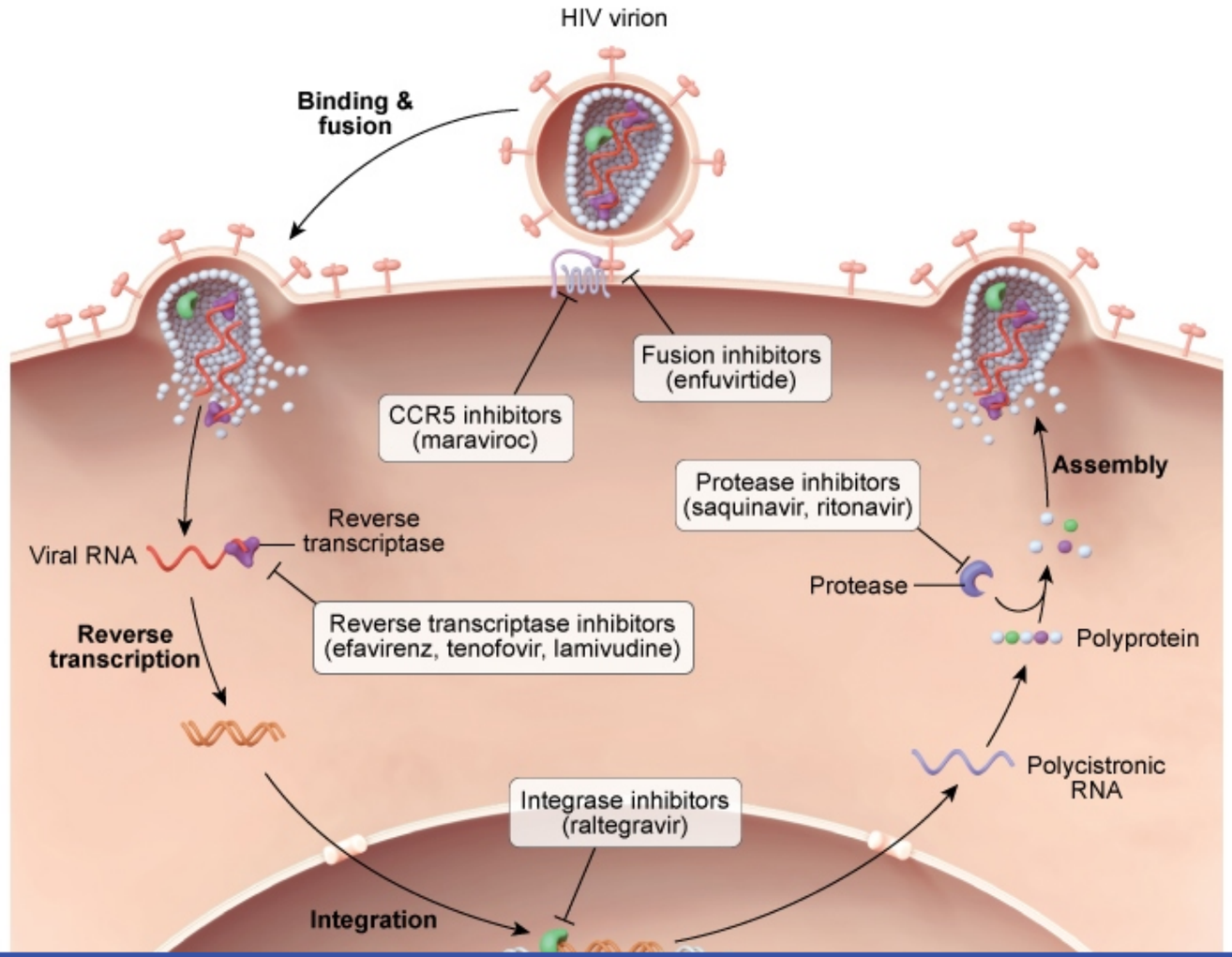

1 2 3 4 5 6 7 8 9 10 11 12 13 14 15 16 17 18 19 20 21 22 23 24 25 26 27 28 29 30

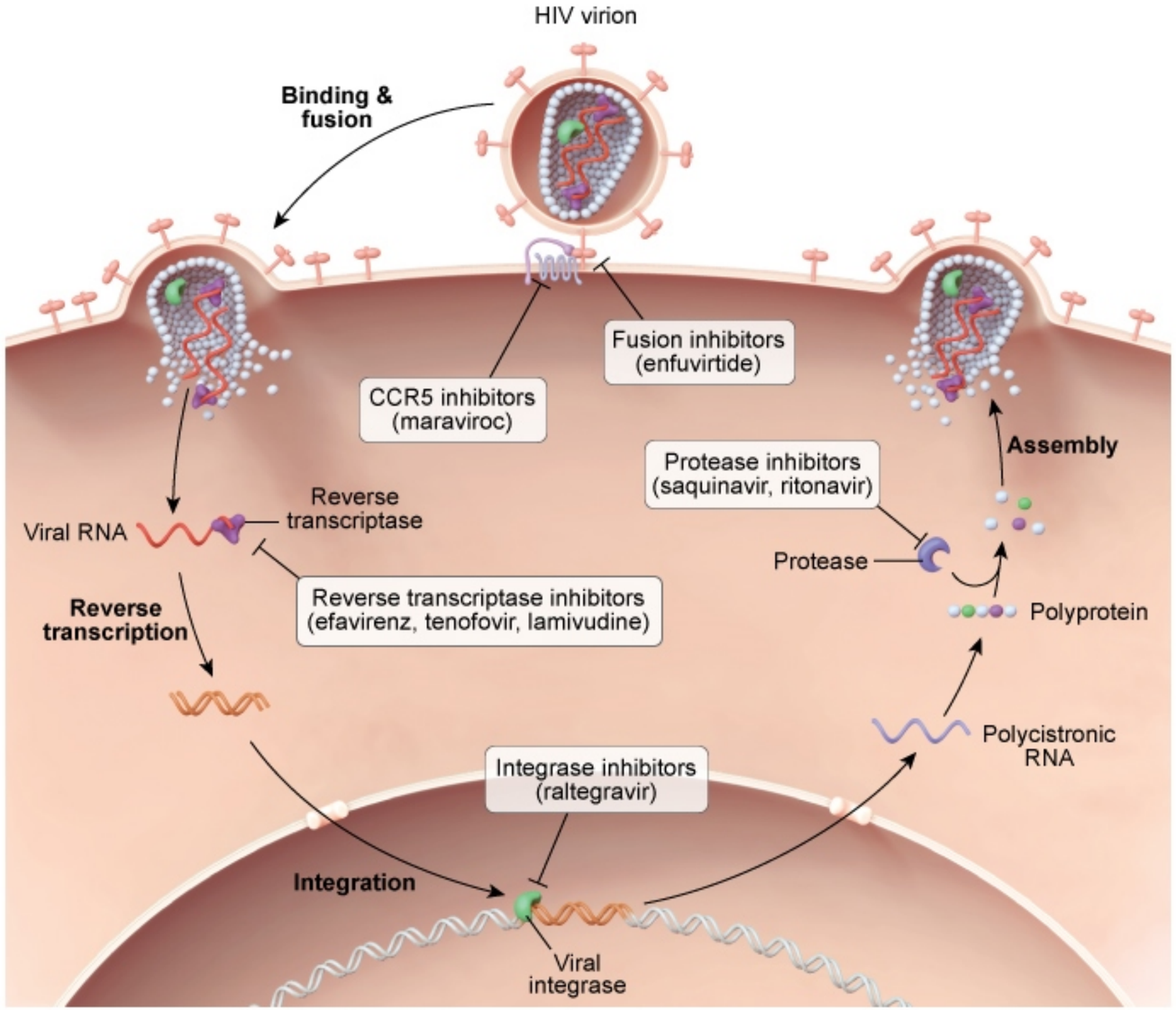

©UWorld

©UWorld

The **HIV genome** contains 3 major genes (***env***, ***gag***, and ***pol***) that are transcribed as **polycistronic mRNA** and translated into **polyproteins** in the endoplasmic reticulum. The *gag* and *pol* polyprotein products (**gag-pol**) are cleaved by **HIV protease** into individual HIV enzymes and structural proteins.

Protease inhibitors inhibit HIV protease from cleaving the gag-pol polyproteins, which results in the formation of immature, noninfectious virions. Protease inhibitors are a common component of first-line HIV antiretroviral therapy and are denoted by medications that end in "**navir**" (eg, darunavir, atazanavir, ritonavir).

(Choice A) The HIV envelope proteins gp120 and gp41 mediate viral attachment and fusion with the host cell membrane. These proteins are generated as a polyprotein (gp160) from the *env* gene. Unlike the gag-pol polyprotein, which is cleaved by HIV protease, the env polyprotein is cleaved by a host protease.

(Choices B and D) The *pol* gene encodes the major HIV enzymes: reverse transcriptase (RT), integrase, and protease. RT converts the HIV RNA genome into complementary double-stranded DNA; it also destroys the HIV RNA genomic template during transcription (ribonuclease H activity). RT is inhibited by nucleoside/nonnucleoside reverse transcriptase inhibitors. Integrase inserts complementary viral DNA into the host chromosome. Integrase strand transfer inhibitors block the function of this enzyme. Both RT and integrase inhibitors block viral replication, but neither are associated with immature virions containing polyproteins.

(Choice E) The HIV genome encodes for several regulatory proteins that are required for viral replication. However, all virus-encoded proteins are translated by host ribosomes, and blockade of protein translation would not be associated with the formation of polyproteins.

Educational objective:
The HIV genome contains 3 major structural genes that are translated as polyproteins and subsequently cleaved by host protease (*env* gene products) or viral protease (*gag-pol* gene products) into the individual proteins that compose the HIV virus. Protease inhibitors block viral protease from cleaving gag-pol polyproteins, which results in the formation of immature virions that are noninfectious.

Pathology	Gastrointestinal & Nutrition	Antiretroviral therapy
Subject	System	Topic

A 48-year-old male is admitted to the hospital with severe epigastric abdominal pain and vomiting after an episode of binge-drinking. Four weeks later, he is found to have a palpable upper abdominal mass and a cystic lesion is visualized on computed tomography scanning (see image below, asterisk marks the lesion).

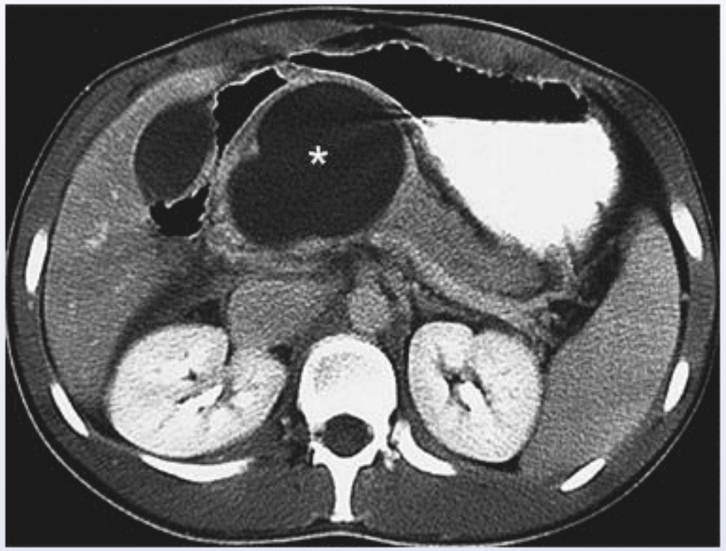

The inner walls of the lesion are most likely lined with:

- A. Glycogen-rich cuboidal epithelium
- B. Columnar mucinous epithelium
- C. Atypical cells forming papillary projections
- D. Fibrous and granulation tissue
- E. Endothelial cells

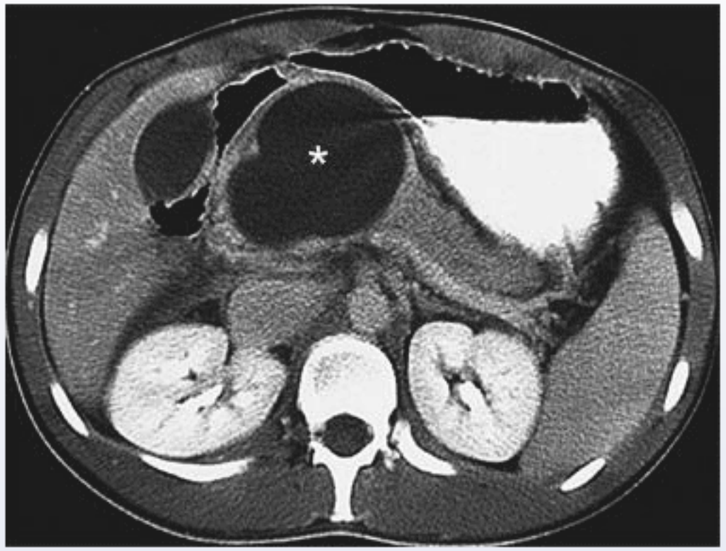

The inner walls of the lesion are most likely lined with:

A. Glycogen-rich cuboidal epithelium

B. Columnar mucinous epithelium

C. Atypical cells forming papillary projections

D. Fibrous and granulation tissue

E. Endothelial cells

Submit

1 2 3 4 5 6 7 8 9 10 11 12 13 14 15 16 17 18 19 20 21 22 23 24 25 26 27 28 29 30

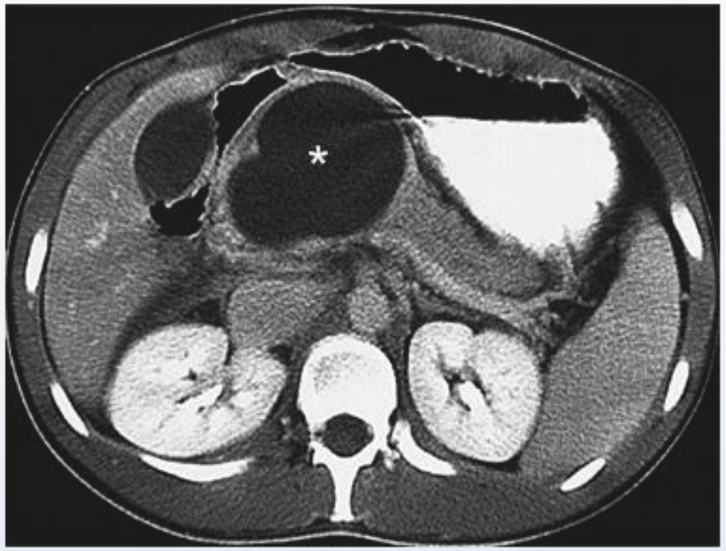

The inner walls of the lesion are most likely lined with:

A. Glycogen-rich cuboidal epithelium (13%)

B. Columnar mucinous epithelium (31%)

C. Atypical cells forming papillary projections (5%)

✓ D. Fibrous and granulation tissue (42%)

E. Endothelial cells (7%)

Omitted
Correct answer

42%
Answered correctly

05 secs
Time Spent

06/25/2020
Last Updated

This CT image shows a pancreatic pseudocyst, a potential complication of pancreatitis. In acute pancreatitis, proteolytic enzymes may disrupt the walls of the pancreatic ducts and cause leakage of pancreatic secretions into the peripancreatic space. This fluid has a high pancreatic enzyme content and induces an inflammatory reaction in the walls of the surrounding organs. Granulation tissue forms, encapsulating the fluid collection and forming a pseudocyst.

In contrast to a true cyst with walls lined by epithelial cells, the walls of a pseudocyst consist of granulation tissue and no epithelial lining. Fibrosis, thickening and organization of the walls occur with time. The formation of firm fibrotic pseudocyst walls ("maturation" of the pseudocyst) takes about 4 to 6 weeks following the episode of acute pancreatitis.

The most common location for a pseudocyst is in the lesser peritoneal sac, bordered by the stomach, duodenum and transverse colon. The pseudocyst walls are closely adherent to the surrounding hollow organs. The pseudocyst in the CT image above is located in the lesser sac, posterior to the stomach.

(Choice A) Glycogen-rich cuboidal epithelium is seen in serous pancreatic neoplasms.

(Choice B) Columnar mucinous epithelium is typically found in mucinous cystic neoplasms of the pancreas.

(Choice C) Atypical cells forming papillary projections are seen in the papillary variant of pancreatic adenocarcinoma.

(Choice E) Endothelial cells are not found in the wall of the pseudocyst.

Educational Objective:
Pancreatic pseudocyst is a common complication of acute pancreatitis. It is a collection of fluid rich in enzymes and inflammatory debris. Its walls consist of granulation tissue and fibrosis. Unlike true cysts, pseudocysts are not lined by epithelium.

Pathology	Gastrointestinal & Nutrition	Acute pancreatitis
Subject	System	Topic

Copyright © UWorld. All rights reserved.

A 70-year-old man comes to the office due to persistent epigastric discomfort and nausea for the past several months. He has also noticed black-colored stools on several occasions. Medical history is notable for hypertension and osteoarthritis. The patient emigrated from rural China 5 years ago to live with his daughter. He does not use tobacco, alcohol, or illicit drugs. Physical examination shows a thin male with pale mucous membranes, an enlarged left supraclavicular lymph node, and epigastric tenderness on deep palpation. Stool testing for occult blood is positive. Upper gastrointestinal endoscopy reveals a 3-cm ulceration at the gastric antrum, with a heaped-up irregular border. Biopsy from the edge of the ulcer reveals glandular structures containing intestinal-like columnar cells. Which of the following most likely predisposed this patient to his current condition?

A. Chronic use of nonsteroidal anti-inflammatory drugs

B. Excessive consumption of salt-preserved foods

C. Frequent intake of high-temperature beverages

D. Functional disruption of gastroesophageal junction

E. Increased gastrin production from a pancreatic mass

Submit

A 70-year-old man comes to the office due to persistent epigastric discomfort and nausea for the past several months. He has also noticed black-colored stools on several occasions. Medical history is notable for hypertension and osteoarthritis. The patient emigrated from rural China 5 years ago to live with his daughter. He does not use tobacco, alcohol, or illicit drugs. Physical examination shows a thin male with pale mucous membranes, an enlarged left supraclavicular lymph node, and epigastric tenderness on deep palpation. Stool testing for occult blood is positive. Upper gastrointestinal endoscopy reveals a 3-cm ulceration at the gastric antrum, with a heaped-up irregular border. Biopsy from the edge of the ulcer reveals glandular structures containing intestinal-like columnar cells. Which of the following most likely predisposed this patient to his current condition?

- A. Chronic use of nonsteroidal anti-inflammatory drugs (22%)
- ✓ B. Excessive consumption of salt-preserved foods (58%)
- C. Frequent intake of high-temperature beverages (5%)
- D. Functional disruption of gastroesophageal junction (4%)
- E. Increased gastrin production from a pancreatic mass (9%)

Omitted
Correct answer
B

58%
Answered correctly

01 sec
Time Spent

05/07/2020
Last Updated

Explanation

Gastric adenocarcinoma	

Gastric adenocarcinoma	
Risk factors	• High-salt diet • N-nitroso–containing compounds (eg, processed meat, tobacco) • Chronic *Helicobacter pylori* infection • Autoimmune chronic atrophic gastritis • Obesity
Clinical features	• Early satiety, weight loss • Epigastric pain, melena • Left supraclavicular &/or umbilical lymphadenopathy
Gross appearance/ histopathology	Intestinal type: • Ulcerated mass with irregular rolled or heaped-up edges • Glandular structures with intestinal-like columnar or cuboidal cells (similar to colon adenocarcinoma) Diffuse: • Plaque-like infiltration of stomach (eg, linitis plastica) • Signet-ring cells without glandular structures

This patient with epigastric pain, occasional melena, and left supraclavicular lymphadenopathy (ie, Virchow node) has intestinal-type **gastric adenocarcinoma**, the most common primary gastric malignancy. It is typically visualized endoscopically as an **ulcerated mass** with irregular folded or heaped-up edges. Histologically, intestinal-type gastric cancer resembles colon adenocarcinoma and is characterized by **glandular** structures containing **intestinal-like columnar** (or cuboidal) cells.

Gastric cancer occurs with the highest incidence in patients from **Eastern Asia**, Eastern Europe, and South America, possibly due to the increased consumption of **salt-preserved foods** (eg, salt-cured fish), which directly damage the gastric epithelium and potentiate the effects of carcinogens. Common carcinogens associated with gastric cancer include n-nitroso–containing compounds (eg, tobacco, processed meat) and

carcinogens. Common carcinogens associated with gastric cancer include n-nitroso–containing compounds (eg, tobacco, processed meat) and chronic *Helicobacter pylori* infection, both of which may also be present at increased levels in these populations. Other risk factors include obesity and autoimmune atrophic gastritis.

(Choices A and E) Chronic nonsteroidal anti-inflammatory drug use and gastrin-producing tumors (ie, Zollinger-Ellison syndrome) are associated with benign peptic ulcer disease, not gastric adenocarcinoma. Benign ulcers are typically clean-based with regular borders (as opposed to this patient's ulcerated lesion with irregular, heaped-up borders); in addition, intestinal metaplasia is unexpected.

(Choice C) Excessive consumption of hot beverages is associated with esophageal squamous cell carcinoma, not gastric adenocarcinoma.

(Choice D) Disruption of the lower esophageal sphincter enables gastric acid to reflux into the esophagus, which predisposes patients to esophageal intestinal metaplasia (eg, Barrett esophagus) and ultimately esophageal adenocarcinoma. However, this is not a risk factor for gastric adenocarcinoma.

Educational objective:
Intestinal-type gastric adenocarcinoma is visualized endoscopically as an ulcerated mass with irregular folded or heaped-up edges. Histologically, it resembles colon adenocarcinoma and is characterized by glandular structures containing intestinal-like columnar (or cuboidal) cells. Risk factors include *Helicobacter pylori* infection, a high-salt diet, n-nitroso–containing compounds, and autoimmune atrophic gastritis.

References

- Characteristics of gastric cancer in Asia.
- Review of salt consumption and stomach cancer risk: epidemiological and biological evidence.
- The effects of anti-inflammatory drug treatment in gastric cancer prevention: an update of a meta-analysis.
- A prospective study of tea drinking temperature and risk of esophageal squamous cell carcinoma.

Pathology	Gastrointestinal & Nutrition	Gastric cancer
Subject	System	Topic

Copyright © UWorld. All rights reserved.

1 2 3 4 5 6 7 8 9 10 11 12 13 14 15 16 17 18 19 20 21 22 23 24 25 26 27 28 29 30

A 46-year-old woman comes to the office with persistent diarrhea, weight loss, and abdominal pain. Her diarrhea started several months ago. She has no fever, melena, or hematochezia. The patient has not traveled outside of the country and has not drunk from any untreated freshwater sources. She has had no recent hospitalizations or antibiotic use. Her sister has a history of celiac disease. Upper endoscopy reveals postbulbar duodenal and jejunal ulcers. This patient most likely has a tumor secreting which of the following molecules?

- A. Gastrin
- B. Glucagon
- C. Insulin
- D. Serotonin
- E. Somatostatin
- F. Vasoactive intestinal polypeptide

Submit

1 2 3 4 5 6 7 8 9 10 11 12 13 14 15 16 17 18 19 20 21 22 23 24 25 26 27 28 29 30

A 46-year-old woman comes to the office with persistent diarrhea, weight loss, and abdominal pain. Her diarrhea started several months ago. She has no fever, melena, or hematochezia. The patient has not traveled outside of the country and has not drunk from any untreated freshwater sources. She has had no recent hospitalizations or antibiotic use. Her sister has a history of celiac disease. Upper endoscopy reveals postbulbar duodenal and jejunal ulcers. This patient most likely has a tumor secreting which of the following molecules?

- ✓ A. Gastrin (73%)
- B. Glucagon (0%)
- C. Insulin (0%)
- D. Serotonin (3%)
- E. Somatostatin (1%)
- F. Vasoactive intestinal polypeptide (20%)

Omitted
Correct answer
A

73%
Answered correctly

02 secs
Time Spent

06/02/2020
Last Updated

Explanation

Zollinger-Ellison syndrome

Settings

1
2
3
4
5
6
7
8
9
10
11
12
13
14
15
16
17
18
19
20
21
22
23
24
25
26
27
28
29
30

Item 16 of 40
Question Id: 586

Mark | Previous | Next | Full Screen | Tutorial | Lab Values | Notes | Calculator | Reverse Color | Text Zoom | Settings

Zollinger-Ellison syndrome

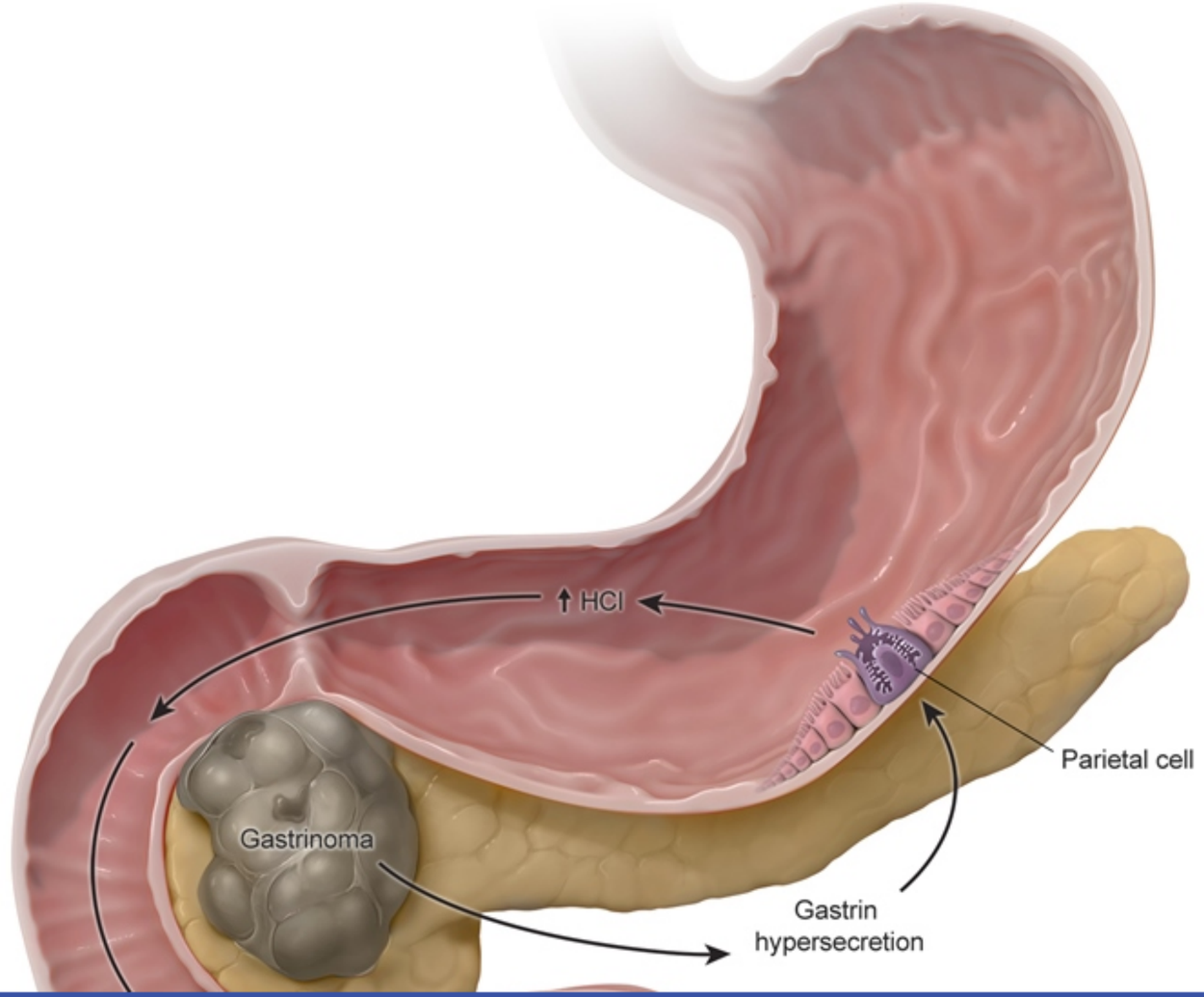

Block Time Remaining: 00:00:36
TUTOR

3 | Feedback | Suspend | End Block

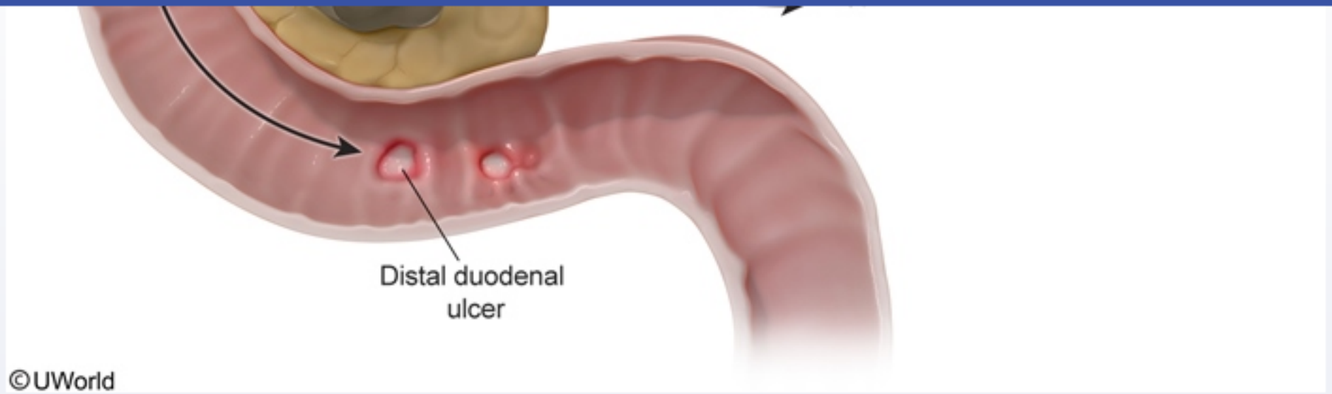

This patient's clinical presentation is highly suggestive of **Zollinger-Ellison syndrome** (ZES). ZES is caused by gastrin-secreting neuroendocrine tumors (**gastrinomas**) that are most commonly located in the small intestine or pancreas. The gastrin produced by these tumors stimulates gastric acid production, often resulting in multiple **peptic ulcers** that can be located **beyond the duodenal bulb** and are often refractory to therapy. Patients typically experience **abdominal pain** and acid reflux. They may also have **diarrhea** as gastric acid damages intestinal epithelial cells and inactivates pancreatic enzymes, preventing proper nutrient absorption.

The diagnosis of gastrinoma is made by measuring basal and stimulated gastrin levels (secretin stimulation test). Patients with ZES should undergo testing (eg, serum calcium, prolactin level) to exclude **multiple endocrine neoplasia type 1** due to the strong association between these conditions.

(Choice B) Glucagonomas are rare pancreatic alpha-cell tumors that present with diabetes mellitus and a raised erythematous rash that typically affects the groin (necrolytic migratory erythema).

(Choice C) Insulinomas are pancreatic beta-cell tumors that secrete insulin autonomously, regardless of blood glucose levels. As a result, patients usually have high circulating insulin/C-peptide levels and symptoms of hypoglycemia (eg, tremor, confusion).

(Choice D) Carcinoid syndrome is most frequently caused by neuroendocrine tumors originating in the small intestine that have metastasized to the liver. These tumors secrete products such as serotonin and bradykinin, resulting in diarrhea, episodic flushing, right-sided valvular heart disease, and wheezing.

(Choice E) Somatostatinomas are rare tumors of the pancreatic D cells that present with diabetes mellitus (diminished insulin secretion)

(Choice B) Glucagonomas are rare pancreatic alpha-cell tumors that present with diabetes mellitus and a raised erythematous rash that typically affects the groin (necrolytic migratory erythema).

(Choice C) Insulinomas are pancreatic beta-cell tumors that secrete insulin autonomously, regardless of blood glucose levels. As a result, patients usually have high circulating insulin/C-peptide levels and symptoms of hypoglycemia (eg, tremor, confusion).

(Choice D) Carcinoid syndrome is most frequently caused by neuroendocrine tumors originating in the small intestine that have metastasized to the liver. These tumors secrete products such as serotonin and bradykinin, resulting in diarrhea, episodic flushing, right-sided valvular heart disease, and wheezing.

(Choice E) Somatostatinomas are rare tumors of the pancreatic D cells that present with diabetes mellitus (diminished insulin secretion), cholelithiasis (inhibition of cholecystokinin release), and diarrhea/steatorrhea (inhibition of pancreatic enzyme/bicarbonate secretion).

(Choice F) Vasoactive intestinal polypeptide is secreted by VIPomas, rare neuroendocrine tumors of the pancreas. Patients typically have diarrhea that persists with fasting, achlorhydria, and hypokalemia.

Educational objective:
Zollinger-Ellison syndrome is caused by gastrin-secreting tumors (gastrinomas) involving the small intestine or pancreas. Patients typically have peptic ulcers (often beyond the duodenal bulb), abdominal pain/acid reflux, and diarrhea. The condition is frequently associated with multiple endocrine neoplasia type 1.

References

- Gastrinoma Zollinger-Ellison-syndrome.
- Hypergastrinemia.

Pathology	Gastrointestinal & Nutrition	Zollinger ellison syndrome
Subject	System	Topic

Copyright © UWorld. All rights reserved.

A 3-week-old male born to a 23-year-old Caucasian primigravida develops projectile non-bilious vomiting after every meal. Abdominal inspection reveals prominent peristalsis in the epigastrium and an olive-sized mass is felt on deep palpation of the right upper abdomen. The mass most likely represents:

A. Infection focus

B. Neoplastic cell proliferation

C. Smooth muscle hypertrophy

D. Pancreatic juice accumulation

E. Biliary duct distension

Submit

1 2 3 4 5 6 7 8 9 10 11 12 13 14 15 16 17 18 19 20 21 22 23 24 25 26 27 28 29 30

A 3-week-old male born to a 23-year-old Caucasian primigravida develops projectile non-bilious vomiting after every meal. Abdominal inspection reveals prominent peristalsis in the epigastrium and an olive-sized mass is felt on deep palpation of the right upper abdomen. The mass most likely represents:

- A. Infection focus (1%)
- B. Neoplastic cell proliferation (1%)
- ✓ C. Smooth muscle hypertrophy (85%)
- D. Pancreatic juice accumulation (1%)
- E. Biliary duct distension (9%)

Omitted
Correct answer
C

85%
Answered correctly

02 secs
Time Spent

05/25/2020
Last Updated

Explanation

Congenital pyloric stenosis is a relatively common disorder that is encountered primarily in male infants (at a 3:1 ratio) and characterized by a multifactorial pattern of inheritance. Infants typically present with recurrent projectile nonbilious vomiting, and physical examination demonstrates visible peristalsis and the presence of an olive-sized mass in the distal stomach or pyloric region. The mass is thought to develop secondary to hypertrophy of the pyloric muscularis mucosae. The narrowing of the pyloric channel is thought to be exacerbated by localized edema and inflammation. The stenosis is relieved by surgical splitting of the muscle.

(Choices A, D, and E) Infection, pancreatic juice accumulation, and biliary duct distension are not associated with pyloric stenosis.

E. Biliary duct distension (9%)

Omitted
Correct answer
C

85%
Answered correctly

02 secs
Time Spent

05/25/2020
Last Updated

Explanation

Congenital pyloric stenosis is a relatively common disorder that is encountered primarily in male infants (at a 3:1 ratio) and characterized by a multifactorial pattern of inheritance. Infants typically present with recurrent projectile nonbilious vomiting, and physical examination demonstrates visible peristalsis and the presence of an olive-sized mass in the distal stomach or pyloric region. The mass is thought to develop secondary to hypertrophy of the pyloric muscularis mucosae. The narrowing of the pyloric channel is thought to be exacerbated by localized edema and inflammation. The stenosis is relieved by surgical splitting of the muscle.

(Choices A, D, and E) Infection, pancreatic juice accumulation, and biliary duct distension are not associated with pyloric stenosis.

(Choice B) Acquired pyloric stenosis occurs in adults and is associated with gastritis, peptic ulcers in the pylorus, or a neoplastic process (eg, carcinoma of the pyloric region or lymphoma). Neoplasm in this area would not be expected in an infant, however.

Educational Objective:
Congenital pyloric stenosis arises secondary to hypertrophy of the pyloric muscularis mucosae.

Pathology	Gastrointestinal & Nutrition	Hypertrophic pyloric stenosis
Subject	System	Topic

Copyright © UWorld. All rights reserved.

Settings

1 2 3 4 5 6 7 8 9 10 11 12 13 14 15 16 17 18 19 20 21 22 23 24 25 26 27 28 29 30

Item 18 of 40
Question Id: 57

Mark | Previous | Next | Full Screen | Tutorial | Lab Values | Notes | Calculator | Reverse Color | Text Zoom | Settings

"Moldy" grains in some regions of China contain a substance that causes a specific G-to-T mutation in gene p53. The population in these regions is expected to be at an increased risk of which of the following diseases?

A. Lung cancer
B. Infectious diarrhea
C. Dilated cardiomyopathy
D. Liver cancer
E. Congenital heart defects
F. Hypothyroidism
G. Osteoporosis
H. Pancreatic cancer

Submit

Block Time Remaining: 00:00:39
TUTOR

Feedback | Suspend | End Block

"Moldy" grains in some regions of China contain a substance that causes a specific G-to-T mutation in gene p53. The population in these regions is expected to be at an increased risk of which of the following diseases?

- A. Lung cancer (16%)
- B. Infectious diarrhea (2%)
- C. Dilated cardiomyopathy (0%)
- ✓ D. Liver cancer (64%)
- E. Congenital heart defects (0%)
- F. Hypothyroidism (0%)
- G. Osteoporosis (1%)
- H. Pancreatic cancer (13%)

Omitted
Correct answer
D

64%
Answered correctly

02 secs
Time Spent

02/03/2020
Last Updated

Explanation

When the humidity and temperature are favorable, specific strains of the fungi *Aspergillus flavus* and *Aspergillus parasiticus* grow on foods such as corn, soybeans, and peanuts, producing aflatoxins as a byproduct. These aflatoxins are categorized as A1, B2, G1, and G2, with aflatoxin B1

Omitted
Correct answer
D

64%
Answered correctly

02 secs
Time Spent

02/03/2020
Last Updated

Explanation

When the humidity and temperature are favorable, specific strains of the fungi *Aspergillus flavus* and *Aspergillus parasiticus* grow on foods such as corn, soybeans, and peanuts, producing aflatoxins as a byproduct. These aflatoxins are categorized as A1, B2, G1, and G2, with aflatoxin B1 the most common and most toxic.

High levels of dietary aflatoxin intake have been strongly associated with hepatocellular carcinoma. In certain areas within Asia and Africa where aflatoxin B1 exposure is high, p53 mutations have been identified in most individuals who developed hepatocellular carcinoma. More than 90% of these aflatoxin-induced p53 mutations are a classic G:C → T:A transversion in codon 249. In addition, research suggests that the combination of chronic aflatoxin exposure and hepatitis B infection significantly increases the risk of developing hepatocellular carcinoma.

(Choices A, B, C, E, F, G, and H) Lung cancer, infectious diarrhea, dilated cardiomyopathy, congenital heart defects, hypothyroidism, osteoporosis, and pancreatic cancer are not associated with aflatoxin-induced mutation of the p53 gene.

Educational Objective:
High levels of dietary aflatoxin exposure is associated with a G:C → T:A transversion in codon 249 of the p53 gene, a mutation thought to greatly increase the risk of developing hepatocellular carcinoma.

Pathology	Gastrointestinal & Nutrition	Hepatocellular cancer
Subject	System	Topic

Copyright © UWorld. All rights reserved.

Settings

1 2 3 4 5 6 7 8 9 10 11 12 13 14 15 16 17 18 19 20 21 22 23 24 25 26 27 28 29 30

Item 19 of 40
Question Id: 1701

Mark | Previous | Next | Full Screen | Tutorial | Lab Values | Notes | Calculator | Reverse Color | Text Zoom | Settings

A 46-year-old man is brought to the emergency department by paramedics after an episode of large-volume hematemesis. He was going over some papers at work when he suddenly felt nauseated and started vomiting up bright red blood. Physical examination reveals a palpable spleen. Endoscopy shows bleeding esophageal varices. A liver biopsy performed 2 days later shows no abnormalities. Which of the following is the most likely cause of this patient's condition?

A. Acetaminophen toxicity

B. Long-term alcohol consumption

C. Budd-Chiari syndrome

D. Constrictive pericarditis

E. Portal vein thrombosis

Submit

Block Time Remaining: 00:00:40
TUTOR

3 | Feedback | Suspend | End Block

A 46-year-old man is brought to the emergency department by paramedics after an episode of large-volume hematemesis. He was going over some papers at work when he suddenly felt nauseated and started vomiting up bright red blood. Physical examination reveals a palpable spleen. Endoscopy shows bleeding esophageal varices. A liver biopsy performed 2 days later shows no abnormalities. Which of the following is the most likely cause of this patient's condition?

- A. Acetaminophen toxicity (3%)
- B. Long-term alcohol consumption (11%)
- C. Budd-Chiari syndrome (22%)
- D. Constrictive pericarditis (1%)
- ✓ E. Portal vein thrombosis (60%)

Omitted
Correct answer
E

60%
Answered correctly

01 sec
Time Spent

04/07/2020
Last Updated

Explanation

Portal vein thrombosis

Esophageal varices

Portal vein thrombosis

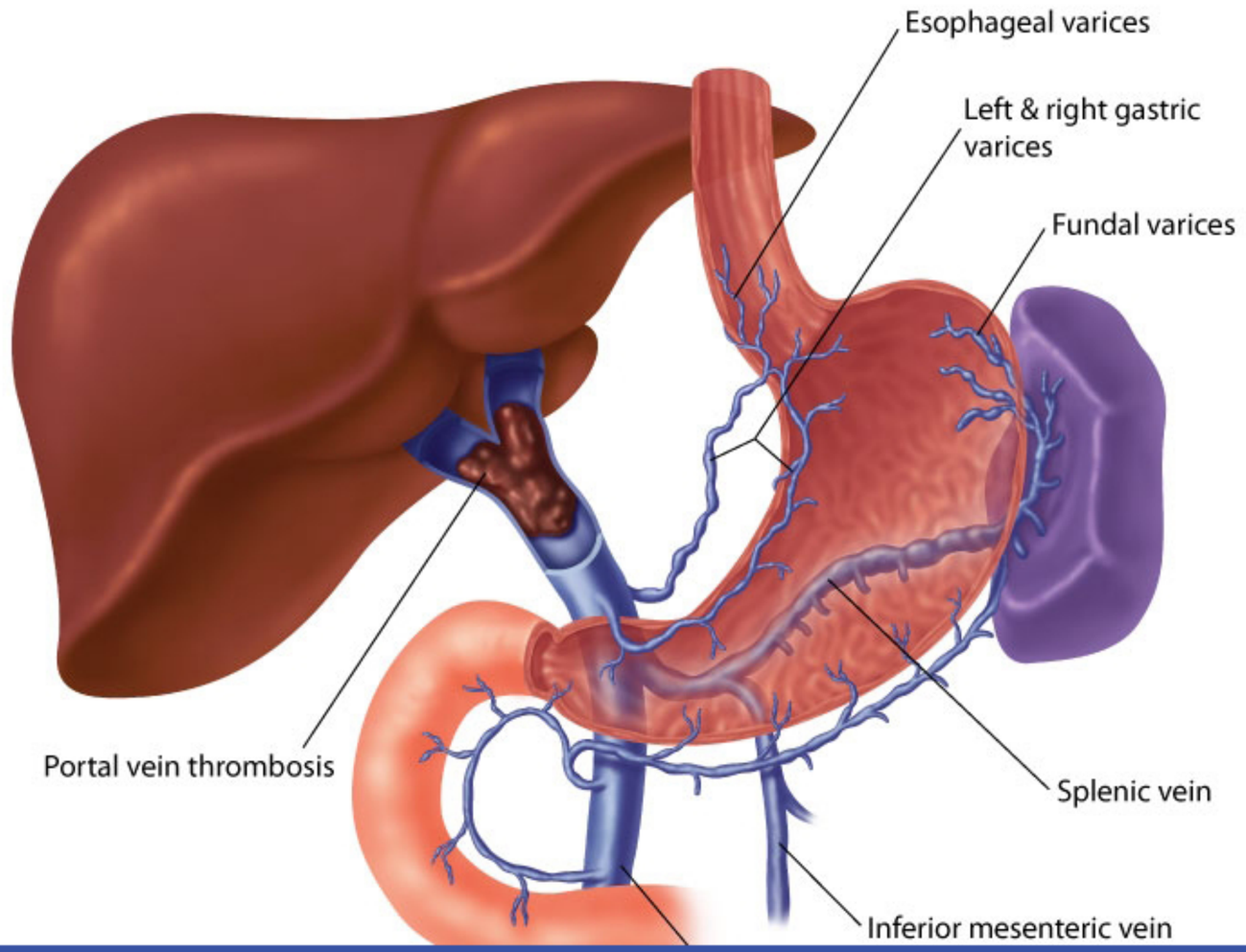

©UWorld

This patient is exhibiting signs of **portal hypertension**, including esophageal **varices** and **splenic enlargement**. Varices form in portal hypertension due to increased hydrostatic pressure in the portal system that causes blood to be shunted through portocaval anastomoses. This patient's **normal liver biopsy** indicates that a **presinusoidal process** is responsible for the portal hypertension. **Portal vein thrombosis** causes obstruction in portal venous flow upstream to the liver, causing portal hypertension while not affecting the liver parenchyma. **Ascites is uncommon** with portal vein thrombosis since sinusoidal hypertension does not develop.

(Choice A) Acetaminophen toxicity causes centrilobular hepatic necrosis and liver failure 24-48 hours following ingestion, depending on the amount consumed. This process would be obvious on liver biopsy.

(Choice B) Long-term alcohol consumption can causes hepatic cirrhosis, which can cause portal hypertension. However, hepatocyte injury and fibrosis would be evident on liver biopsy. Mallory-Weiss tears can also occur with heavy alcohol use, however, mucosal lacerations (not varices) would be seen on endoscopy.

(Choice C) In Budd-Chiari syndrome, there is occlusion of the hepatic vein, which drains blood from the liver and portal circulation into the systemic circulation. Liver biopsy shows centrilobular congestion and fibrosis.

(Choice D) Constrictive pericarditis causes blood to back up in the systemic venous circulation due to decreased cardiac output. This increases pressure within the liver in much the same way as Budd-Chiari syndrome and would present with similar findings.

Educational objective:
Portal vein thrombosis causes portal hypertension, splenomegaly, and varicosities at portocaval anastomoses. It does not cause histologic changes to the hepatic parenchyma. Ascites is uncommon as the obstruction is presinusoidal; ascites typically only develops in conditions that cause sinusoidal hypertension.

Pathology	Gastrointestinal & Nutrition	Esophageal varices
Subject	System	Topic

Copyright © UWorld. All rights reserved.

A 2-year-old Caucasian boy is hospitalized with abdominal pain and vomiting. After initial evaluation laparotomy is performed, and a portion of the intestine is resected (see the slide below).

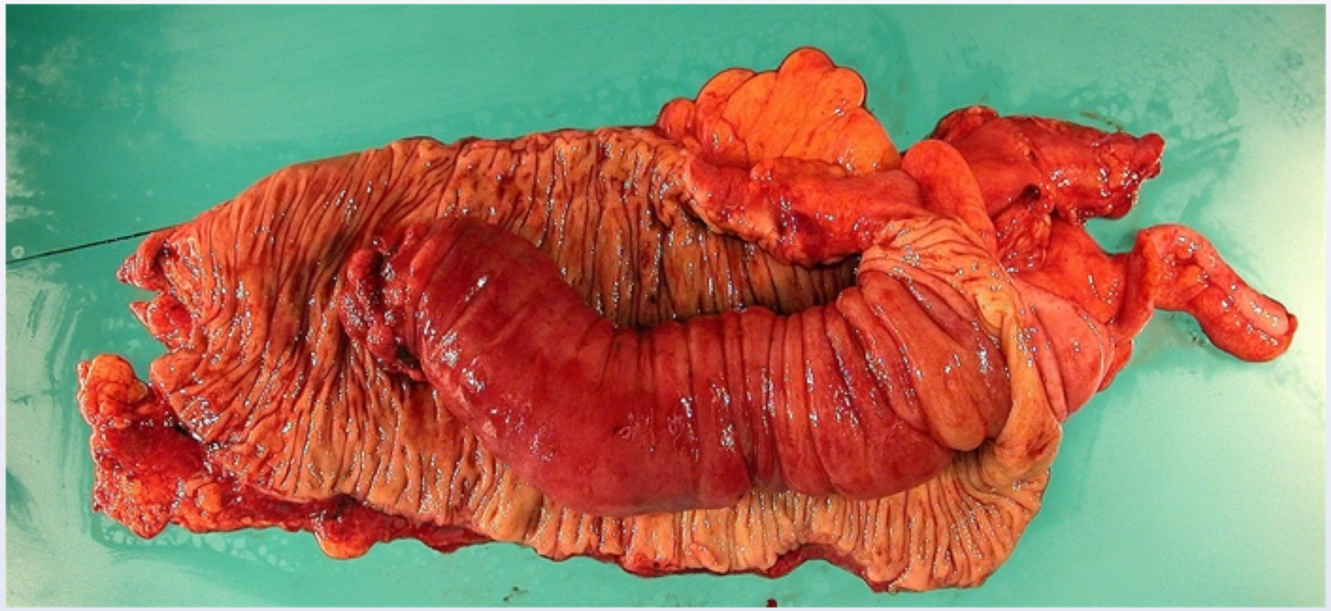

This patient most likely suffers from:

- A. Mesenteric adenitis
- B. Acute appendicitis
- C. Pseudomembranous colitis
- D. Ischemic colitis
- E. Collagenous colitis

Settings

1 2 3 4 5 6 7 8 9 10 11 12 13 14 15 16 17 18 19 20 21 22 23 24 25 26 27 28 29 30

Item 20 of 40
Question Id: 416

Mark | Previous | Next | Full Screen | Tutorial | Lab Values | Notes | Calculator | Reverse Color | Text Zoom | Settings

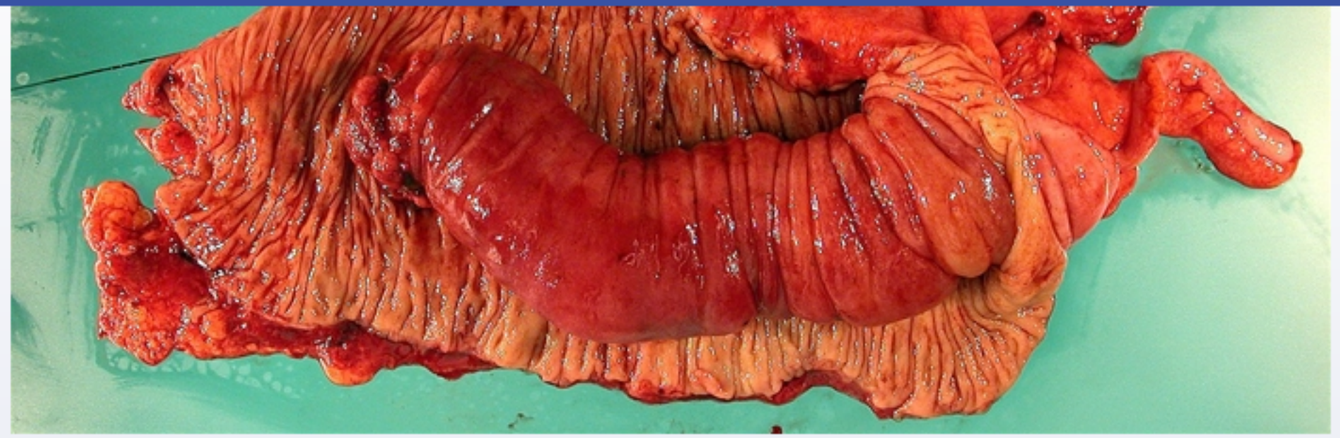

This patient most likely suffers from:

- A. Mesenteric adenitis (0%)
- B. Acute appendicitis (1%)
- C. Pseudomembranous colitis (0%)
- D. Ischemic colitis (2%)
- E. Collagenous colitis (0%)
- ✓ F. Intussusception (82%)
- G. Meckel diverticulitis (11%)

Omitted
Correct answer

82%
Answered correctly

03 secs
Time Spent

02/03/2020
Last Updated

Block Time Remaining: 00:00:44
TUTOR

2 | Feedback | Suspend | End Block

Omitted
Correct answer
F

82%
Answered correctly

03 secs
Time Spent

02/03/2020
Last Updated

Explanation

This is a surgical specimen that has a portion of the intestine open with a necrotic segment found in the lumen. This is a typical picture of intussusception, an invagination of a portion of the intestine into the lumen of the adjacent intestinal segment (imagine a collapsed telescope). Intussusception leads to impaired venous return from the invaginated segment of the bowel, which can cause ischemia and subsequent necrosis of the intestinal wall.

The most typical location for intussusception is at the ileocolic junction. The size differences in the adjacent segments of the intestine allow the small bowel to invaginate into the cecum. Intussusception is most common in children younger than 2 years old. In this age group, it often occurs without any structural cause (sometimes associated with viral infection). In patients older than 2 years of age, a lead point, such as Meckel diverticulum, foreign body, or intestinal tumor, should be sought.

Clinical presentation is colicky, intermittent abdominal pain, nausea, vomiting, and "currant jelly" stools (that contain blood and mucus). A tubular mass may be palpable in the lower right abdominal quadrant. Barium enema is diagnostic and may be therapeutic. If the intussusception does not resolve with barium enema, surgical intervention is mandated.

Educational Objective:
Intussusception most often occurs in children younger than 2 years of age and in the region of the ileocecal valve. It manifests with intermittent, severe, colicky abdominal pain, "currant jelly" stools, and sometimes a palpable mass in the right lower abdominal quadrant.

Pathology	Gastrointestinal & Nutrition	Intussusception
Subject	System	Topic

Copyright © UWorld. All rights reserved.

Settings

1 2 3 4 5 6 7 8 9 10 11 12 13 14 15 16 17 18 19 20 21 22 23 24 25 26 27 28 29 30

Item 21 of 40
Question Id: 253

Mark | Previous | Next | Full Screen | Tutorial | Lab Values | Notes | Calculator | Reverse Color | Text Zoom | Settings

A 68-year-old man comes to the office due to fatigue, weight loss, and constipation. He has refused to undergo screening colonoscopy for several years because "nobody in my family had colon cancers." Past medical history is notable for emphysema and stable angina. The patient has smoked a pack of cigarettes daily for 50 years and drinks alcohol occasionally. Physical examination is unremarkable. He is referred for colonoscopy, which reveals a circumferential mass encircling the sigmoid colon. Pathology is positive for adenocarcinoma. CT scan of the chest, abdomen, and pelvis is negative for signs of metastasis. Serum carcinoembryonic antigen assay is ordered. The results of this assay would be most useful for which of the following aspects of this patient's care?

- A. Determining the need for surgery
- B. Determining the type of chemotherapy
- C. Grading of the tumor
- D. Monitoring for residual disease
- E. Staging of the tumor

Submit

Block Time Remaining: 00:00:44
TUTOR

2 | Feedback | Suspend | End Block

A 68-year-old man comes to the office due to fatigue, weight loss, and constipation. He has refused to undergo screening colonoscopy for several years because "nobody in my family had colon cancers." Past medical history is notable for emphysema and stable angina. The patient has smoked a pack of cigarettes daily for 50 years and drinks alcohol occasionally. Physical examination is unremarkable. He is referred for colonoscopy, which reveals a circumferential mass encircling the sigmoid colon. Pathology is positive for adenocarcinoma. CT scan of the chest, abdomen, and pelvis is negative for signs of metastasis. Serum carcinoembryonic antigen assay is ordered. The results of this assay would be most useful for which of the following aspects of this patient's care?

- A. Determining the need for surgery (1%)
- B. Determining the type of chemotherapy (8%)
- C. Grading of the tumor (3%)
- ✓ D. Monitoring for residual disease (80%)
- E. Staging of the tumor (5%)

Omitted
Correct answer
D

80%
Answered correctly

01 sec
Time Spent

04/15/2020
Last Updated

Explanation

Carcinoembryonic antigen (CEA) is a glycoprotein involved in cell adhesion. It is produced in the embryonic pancreas, liver, and intestine and is also detected in minute amounts in the serum of healthy adults. CEA levels are increased in most patients with colon cancer. Elevated **preoperative CEA** levels are associated with a worse **prognosis**, and failure to normalize following surgery suggests **residual disease**. During long-term follow-up, rising CEA levels are a sensitive indicator of colorectal cancer **recurrence**. However, CEA has low sensitivity and specificity

Carcinoembryonic antigen (CEA) is a glycoprotein involved in cell adhesion. It is produced in the embryonic pancreas, liver, and intestine and is also detected in minute amounts in the serum of healthy adults. CEA levels are increased in most patients with colon cancer. Elevated **preoperative CEA** levels are associated with a worse **prognosis**, and failure to normalize following surgery suggests **residual disease**. During long-term follow-up, rising CEA levels are a sensitive indicator of colorectal cancer **recurrence**. However, CEA has low sensitivity and specificity for initial screening and diagnosis of colon cancer.

CEA levels are elevated in pancreatic, gastric, and breast malignancies along with other nonmalignant diseases (eg, inflammatory bowel disease, chronic obstructive pulmonary disease, cirrhosis, pancreatitis). CEA levels are also higher in smokers than nonsmokers.

(Choice A) Surgical resection is recommended for most patients with colon cancer unless there are unresectable metastases. The specific procedure recommended is dependent on stage and anatomical considerations rather than CEA levels.

(Choice B) Adjuvant chemotherapy is recommended for most patients with node-positive colorectal adenocarcinoma regardless of CEA levels.

(Choices C and E) Tumor grade describes the degree of tumor differentiation and is determined histologically. The stage of the tumor reflects the extent of its spread (eg, penetration of the bowel wall, lymph node invasion, distant metastases). Elevated CEA levels are associated with a worse prognosis regardless of tumor stage, but CEA measurement is not currently considered part of the initial staging evaluation.

Educational objective:
Carcinoembryonic antigen (CEA) levels are increased in colon cancer but are also elevated in a number of other conditions (eg, pancreatic cancer, COPD, cirrhosis). CEA cannot be used to diagnose colon cancer, but it is helpful for detecting residual disease and recurrence.

References

- Carcinoembryonic antigen in the staging and follow-up of patients with colorectal cancer.

Pathology	Gastrointestinal & Nutrition	Colorectal cancer
Subject	System	Topic

Copyright © UWorld. All rights reserved.

Researchers studying gastrointestinal pathophysiology analyze hundreds of gastric mucosal biopsy specimens taken from patients who underwent endoscopy at a local tertiary care center. They notice that colonization of the gastric antrum with S-shaped, gram-negative bacteria is associated with a decreased number of somatostatin-producing antral cells. Depletion of these cells from the gastric antrum is most likely to cause which of the following conditions?

A. Chronic pancreatitis

B. Duodenal ulcers

C. Gastric lymphoma

D. Gastric ulcers

E. Vitamin B_{12} deficiency

Submit

1 2 3 4 5 6 7 8 9 10 11 12 13 14 15 16 17 18 19 20 21 22 23 24 25 26 27 28 29 30

Researchers studying gastrointestinal pathophysiology analyze hundreds of gastric mucosal biopsy specimens taken from patients who underwent endoscopy at a local tertiary care center. They notice that colonization of the gastric antrum with S-shaped, gram-negative bacteria is associated with a decreased number of somatostatin-producing antral cells. Depletion of these cells from the gastric antrum is most likely to cause which of the following conditions?

A. Chronic pancreatitis (1%)
✓ B. Duodenal ulcers (62%)
C. Gastric lymphoma (2%)
D. Gastric ulcers (30%)
E. Vitamin B_{12} deficiency (2%)

Omitted
Correct answer
B

62%
Answered correctly

01 sec
Time Spent

03/21/2020
Last Updated

Explanation

***Helicobacter pylori* and duodenal ulcers**

Helicobacter pylori and duodenal ulcers

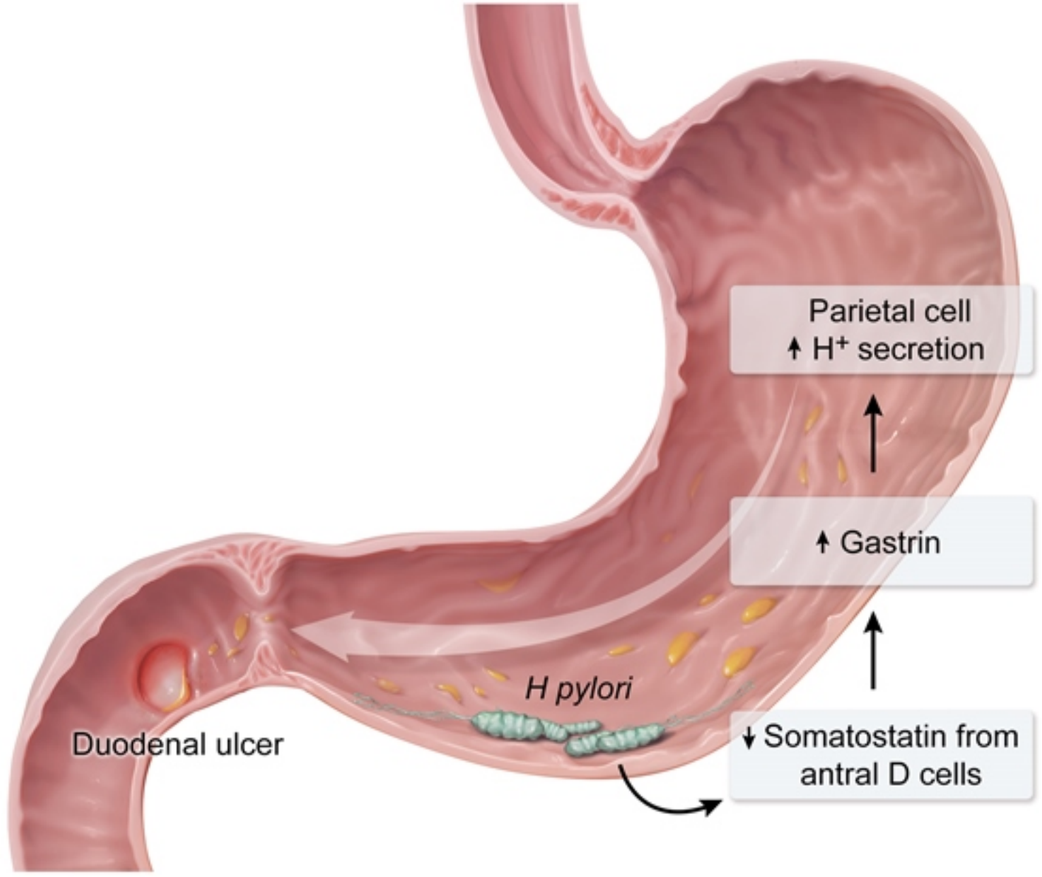

©UWorld

Helicobacter pylori is a motile, spiral-shaped, gram-negative bacteria found attached to the gastric mucosa or deep in the mucus layer overlying the gastric epithelium. It is protected from gastric acid by endogenous urease production: **urease** converts urea to ammonia, which alkalinizes the surrounding pH but injures gastric epithelial cells. Damage to the gastric mucosa is compounded by localized inflammation due to the immunologic response against *H pylori*.

©UWorld

Helicobacter pylori is a motile, spiral-shaped, gram-negative bacteria found attached to the gastric mucosa or deep in the mucus layer overlying the gastric epithelium. It is protected from gastric acid by endogenous urease production: **urease** converts urea to ammonia, which alkalinizes the surrounding pH but injures gastric epithelial cells. Damage to the gastric mucosa is compounded by localized inflammation due to the immunologic response against *H pylori*.

Chronic inflammation due to *H pylori* colonization in the **gastric antrum** leads to **depletion of somatostatin-producing cells** (delta cells), which are located mostly in the antrum. Somatostatin inhibits gastrin release from G-cells. In its absence, **elevated gastrin** levels act directly (via cholecystokinin B receptors) and indirectly (via histamine release by enterochromaffin-like cells) to **increase acid secretion** by parietal cells. In addition, *H pylori* releases cytotoxins that inhibit duodenal production of bicarbonate. The resultant increased acid load is emptied into the under-protected duodenum, leading to **duodenal ulcer** formation.

In contrast, gastric ulcers occur when *H pylori* colonizes the gastric body (corpus) **(Choice D)**. Chronic inflammation leads to multifocal atrophic gastritis and a reduction in the number of acid-producing parietal cells, which are located mostly in the gastric body. Delta cells in the antrum are not markedly reduced, therefore acid secretion is often low to normal. Gastric ulcer formation results from direct mucosal damage caused by bacterial products (eg, ammonia, cytotoxins) and the resultant inflammatory response. Unlike antral-predominant disease, corpus-predominant disease is associated with metaplasia and malignancies (eg, gastric lymphoma, adenocarcinoma) **(Choice C)**.

(Choice A) Chronic pancreatitis is not associated with *H pylori* infection. It is most frequently caused by chronic alcoholism or obstruction of the pancreatic ducts due to gallstones or malignancy.

(Choice E) Vitamin B_{12} deficiency can result from autoimmune gastritis. Autoimmune gastritis is characterized by autoantibodies against gastric parietal cells leading to inflammation of the gastric mucosa, parietal cell destruction, and achlorhydria. Its etiology is at least partially genetic.

Educational objective:
Helicobacter pylori antral gastritis is associated with the formation of duodenal ulcers due to increased gastric acid production. This increase in acidity is caused by unchecked gastrin production due to the destruction of somatostatin-secreting cells in the gastric antrum.

Pathology | Gastrointestinal & Nutrition | Peptic ulcer disease

Exhibit Display

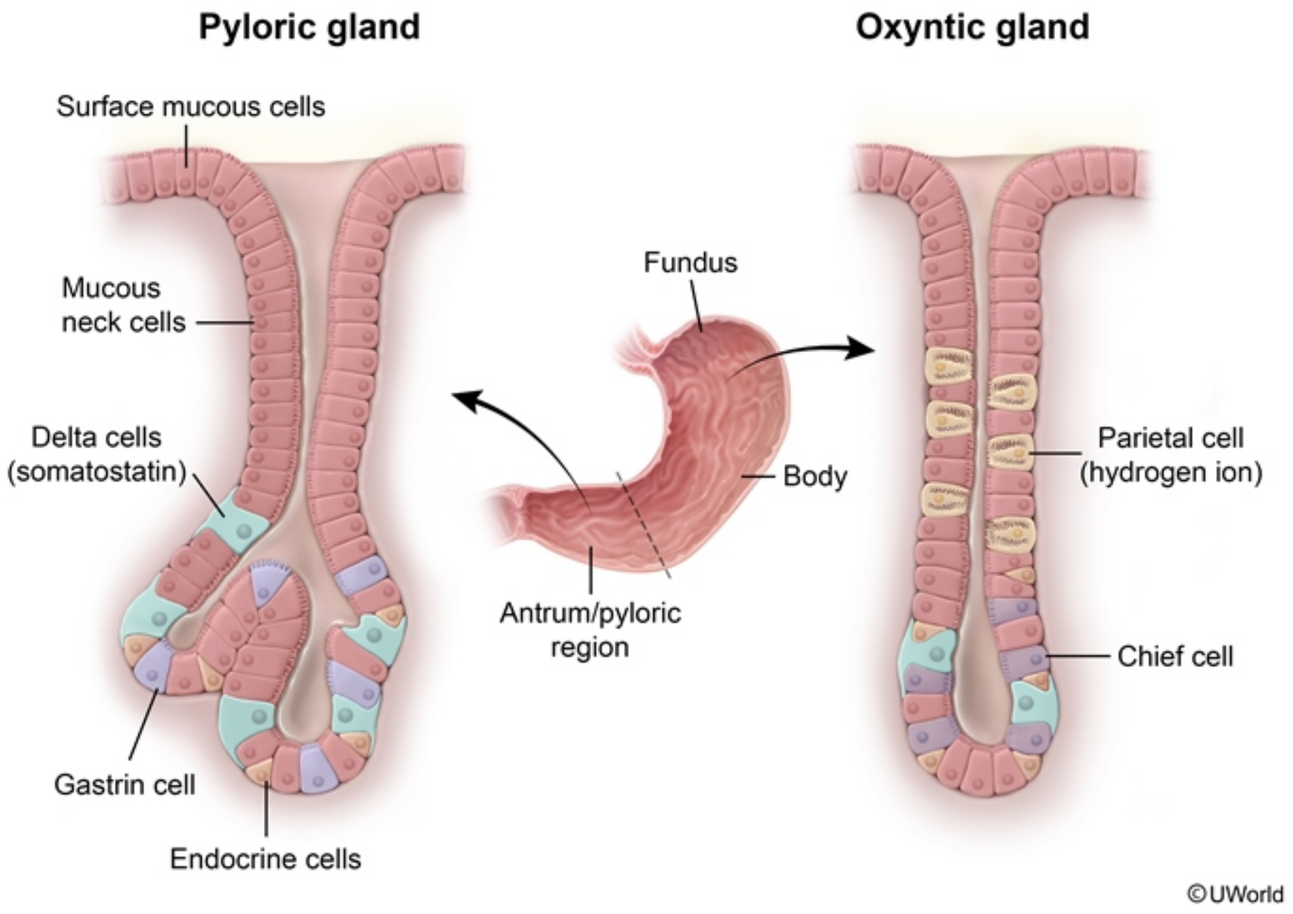

Zoom In | Zoom Out | Reset | Add To New Card | Existing Card

Pathology | Gastrointestinal & Nutrition | Peptic ulcer disease

Exhibit Display

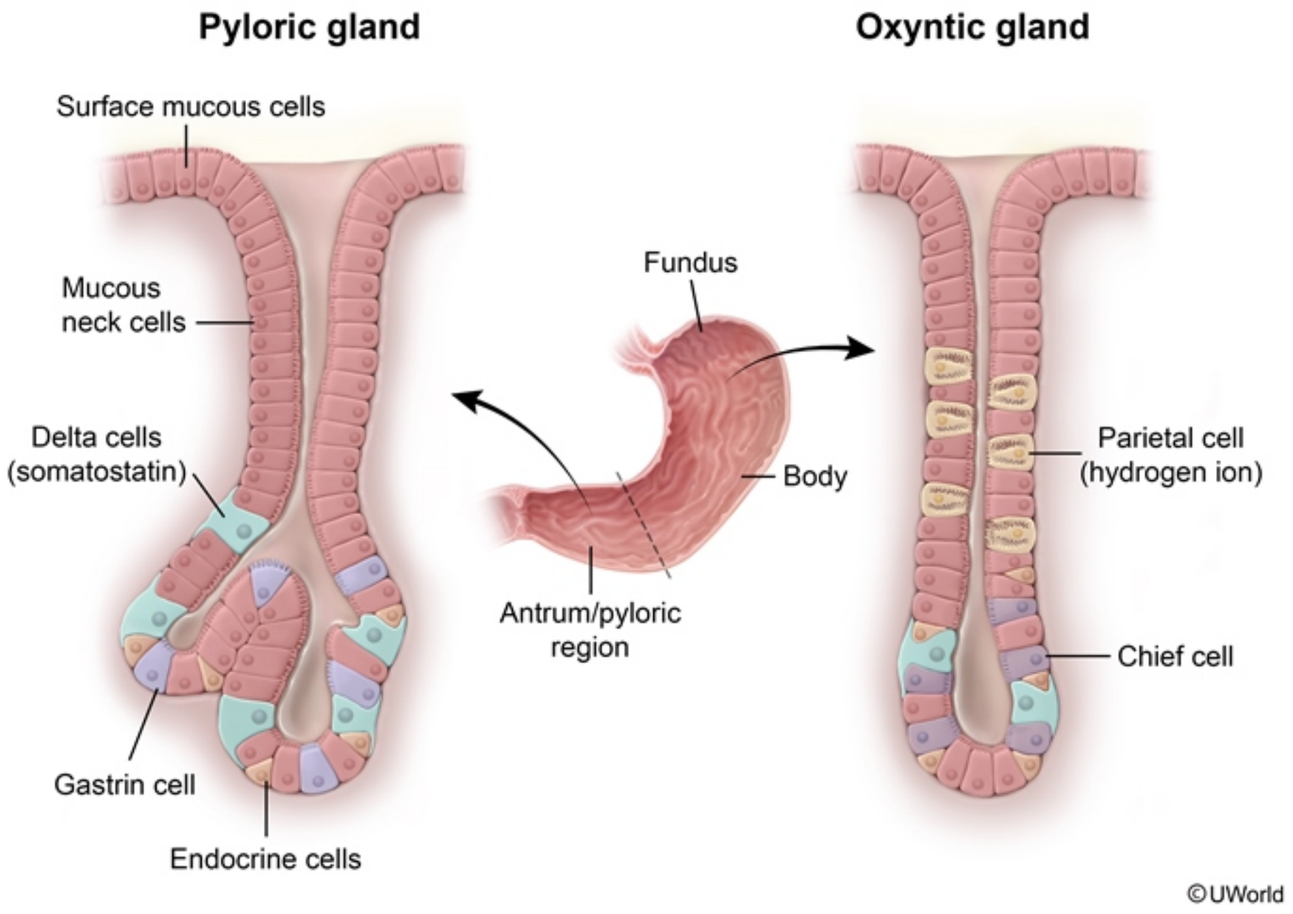

Zoom In | Zoom Out | Reset | Add To New Card | Existing Card

Pathology | Gastrointestinal & Nutrition | Peptic ulcer disease

surrounding pH but injures gastric epithelial cells. Damage to the gastric mucosa is compounded by localized inflammation due to the immunologic response against *H pylori*.

Chronic inflammation due to *H pylori* colonization in the **gastric antrum** leads to **depletion of somatostatin-producing cells** (delta cells), which are located mostly in the antrum. Somatostatin inhibits gastrin release from G-cells. In its absence, **elevated gastrin** levels act directly (via cholecystokinin B receptors) and indirectly (via histamine release by enterochromaffin-like cells) to **increase acid secretion** by parietal cells. In addition, *H pylori* releases cytotoxins that inhibit duodenal production of bicarbonate. The resultant increased acid load is emptied into the under-protected duodenum, leading to **duodenal ulcer** formation.

In contrast, gastric ulcers occur when *H pylori* colonizes the gastric body (corpus) **(Choice D)**. Chronic inflammation leads to multifocal atrophic gastritis and a reduction in the number of acid-producing parietal cells, which are located mostly in the gastric body. Delta cells in the antrum are not markedly reduced, therefore acid secretion is often low to normal. Gastric ulcer formation results from direct mucosal damage caused by bacterial products (eg, ammonia, cytotoxins) and the resultant inflammatory response. Unlike antral-predominant disease, corpus-predominant disease is associated with metaplasia and malignancies (eg, gastric lymphoma, adenocarcinoma) **(Choice C)**.

(Choice A) Chronic pancreatitis is not associated with *H pylori* infection. It is most frequently caused by chronic alcoholism or obstruction of the pancreatic ducts due to gallstones or malignancy.

(Choice E) Vitamin B_{12} deficiency can result from autoimmune gastritis. Autoimmune gastritis is characterized by autoantibodies against gastric parietal cells leading to inflammation of the gastric mucosa, parietal cell destruction, and achlorhydria. Its etiology is at least partially genetic.

Educational objective:
Helicobacter pylori antral gastritis is associated with the formation of duodenal ulcers due to increased gastric acid production. This increase in acidity is caused by unchecked gastrin production due to the destruction of somatostatin-secreting cells in the gastric antrum.

Pathology	Gastrointestinal & Nutrition	Peptic ulcer disease
Subject	System	Topic

Copyright © UWorld. All rights reserved.

A 72-year-old woman comes to the emergency department due to bloody bowel movements. One hour ago, the patient had a sudden urge to defecate and passed a large amount of bright red blood mixed with stool. Several minutes later, she had another episode with a small amount of blood. The patient reports no nausea, vomiting, abdominal pain, diarrhea, or fever and never had such symptoms before. She is hospitalized but has no further bleeding. Physical examination, including a digital rectal examination, is unremarkable. A colonoscopy performed after bowel preparation reveals the findings in the exhibit. There are no other abnormalities. Which of following is the most likely source of this patient's bleeding?

A. Abnormal arteriovenous channel

B. Diffusely eroded mucosal surface

C. Dilated and tortuous venous plexus

D. Disruption of vasa recta

E. Sloughed off polypoidal mass

Submit

Settings

1
2
3
4
5
6
7
8
9
10
11
12
13
14
15
16
17
18
19
20
21
22
23
24
25
26
27
28
29
30

Item 23 of 40
Question Id: 14901

Mark | Previous | Next | Full Screen | Tutorial | Lab Values | Notes | Calculator | Reverse Color | Text Zoom | Settings

Exhibit Display

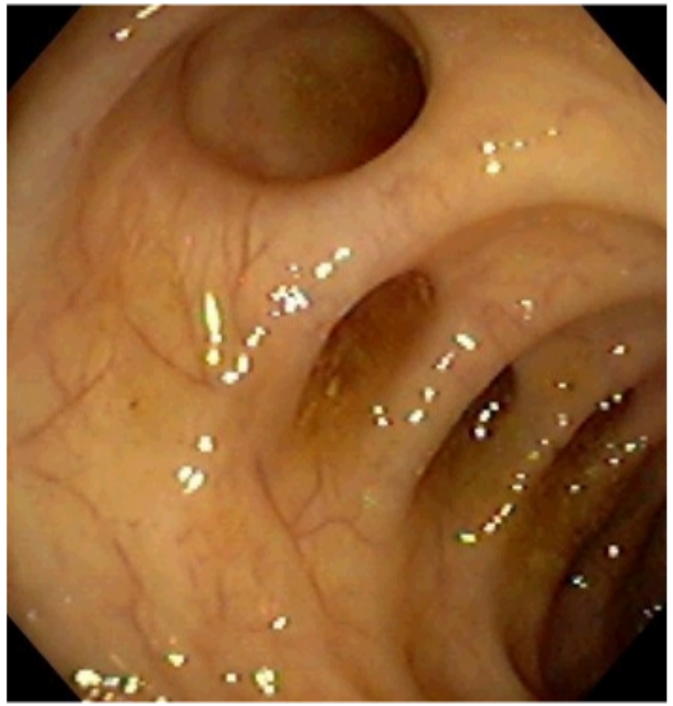

Zoom In | Zoom Out | Reset | Add To Flash Card

Block Time Remaining: 00:00:50
TUTOR

0 | Feedback | Suspend | End Block

A 72-year-old woman comes to the emergency department due to bloody bowel movements. One hour ago, the patient had a sudden urge to defecate and passed a large amount of bright red blood mixed with stool. Several minutes later, she had another episode with a small amount of blood. The patient reports no nausea, vomiting, abdominal pain, diarrhea, or fever and never had such symptoms before. She is hospitalized but has no further bleeding. Physical examination, including a digital rectal examination, is unremarkable. A colonoscopy performed after bowel preparation reveals the findings in the exhibit. There are no other abnormalities. Which of following is the most likely source of this patient's bleeding?

- A. Abnormal arteriovenous channel (6%)
- B. Diffusely eroded mucosal surface (17%)
- C. Dilated and tortuous venous plexus (7%)
- ✓ D. Disruption of vasa recta (63%)
- E. Sloughed off polypoidal mass (4%)

Omitted
Correct answer
D

63%
Answered correctly

07 secs
Time Spent

05/08/2020
Last Updated

Explanation

Diverticular disease	
	• Diverticulosis: ↑ intraluminal pressure causing herniation

Diverticular disease	
Etiology	• Diverticulosis: ↑ intraluminal pressure causing herniation through points of weakness (vasa recta penetration) • Diverticular bleeding: injury to exposed vasa recta • Diverticulitis: trapped food particles & ↑ intraluminal pressure causing microperforation
Symptoms	• Diverticulosis: none • Diverticular bleeding: painless hematochezia • Diverticulitis: left lower quadrant pain, nausea, vomiting, fever
Risk factors	• Diet high in red meat & fat & low in fiber • Obesity, physical inactivity, smoking

This patient with hematochezia had a colonoscopy revealing multiple outpouchings of the colonic mucosa, consistent with **colonic diverticulosis**. The incidence of diverticulosis increases with age and is seen typically in patients age >60. Risk factors include low-fiber, high-fat diet, obesity, and physical inactivity.

Diverticula tend to form in areas where the intraluminal colon wall lacks structural integrity. Typically, these weak points are located where the **vasa recta** (terminal vessels derived from the superior and inferior mesenteric arteries) penetrate through the smooth muscular layer of the colon. As the diverticula enlarge, the vessels are exposed to chronic injury, leading to thinning of the vascular media. Ultimately, the weakened **vessels can ulcerate and rupture**, leading to intraluminal hemorrhage and **painless hematochezia** that is often self-limited but can occasionally result in hemodynamic instability.

Management includes patient resuscitation (eg, intravenous fluids) and colonoscopy, which can diagnose diverticulosis and may identify and treat the source of any active bleeding; angiography or surgery may be required for persistent bleeding.

(Choice A) Angiodysplasias are abnormal arteriovenous channels that form from ectatic, thin-walled vessels within the gastrointestinal tract.

vessels can ulcerate and rupture, leading to intraluminal hemorrhage and **painless hematochezia** that is often self-limited but can occasionally result in hemodynamic instability.

Management includes patient resuscitation (eg, intravenous fluids) and colonoscopy, which can diagnose diverticulosis and may identify and treat the source of any active bleeding; angiography or surgery may be required for persistent bleeding.

(Choice A) Angiodysplasias are abnormal arteriovenous channels that form from ectatic, thin-walled vessels within the gastrointestinal tract. Although they can also cause painless hematochezia, they are identified on colonoscopy as flat, red lesions with a fern-like or arborized appearance.

(Choice B) Diffuse, continuous mucosal inflammation and erosion extending from the rectum and into the proximal colon are consistent with ulcerative colitis (UC) and typically grossly visible on endoscopy. Although UC also causes hematochezia, it is typically associated with diarrhea, progressive abdominal pain, tenesmus, and fevers.

(Choice C) Hemorrhoids are characterized by dilation and tortuosity of the rectal venous plexuses. These appear as a purplish or bluish bulge at the anorectum and are identified easily on physical examination or during colonoscopy.

(Choice E) Colorectal adenocarcinoma, which arises typically from colonic polyps, can also cause hematochezia due to mucosal sloughing but is usually identified during a colonoscopy as an ulcerated polypoid mass. Patients also often have a history of unexplained weight loss, fatigue, or abnormal stool caliber (eg, pencil-thin stool).

Educational objective:
Colonic diverticula form at weak points in the colon wall, typically in areas where the vasa recta penetrate through the smooth muscle. As diverticula enlarge, the vasa recta are exposed and become vulnerable to chronic injury, which can lead to intraluminal hemorrhage and painless hematochezia.

Pathology	Gastrointestinal & Nutrition	Diverticular disease
Subject	System	Topic

Copyright © UWorld. All rights reserved.

1
2
3
4
5
6
7
8
9
10
11
12
13
14
15
16
17
18
19
20
21
22
23
24
25
26
27
28
29
30

vessels can ulcerate and rupture, leading to intraluminal hemorrhage and **painless hematochezia** that is often self-limited but can occasionally

Exhibit Display

Zoom In | Zoom Out | Reset | Add To Flash Card

1 2 3 4 5 6 7 8 9 10 11 12 13 14 15 16 17 18 19 20 21 22 23 24 25 26 27 28 29 30

vessels can ulcerate and rupture, leading to intraluminal hemorrhage and **painless hematochezia** that is often self-limited but can occasionally

Exhibit Display

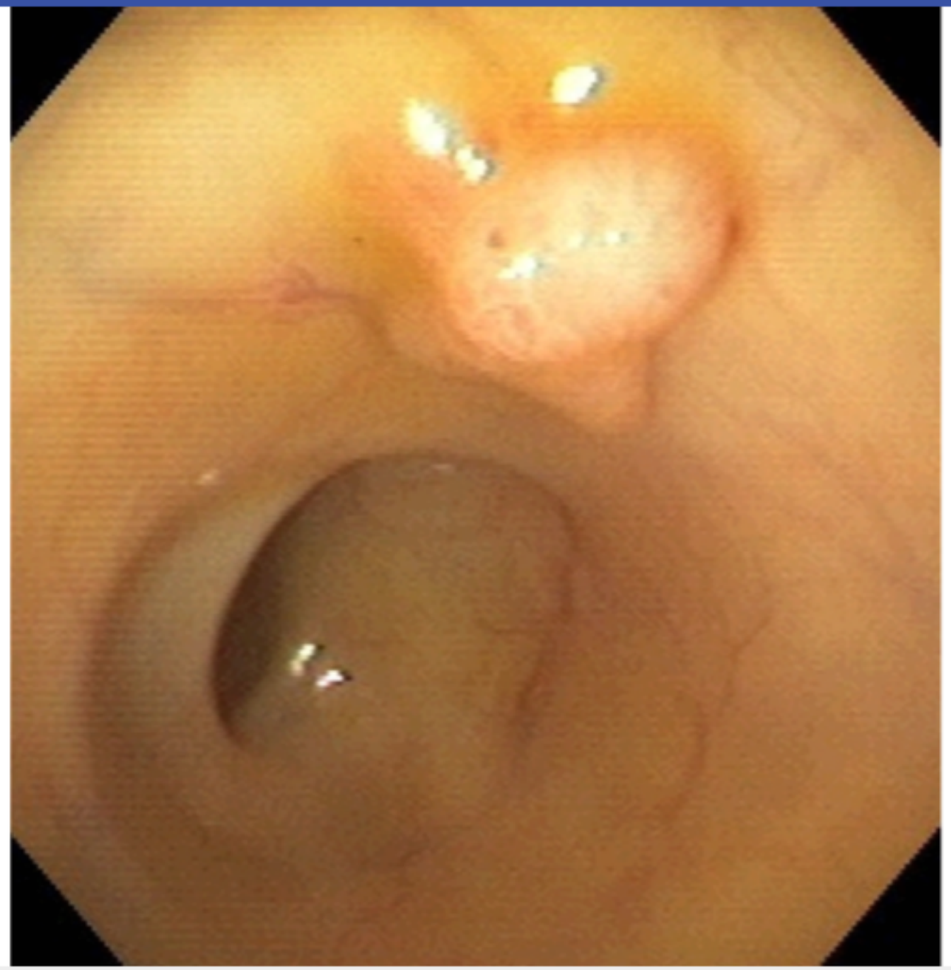

Zoom In | Zoom Out | Reset | Add To Flash Card

A 26-year-old woman is evaluated for intermittent abdominal discomfort, diarrhea, and melena. The patient undergoes colonoscopy followed by total colectomy due to significant colonic abnormalities. Representative colon findings are shown in the image below.

Her sister, who has the same biological parents and has no symptoms, also undergoes screening colonoscopy and has similar findings. If left untreated, which of the following is the most likely lifetime risk of colon cancer in the patient's sister?

- A. About 25%
- B. About 50%

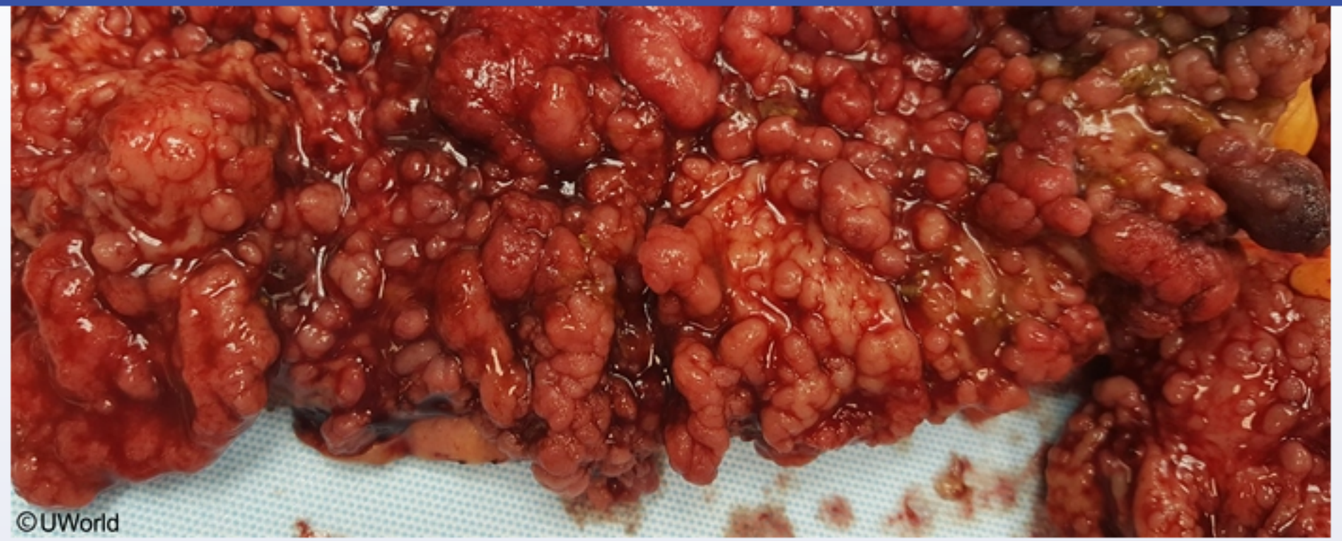

Her sister, who has the same biological parents and has no symptoms, also undergoes screening colonoscopy and has similar findings. If left untreated, which of the following is the most likely lifetime risk of colon cancer in the patient's sister?

- A. About 25%
- B. About 50%
- C. About 75%
- D. Close to 100%
- E. Same as general population

Submit

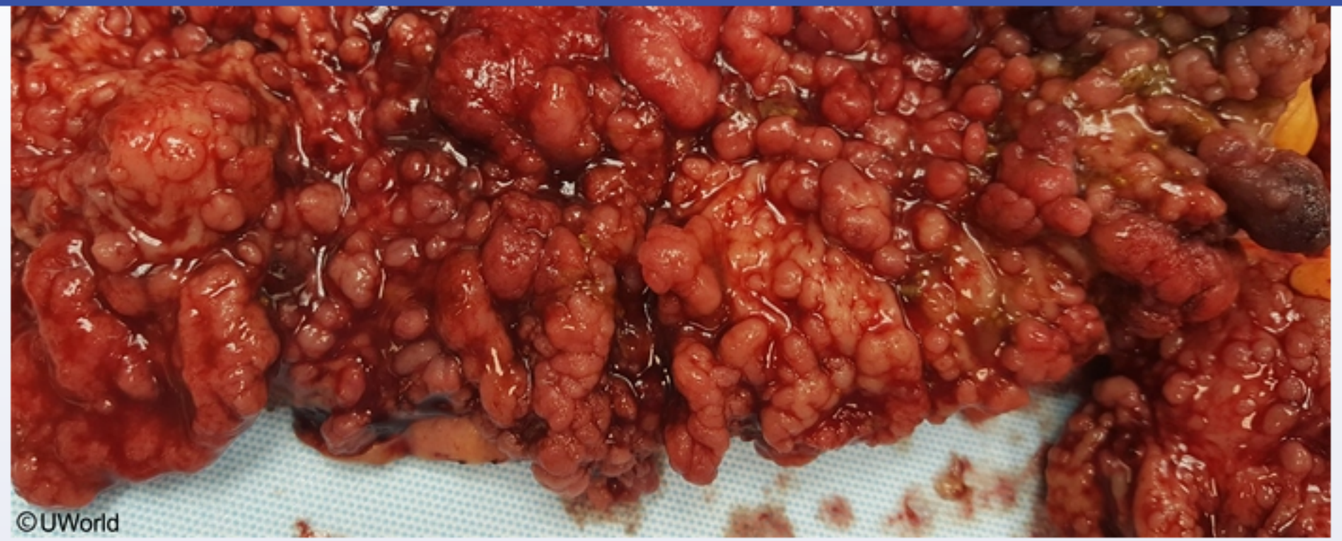

Her sister, who has the same biological parents and has no symptoms, also undergoes screening colonoscopy and has similar findings. If left untreated, which of the following is the most likely lifetime risk of colon cancer in the patient's sister?

- A. About 25% (3%)
- B. About 50% (7%)
- C. About 75% (5%)
- ✓ D. Close to 100% (80%)
- E. Same as general population (3%)

Omitted
Correct answer

80%
Answered correctly

05 secs
Time Spent

04/28/2020
Last Updated

Explanation

Syndromes that increase colon cancer risk			
Syndrome	**Gene mutation**	**Colon cancer risk**	**Other associated neoplasms**
Familial adenomatous polyposis	*APC*	100%	Upper gastrointestinal Thyroid Desmoids/osteomas
Lynch syndrome	*MSH2/6, MLH1*	50%-80%	Endometrial Ovarian
Peutz-Jeghers syndrome	*STK11*	39%	Upper gastrointestinal Pancreatic Breast

This patient and her sister have innumerable colonic polyps, raising strong suspicion for the autosomal dominant hereditary disorder **familial adenomatous polyposis** (FAP). Patients with this disorder develop hundreds or thousands of **colonic polyps** in the second or third decade of life. These polyps behave similarly to colonic polyps that form in patients who do not have FAP (spontaneous polyps): they typically grow over time, do not regress, and are associated with a progressive risk for high-grade dysplasia and transformation to invasive cancer as they enlarge. Because patients with FAP have innumerable polyps, the risk that one or more will transform into invasive **colonic carcinoma is nearly 100%**. Therefore, colectomy is generally recommended.

FAP is caused by a germline mutation to the tumor suppressor gene ***adenomatous polyposis coli*** (*APC*). The *APC* gene encodes for a protein that destroys beta-catenin. Loss of the APC protein results in elevated beta-catenin levels, which stimulates a transcriptional activator that leads to proliferation of intestinal crypt cells (and the subsequent formation of polyps). Patients may also have extracolonic manifestations such as gastric or duodenal polyps, desmoid tumors, and brain cancer, but these manifestations have lower penetrance than colonic polyps.

			Breast

This patient and her sister have innumerable colonic polyps, raising strong suspicion for the autosomal dominant hereditary disorder **familial adenomatous polyposis** (FAP). Patients with this disorder develop hundreds or thousands of **colonic polyps** in the second or third decade of life. These polyps behave similarly to colonic polyps that form in patients who do not have FAP (spontaneous polyps): they typically grow over time, do not regress, and are associated with a progressive risk for high-grade dysplasia and transformation to invasive cancer as they enlarge. Because patients with FAP have innumerable polyps, the risk that one or more will transform into invasive **colonic carcinoma is nearly 100%**. Therefore, colectomy is generally recommended.

FAP is caused by a germline mutation to the tumor suppressor gene ***adenomatous polyposis coli*** (*APC*). The *APC* gene encodes for a protein that destroys beta-catenin. Loss of the APC protein results in elevated beta-catenin levels, which stimulates a transcriptional activator that leads to proliferation of intestinal crypt cells (and the subsequent formation of polyps). Patients may also have extracolonic manifestations such as gastric or duodenal polyps, desmoid tumors, and brain cancer, but these manifestations have lower penetrance than colonic polyps.

Loss of control of the APC pathway is a crucial first step in the development of both hereditary and sporadic forms of colon cancer. Nearly 80% of sporadic colon cancers have somatic mutations to both *APC* alleles; the remainder usually have activating mutations to the downstream products of this pathway.

Educational objective:
Familial adenomatous polyposis (FAP) is an autosomal dominant disorder caused by germline mutation to the tumor suppressor gene *adenomatous polyposis coli*. Patients with FAP develop hundred or thousands of colonic polyps; lifetime risk of colon cancer is close to 100%.

References

- Hereditary and familial colon cancer.

Pathology	Gastrointestinal & Nutrition	Colorectal cancer
Subject	System	Topic

Copyright © UWorld. All rights reserved.

A 59-year-old woman comes to the office due to fatigue and generalized itching that have developed slowly over the last year. She has not had a visible rash. The patient is reluctant to seek health care and has not seen a physician in years. She does not use tobacco, alcohol, or illicit drugs. Vital signs are normal. Examination shows mild hepatomegaly. Laboratory studies show a striking increase in serum alkaline phosphatase, with moderate elevations in bilirubin and hepatic transaminases. Liver biopsy reveals dilated bile canaliculi with green-brown plugs and yellowish-green accumulations of pigment within the hepatic parenchyma. The patient does not return for her scheduled follow-up appointment to discuss further management. This patient is at risk for developing which of the following complications?

- A. Cardiac dilation
- B. Choreoathetosis
- C. Fat-soluble vitamin deficiency
- D. Gastric atrophy
- E. Macrocytic anemia
- F. Seborrheic dermatitis

Submit

A 59-year-old woman comes to the office due to fatigue and generalized itching that have developed slowly over the last year. She has not had a visible rash. The patient is reluctant to seek health care and has not seen a physician in years. She does not use tobacco, alcohol, or illicit drugs. Vital signs are normal. Examination shows mild hepatomegaly. Laboratory studies show a striking increase in serum alkaline phosphatase, with moderate elevations in bilirubin and hepatic transaminases. Liver biopsy reveals dilated bile canaliculi with green-brown plugs and yellowish-green accumulations of pigment within the hepatic parenchyma. The patient does not return for her scheduled follow-up appointment to discuss further management. This patient is at risk for developing which of the following complications?

- A. Cardiac dilation (3%)
- B. Choreoathetosis (8%)
- ✓ C. Fat-soluble vitamin deficiency (81%)
- D. Gastric atrophy (1%)
- E. Macrocytic anemia (3%)
- F. Seborrheic dermatitis (2%)

Omitted
Correct answer
C

81%
Answered correctly

03 secs
Time Spent

02/04/2020
Last Updated

Explanation

Causes of cholestasis

Causes of cholestasis	
Intrahepatic	• Drug-induced (eg, erythromycin, contraceptives) • Primary biliary cholangitis • Cholestasis of pregnancy • Primary sclerosing cholangitis (may also be extrahepatic)
Extrahepatic	• Choledocholithiasis • Malignancy (eg, pancreatic, gallbladder)

©UWorld

This patient has fatigue, pruritus, hepatomegaly, and an elevated alkaline phosphatase level suggesting cholestatic liver disease. **Cholestasis** can arise secondary to hepatocellular dysfunction or intrahepatic or extrahepatic biliary obstruction. Both obstructive and nonobstructive cholestasis are characterized by the deposition of bile pigment within the hepatic parenchyma, often with green-brown plugs in the dilated bile canaliculi. When it is prolonged, the reduction in bile flow causes intestinal **malabsorption** of fats and **fat-soluble vitamins** (A, D, E, and K), which require bile salts for digestion.

(Choice A) Cardiac dilation can result from deficiency of thiamine (vitamin B_1), a water-soluble vitamin. Deficiency is common in alcoholics but not in patients with cholestatic liver disease.

(Choice B) Wilson disease is an autosomal recessive disorder characterized by abnormal biliary handling of copper. Liver disease with eventual cirrhosis is common. Central nervous system involvement can cause dysarthria, ataxia, and movement disorders including chorea and athetosis. Hepatocellular markers (eg, transaminases) will be elevated more prominently than cholestatic markers.

(Choices D and E) Atrophic gastritis can be due to autoimmune causes (pernicious anemia), *Helicobacter pylori* infection, radiation, or

©UWorld

This patient has fatigue, pruritus, hepatomegaly, and an elevated alkaline phosphatase level suggesting cholestatic liver disease. **Cholestasis** can arise secondary to hepatocellular dysfunction or intrahepatic or extrahepatic biliary obstruction. Both obstructive and nonobstructive cholestasis are characterized by the deposition of bile pigment within the hepatic parenchyma, often with green-brown plugs in the dilated bile canaliculi. When it is prolonged, the reduction in bile flow causes intestinal **malabsorption** of fats and **fat-soluble vitamins** (A, D, E, and K), which require bile salts for digestion.

(Choice A) Cardiac dilation can result from deficiency of thiamine (vitamin B_1), a water-soluble vitamin. Deficiency is common in alcoholics but not in patients with cholestatic liver disease.

(Choice B) Wilson disease is an autosomal recessive disorder characterized by abnormal biliary handling of copper. Liver disease with eventual cirrhosis is common. Central nervous system involvement can cause dysarthria, ataxia, and movement disorders including chorea and athetosis. Hepatocellular markers (eg, transaminases) will be elevated more prominently than cholestatic markers.

(Choices D and E) Atrophic gastritis can be due to autoimmune causes (pernicious anemia), *Helicobacter pylori* infection, radiation, or granulomatous conditions. Loss of intrinsic factor production by parietal cells can lead to deficiency of vitamin B_{12} with resulting macrocytic anemia.

(Choice F) Seborrheic dermatitis is a common inflammatory condition characterized by accumulation of scaly, greasy skin on the scalp, face, ears, eyelids, and eyebrows. Severe or widespread seborrhea is seen in HIV infection and Parkinson disease, but it is not associated with cholestatic liver disease.

Educational objective:
Cholestatic liver disease can cause malabsorption and nutritional deficiencies of fat-soluble vitamins.

Pathology	Gastrointestinal & Nutrition	Cholestasis
Subject	System	Topic

Copyright © UWorld. All rights reserved.

Settings

1
2
3
4
5
6
7
8
9
10
11
12
13
14
15
16
17
18
19
20
21
22
23
24
25
26
27
28
29
30

Item 25 of 40
Question Id: 364

Mark | Previous | Next | Full Screen | Tutorial | Lab Values | Notes | Calculator | Reverse Color | Text Zoom | Settings

©UWorld

Exhibit Display

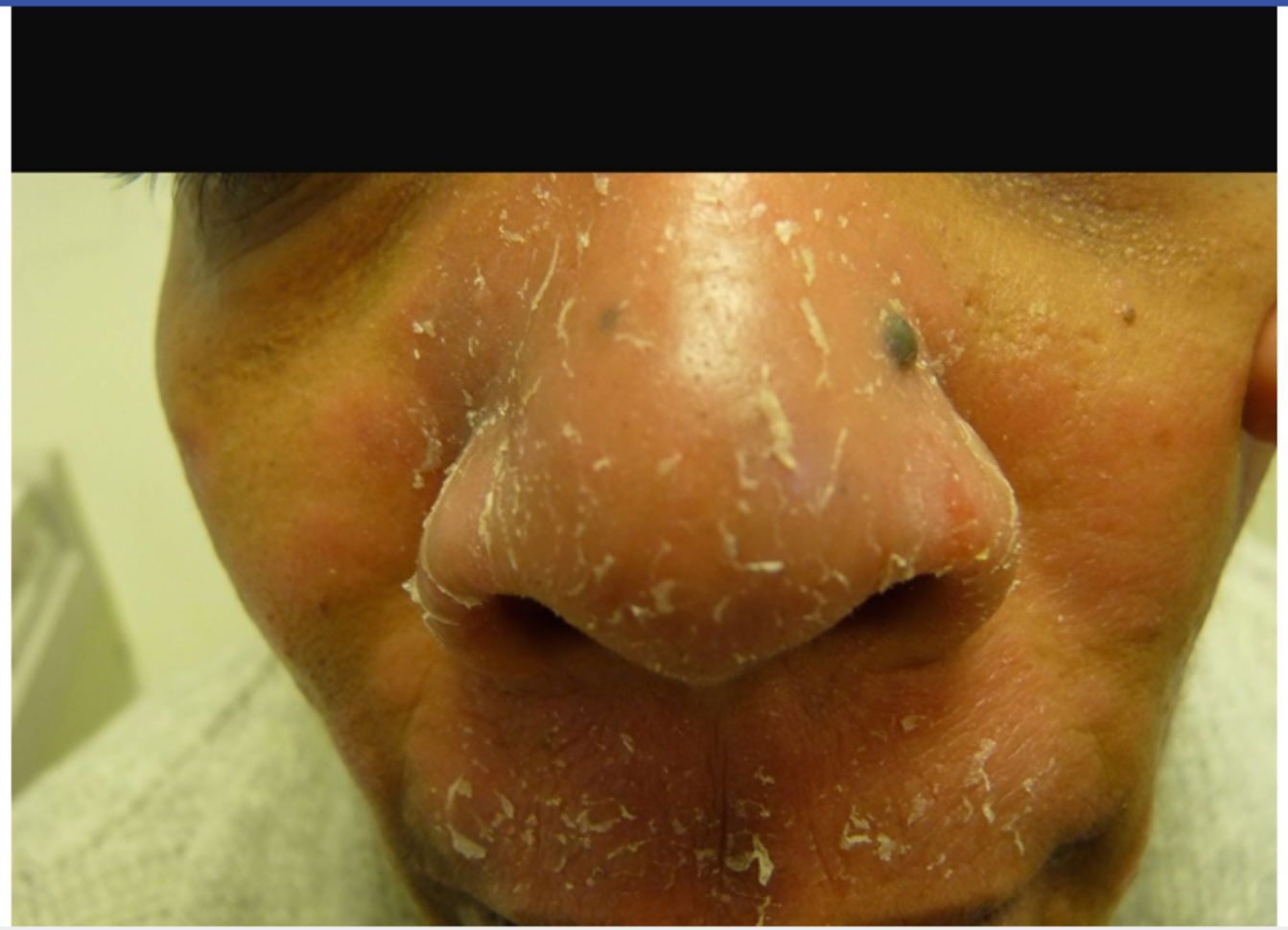

Zoom In | Zoom Out | Reset | Add To New Card | Existing Card

Block Time Remaining: 00:01:01
TUTOR

4 | Feedback | Suspend | End Block

A 33-year-old woman with a 9-year history of ulcerative colitis comes to the office due to concern about her risk of colon cancer. One of her close family friends died recently from this cancer. The patient wants to "undergo all the tests for colon cancer." She has no other comorbid conditions and is under the care of a gastroenterologist who has kept her disease well controlled with sulfasalazine. Compared with sporadic colorectal carcinoma, colorectal malignancy arising in this patient would more likely exhibit which of the following features?

- A. Early *APC* gene mutation
- B. Low-grade histology
- C. Multifocal origin
- D. Origin from an adenomatous polyp

Submit

A 33-year-old woman with a 9-year history of ulcerative colitis comes to the office due to concern about her risk of colon cancer. One of her close family friends died recently from this cancer. The patient wants to "undergo all the tests for colon cancer." She has no other comorbid conditions and is under the care of a gastroenterologist who has kept her disease well controlled with sulfasalazine. Compared with sporadic colorectal carcinoma, colorectal malignancy arising in this patient would more likely exhibit which of the following features?

- A. Early *APC* gene mutation (24%)
- B. Low-grade histology (14%)
- ✓ C. Multifocal origin (48%)
- D. Origin from an adenomatous polyp (12%)

Omitted
Correct answer
C

48%
Answered correctly

02 secs
Time Spent

03/16/2020
Last Updated

Explanation

Colitis-associated vs sporadic colorectal cancer

	Colitis-associated	Sporadic
Age	• Younger (age 40-55)	• Older (age >60)
Origin of dysplasia	• Flat (nonpolypoid) lesions	• Polypoid lesions

Colitis-associated vs sporadic colorectal cancer

	Colitis-associated	Sporadic
Age	• Younger (age 40-55)	• Older (age >60)
Origin of dysplasia	• Flat (nonpolypoid) lesions	• Polypoid lesions
Location	• Proximal > distal (particularly with CD)	• Distal > proximal
Tumors	• Multifocal	• Singular
Histology	• Mucinous and/or signet ring cells • Poorly differentiated	• Rarely mucinous • Well differentiated
Mutations	• Early *p53* mutation • Late *APC* gene mutation	• Early *APC* gene mutation • Late *p53* mutation

APC = adenomatous polyposis coli; CD = Crohn disease.

Inflammatory bowel disease (IBD) is associated with a significant risk for colorectal carcinoma (CRC); up to 30% of patients with IBD develop CRC in their lifetime. Patients with ulcerative colitis, particularly pancolitis, are at highest risk. **Colitis-associated colorectal cancer** (CA-CRC) occurs in areas of chronic inflammation, and the risk is proportionate to the duration and severity of inflammation.

(Choices A, B, and D) Unlike sporadic CRC, which typically progresses slowly from a singular dysplastic polyp, CA-CRC is typically more **aggressive**, often evolves from flat (**nonpolypoid**) lesions, and is frequently **multifocal** (ie, multiple synchronous carcinomas) at diagnosis. CA-CRC often affects a **younger** population than sporadic CRC. These malignancies are more likely to have a **higher histopathologic grade**, with poorly differentiated or anaplastic cells and a high number of mucinous or signet ring cells. The molecular pathogenesis of CA-CRC is also different than that of sporadic disease, with *p53* mutations occurring early in the course of malignant development and *APC* mutations occurring much later.

APC = adenomatous polyposis coli; CD = Crohn disease.

Inflammatory bowel disease (IBD) is associated with a significant risk for colorectal carcinoma (CRC); up to 30% of patients with IBD develop CRC in their lifetime. Patients with ulcerative colitis, particularly pancolitis, are at highest risk. **Colitis-associated colorectal cancer** (CA-CRC) occurs in areas of chronic inflammation, and the risk is proportionate to the duration and severity of inflammation.

(Choices A, B, and D) Unlike sporadic CRC, which typically progresses slowly from a singular dysplastic polyp, CA-CRC is typically more **aggressive**, often evolves from flat (**nonpolypoid**) lesions, and is frequently **multifocal** (ie, multiple synchronous carcinomas) at diagnosis. CA-CRC often affects a **younger** population than sporadic CRC. These malignancies are more likely to have a **higher histopathologic grade**, with poorly differentiated or anaplastic cells and a high number of mucinous or signet ring cells. The molecular pathogenesis of CA-CRC is also different than that of sporadic disease, with *p53* mutations occurring early in the course of malignant development and *APC* mutations occurring much later.

Given the high risk for CRC and the difficulty of colonoscopic visualization of flat or multifocal lesions, it is important to regularly monitor IBD via colonoscopy with random biopsies.

Educational objective:
Inflammatory bowel disease, especially ulcerative pancolitis, is associated with a significant risk for colorectal carcinoma. Compared with sporadic colorectal cancer, colitis-associated colorectal cancer is more likely to occur at a younger age, is typically more aggressive with a higher histopathologic grade, often evolves from flat (nonpolypoid) lesions, and is frequently multifocal. Patients should be monitored regularly via colonoscopy with random biopsies.

References

- Current management of inflammatory bowel disease and colorectal cancer.

Pathology	Gastrointestinal & Nutrition	Colorectal cancer
Subject	System	Topic

Copyright © UWorld. All rights reserved.

1 2 3 4 5 6 7 8 9 10 11 12 13 14 15 16 17 18 19 20 21 22 23 24 25 26 27 28 29 30

A 73-year-old woman is brought to the clinic by her niece due to a 10-day history of abdominal pain and loss of appetite. The patient does not like "going to the doctor" and has not been seen by a physician in many years. Frequent loose stools and loss of appetite have been present since the pain began. Family history is significant for colon cancer in a maternal aunt. Temperature is 37.8 C (100 F) and pulse is 98/min. Abdominal examination is significant for tenderness on deep palpation of the left lower quadrant, along with an appreciable mass. There is no inguinal lymphadenopathy. White blood cell count is 15,000/mm^3. Which of the following is the most likely cause of the abdominal pain in this patient?

A. Acute diverticulitis

B. Colon cancer

C. Incarcerated direct inguinal hernia

D. Ischemic colitis

E. Tubo-ovarian abscess

F. Ulcerative colitis

Submit

A 73-year-old woman is brought to the clinic by her niece due to a 10-day history of abdominal pain and loss of appetite. The patient does not like "going to the doctor" and has not been seen by a physician in many years. Frequent loose stools and loss of appetite have been present since the pain began. Family history is significant for colon cancer in a maternal aunt. Temperature is 37.8 C (100 F) and pulse is 98/min. Abdominal examination is significant for tenderness on deep palpation of the left lower quadrant, along with an appreciable mass. There is no inguinal lymphadenopathy. White blood cell count is 15,000/mm^3. Which of the following is the most likely cause of the abdominal pain in this patient?

- ✓ A. Acute diverticulitis (66%)
- B. Colon cancer (14%)
- C. Incarcerated direct inguinal hernia (4%)
- D. Ischemic colitis (5%)
- E. Tubo-ovarian abscess (5%)
- F. Ulcerative colitis (2%)

Omitted
Correct answer
A

66%
Answered correctly

02 secs
Time Spent

02/11/2020
Last Updated

Explanation

Acute diverticulitis	
Pathogenesis	• Trapped food particles & ↑ intracolonic pressure that cause microperforation of colonic diverticula

Acute diverticulitis	
Pathogenesis	• Trapped food particles & ↑ intracolonic pressure that cause microperforation of colonic diverticula
Clinical presentation	• Abdominal pain (usually left lower quadrant) • Nausea, vomiting, change in bowel habits • Tenderness ± palpable mass • Leukocytosis
Diagnosis	• Abdominal CT scan (oral & intravenous contrast)

This patient with abdominal pain, leukocytosis, low-grade fever, and a mass palpated in the left lower quadrant likely has acute diverticulitis. Diverticulitis is characterized by inflammation of colonic diverticula (ie, herniated outpouchings of the colonic mucosa and submucosa through the muscularis mucosae) and is caused by trapped food particles and elevated intraluminal pressure within a diverticulum, resulting in microperforation. The risk increases with age (particularly in those age ≥60).

Patients commonly present with constant **abdominal pain**, classically in the **left lower quadrant**, signifying sigmoid colon involvement. Other symptoms include nausea, vomiting, and changes in bowel habits (constipation or diarrhea). Patients often have low-grade **fever**, and examination may reveal **lower abdominal tenderness** and, often, a **palpable mass** due to inflammation or abscess formation. Mild leukocytosis is a common laboratory finding; occult blood may be present, but gross hematochezia is rare.

(Choice B) Colon cancer may present with abdominal pain. However, a tumor large enough to palpate on examination suggests extensive disease and would typically be associated with more chronic symptoms (eg, weight loss). The leukocytosis and short duration of symptoms in this patient are more consistent with diverticulitis.

(Choice C) Incarcerated direct inguinal hernias cause a palpable mass; however, the mass would typically be in the groin, not the abdomen. In addition, unless the hernia is strangulated, leukocytosis and fevers are unexpected.

(Choice D) Ischemic colitis is a common cause of abdominal pain in an older patient; however, it typically presents with hematochezia and

microperforation. The risk increases with age (particularly in those age ≥60).

Patients commonly present with constant **abdominal pain**, classically in the **left lower quadrant**, signifying sigmoid colon involvement. Other symptoms include nausea, vomiting, and changes in bowel habits (constipation or diarrhea). Patients often have low-grade **fever**, and examination may reveal **lower abdominal tenderness** and, often, a **palpable mass** due to inflammation or abscess formation. Mild leukocytosis is a common laboratory finding; occult blood may be present, but gross hematochezia is rare.

(Choice B) Colon cancer may present with abdominal pain. However, a tumor large enough to palpate on examination suggests extensive disease and would typically be associated with more chronic symptoms (eg, weight loss). The leukocytosis and short duration of symptoms in this patient are more consistent with diverticulitis.

(Choice C) Incarcerated direct inguinal hernias cause a palpable mass; however, the mass would typically be in the groin, not the abdomen. In addition, unless the hernia is strangulated, leukocytosis and fevers are unexpected.

(Choice D) Ischemic colitis is a common cause of abdominal pain in an older patient; however, it typically presents with hematochezia and postprandial pain in patients with ischemic risk factors (eg, hypertension, diabetes).

(Choice E) Tubo-ovarian abscess can cause abdominal pain and leukocytosis; however, patients typically have vaginal discharge, and a mass (if present) is located in the pelvis, not the abdomen. Tubo-ovarian abscesses typically occur in the setting of pelvic inflammatory disease, which is far more common in patients age <40.

(Choice F) Ulcerative colitis often presents with abdominal pain and diarrhea; however, hematochezia is common. In addition, patients are typically diagnosed at age 20-40.

Educational objective:
Diverticulitis is characterized by inflammation of colonic diverticula. Patients have abdominal pain, nausea, vomiting, and changes in bowel habits. Low-grade fever and leukocytosis are common, and physical examination may demonstrate a tender mass in the left lower quadrant.

References

- Diagnosis and management of acute diverticulitis.

1 2 3 4 5 6 7 8 9 10 11 12 13 14 15 16 17 18 19 20 21 22 23 24 25 26 27 28 29 30

A 38-year-old man is evaluated for bloody stools, weight loss, and anemia. The patient's past medical history is unremarkable, and he does not take any medications. He uses tobacco and drinks alcohol "socially." The patient's father died of colon cancer at age 40. His younger sister suffers from endometrial cancer. Examination is remarkable for minimal right-sided abdominal tenderness without guarding to deep palpation. Stool is positive for occult blood. Colonoscopy shows a right-sided ulcerative colon mass. No polyps are noted. Biopsy of the mass reveals adenocarcinoma. A mutation in which of the following genes is most likely responsible for this patient's condition?

A. *APC*

B. *BRCA1*

C. *MEN1*

D. *MSH2*

E. *VHL*

Submit

A 38-year-old man is evaluated for bloody stools, weight loss, and anemia. The patient's past medical history is unremarkable, and he does not take any medications. He uses tobacco and drinks alcohol "socially." The patient's father died of colon cancer at age 40. His younger sister suffers from endometrial cancer. Examination is remarkable for minimal right-sided abdominal tenderness without guarding to deep palpation. Stool is positive for occult blood. Colonoscopy shows a right-sided ulcerative colon mass. No polyps are noted. Biopsy of the mass reveals adenocarcinoma. A mutation in which of the following genes is most likely responsible for this patient's condition?

- A. *APC* (41%)
- B. *BRCA1* (5%)
- C. *MEN1* (1%)
- ✓ D. *MSH2* (47%)
- E. *VHL* (4%)

Omitted
Correct answer
D

47%
Answered correctly

02 secs
Time Spent

01/27/2020
Last Updated

Explanation

Common hereditary cancer syndromes			
Syndrome	**Gene**	**Associated neoplasms**	**Pathogenesis**

Common hereditary cancer syndromes

Syndrome	Gene	Associated neoplasms	Pathogenesis
Lynch syndrome	*MSH2, MLH1, MSH6, PMS2*	• Colorectal cancer • Endometrial cancer • Ovarian cancer	• **Autosomal dominant** • Caused by **inactivating** mutation in corresponding **tumor suppressor gene** • Deletion of remaining normal allele (**second hit**) leads to loss of heterozygosity & **malignant transformation**
Familial adenomatous polyposis	*APC*	• Colorectal cancer • Desmoids & osteomas • Brain tumors	
von Hippel-Lindau syndrome	*VHL*	• Hemangioblastomas • Clear cell renal carcinoma • Pheochromocytoma	
Li-Fraumeni syndrome	*TP53*	• Sarcomas • Breast cancer • Brain tumors • Adrenocortical carcinoma • Leukemia	
Multiple endocrine neoplasia type 1	*MEN1*	• Parathyroid adenomas • Pituitary adenomas • Pancreatic	

1
2
3
4
5
6
7
8
9
10
11
12
13
14
15
16
17
18
19
20
21
22
23
24
25
26
27
28
29
30

Li-Fraumeni syndrome	*TP53*	• Sarcomas • Breast cancer • Brain tumors • Adrenocortical carcinoma • Leukemia	• Deletion of remaining normal allele (**second hit**) leads to loss of heterozygosity & **malignant transformation**
Multiple endocrine neoplasia type 1	*MEN1*	• Parathyroid adenomas • Pituitary adenomas • Pancreatic adenomas	
Multiple endocrine neoplasia type 2	*RET*	• Medullary thyroid cancer • Pheochromocytoma • Parathyroid hyperplasia (*MEN2A*)	• **Autosomal dominant** • **Activating** (gain-of-function) mutation in proto-oncogene • **Continuous stimulation** of cell division predisposes to tumor growth

This case is typical of **hereditary nonpolyposis colon cancer** (HNPCC), or Lynch syndrome, an **autosomal dominant** genetic predisposition to colon cancer. In patients with HNPCC, **colon cancer** occurs at a young age (**age <50**). **Family history** reveals a high incidence of **colon** cancer and, occasionally, **extraintestinal** (eg, endometrial) cancers in first-degree relatives.

With HNPCC, there is an inherited mutation in one of the genes responsible for **DNA mismatch repair** (eg, *MSH2, MLH1*). The products of these genes proofread DNA during replication. Patients with HNPCC inherit a mutation in an allele, and mutation of the second allele occurs during adult life. When 2 dysfunctional copies are present, malignancies will develop readily.

(Choice A) The *APC* gene is responsible for intercellular attachment. Its mutation leads to the formation of adenomatous polyps from normal mucosa. *APC* mutation is detected in most sporadic colon cancers and in all familial polyposis syndromes but not in HNPCC.

neoplasia type 2	*RET*	• Parathyroid hyperplasia (*MEN2A*)	• **Continuous stimulation** of cell division predisposes to tumor growth

This case is typical of **hereditary nonpolyposis colon cancer** (HNPCC), or Lynch syndrome, an **autosomal dominant** genetic predisposition to colon cancer. In patients with HNPCC, **colon cancer** occurs at a young age (**age <50**). **Family history** reveals a high incidence of **colon** cancer and, occasionally, **extraintestinal** (eg, endometrial) cancers in first-degree relatives.

With HNPCC, there is an inherited mutation in one of the genes responsible for **DNA mismatch repair** (eg, *MSH2, MLH1*). The products of these genes proofread DNA during replication. Patients with HNPCC inherit a mutation in an allele, and mutation of the second allele occurs during adult life. When 2 dysfunctional copies are present, malignancies will develop readily.

(Choice A) The *APC* gene is responsible for intercellular attachment. Its mutation leads to the formation of adenomatous polyps from normal mucosa. *APC* mutation is detected in most sporadic colon cancers and in all familial polyposis syndromes but not in HNPCC.

(Choice B) Mutations in the tumor suppressor gene *BRCA* are classically associated with breast and ovarian cancers.

(Choice C) *MEN1* mutations are associated with multiple endocrine neoplasia type 1 syndrome (parathyroid, pituitary, and pancreatic adenomas).

(Choice E) Mutations in the tumor suppressor gene *VHL* are classically associated with von Hippel-Lindau syndrome (hemangioblastoma, clear cell renal carcinoma, pheochromocytoma).

Educational objective:
Hereditary nonpolyposis colon cancer (HNPCC), or Lynch syndrome, leads to occurrence of colonic adenocarcinomas at a young age (age <50) along with a predisposition for extraintestinal malignancies. Mutations of DNA mismatch repair genes are responsible for HNPCC.

Pathology	Gastrointestinal & Nutrition	Lynch syndrome
Subject	System	Topic

Copyright © UWorld. All rights reserved.

A 45-year-old man comes to the emergency department due to sudden-onset vomiting and severe upper abdominal pain that radiates to his back. The patient's total bilirubin is 0.9 mg/dL, aspartate aminotransferase (AST) is 98 U/L, alanine aminotransferase (ALT) is 32 U/L, and alkaline phosphatase is 98 U/L. Serum lipase is markedly increased. Abdominal ultrasound reveals a normal gallbladder and common bile duct. The diagnosis of acute pancreatitis is made, and a specific etiology is established. Which of the following additional laboratory findings is most specific for the underlying cause of this patient's pancreatitis?

A. Mean corpuscular volume of 108 fL

B. Serum calcium level of 8 mg/dL

C. Serum glucose level of 180 mg/dL

D. Serum sodium level of 150 mEq/L

E. White blood cell count of 22,000/mm ^{3}

Submit

A 45-year-old man comes to the emergency department due to sudden-onset vomiting and severe upper abdominal pain that radiates to his back. The patient's total bilirubin is 0.9 mg/dL, aspartate aminotransferase (AST) is 98 U/L, alanine aminotransferase (ALT) is 32 U/L, and alkaline phosphatase is 98 U/L. Serum lipase is markedly increased. Abdominal ultrasound reveals a normal gallbladder and common bile duct. The diagnosis of acute pancreatitis is made, and a specific etiology is established. Which of the following additional laboratory findings is most specific for the underlying cause of this patient's pancreatitis?

- ✓ A. Mean corpuscular volume of 108 fL (34%)
- B. Serum calcium level of 8 mg/dL (24%)
- C. Serum glucose level of 180 mg/dL (16%)
- D. Serum sodium level of 150 mEq/L (3%)
- E. White blood cell count of 22,000/mm ^{3} (20%)

Omitted
Correct answer
A

34%
Answered correctly

02 secs
Time Spent

06/01/2020
Last Updated

Explanation

This patient's **acute pancreatitis** is likely related to **alcohol abuse** given his **>2 AST:ALT ratio** and **absence of gallstones** on abdominal ultrasound. After gallstones, alcohol abuse is the second most common cause of acute pancreatitis. Ethanol induces pancreatic secretions with a high protein concentration and low fluid content. These viscous secretions are prone to precipitate and form plugs that can obstruct the lumina of the pancreatic ductules. Alcohol also causes spasms of the sphincter of Oddi and has a direct toxic effect on the acinar cells.

Explanation

This patient's **acute pancreatitis** is likely related to **alcohol abuse** given his **>2 AST:ALT ratio** and **absence of gallstones** on abdominal ultrasound. After gallstones, alcohol abuse is the second most common cause of acute pancreatitis. Ethanol induces pancreatic secretions with a high protein concentration and low fluid content. These viscous secretions are prone to precipitate and form plugs that can obstruct the lumina of the pancreatic ductules. Alcohol also causes spasms of the sphincter of Oddi and has a direct toxic effect on the acinar cells.

Alcohol-related acute pancreatitis is clinically **indistinguishable** from pancreatitis due to other causes. However, chronic alcohol use causes a number of systemic effects due to both the direct toxic actions of ethanol and alcoholism-associated vitamin deficiencies. Even in the absence of anemia, **macrocytosis** (mean corpuscular volume >100 fL) is often seen and is likely related to poor nutrition (eg, folate deficiency), liver disease, and/or direct toxicity of alcohol on the marrow.

(Choice B) In severe acute pancreatitis, necrosis can spread into the retroperitoneal fat, omentum, mesentery, and even beyond the abdominal cavity. Large amounts of calcium bind to the released free fatty acids, forming soaps that are deposited in the areas of necrosis, which may result in hypocalcemia. However, this is a nonspecific finding that can occur with pancreatitis of any etiology, not just alcoholic pancreatitis.

(Choice C) Inflammation in acute pancreatitis may lead to dysfunction of the pancreatic islets with decreased secretion of insulin, resulting in hyperglycemia. This is a nonspecific finding that can occur with pancreatitis of any etiology, not just alcoholic pancreatitis.

(Choice D) Hypernatremia may occur in the setting of severe acute pancreatitis due to large third-space fluid loss (ie, interstitial fluid accumulation) and decreased water intake, causing subsequent hypovolemia and renal sodium retention. This finding is also not specific for alcoholic pancreatitis.

(Choice E) An increased white blood cell count is a nonspecific marker of inflammation and may occur with pancreatitis of any etiology.

Educational objective:
After gallstones, alcohol abuse is the second most common cause of acute pancreatitis. Macrocytosis and an AST:ALT ratio >2 are indirect indicators of chronic alcohol consumption. Alcohol-related macrocytosis can occur independently of folate deficiency.

References

- Pathophysiology of alcoholic pancreatitis: an overview.

anemia, **macrocytosis** (mean corpuscular volume >100 fL) is often seen and is likely related to poor nutrition (eg, folate deficiency), liver disease, and/or direct toxicity of alcohol on the marrow.

(Choice B) In severe acute pancreatitis, necrosis can spread into the retroperitoneal fat, omentum, mesentery, and even beyond the abdominal cavity. Large amounts of calcium bind to the released free fatty acids, forming soaps that are deposited in the areas of necrosis, which may result in hypocalcemia. However, this is a nonspecific finding that can occur with pancreatitis of any etiology, not just alcoholic pancreatitis.

(Choice C) Inflammation in acute pancreatitis may lead to dysfunction of the pancreatic islets with decreased secretion of insulin, resulting in hyperglycemia. This is a nonspecific finding that can occur with pancreatitis of any etiology, not just alcoholic pancreatitis.

(Choice D) Hypernatremia may occur in the setting of severe acute pancreatitis due to large third-space fluid loss (ie, interstitial fluid accumulation) and decreased water intake, causing subsequent hypovolemia and renal sodium retention. This finding is also not specific for alcoholic pancreatitis.

(Choice E) An increased white blood cell count is a nonspecific marker of inflammation and may occur with pancreatitis of any etiology.

Educational objective:
After gallstones, alcohol abuse is the second most common cause of acute pancreatitis. Macrocytosis and an AST:ALT ratio >2 are indirect indicators of chronic alcohol consumption. Alcohol-related macrocytosis can occur independently of folate deficiency.

References

- Pathophysiology of alcoholic pancreatitis: an overview.
- Diagnosis of alcoholic liver disease.
- Traditional markers of excessive alcohol use.

Pathology	Gastrointestinal & Nutrition	Acute pancreatitis
Subject	System	Topic

Copyright © UWorld. All rights reserved.

A 5-year-old boy is brought to the emergency department due to diarrhea and a low-grade fever. He attends a day care center where other children developed similar symptoms. The boy has no known medical problems. He is up to date with age-appropriate vaccinations. He has not traveled abroad. Physical examination shows abdominal tenderness on deep palpation but no rigidity. Stool is sent for culture, and the patient is diagnosed with *Shigella sonnei* infection. The outbreak is reported to public health authorities and is traced to consumption of a potato salad handled by a food worker who recently had a mild diarrheal illness. Which of the following cells are primarily responsible for uptake of the bacteria that initiated the infection in this boy?

- A. Endothelial cells
- B. Enteroendocrine cells
- C. Goblet cells
- D. Microfold (M) cells
- E. Paneth cells
- F. Polymorphonuclear cells

Submit

A 5-year-old boy is brought to the emergency department due to diarrhea and a low-grade fever. He attends a day care center where other children developed similar symptoms. The boy has no known medical problems. He is up to date with age-appropriate vaccinations. He has not traveled abroad. Physical examination shows abdominal tenderness on deep palpation but no rigidity. Stool is sent for culture, and the patient is diagnosed with *Shigella sonnei* infection. The outbreak is reported to public health authorities and is traced to consumption of a potato salad handled by a food worker who recently had a mild diarrheal illness. Which of the following cells are primarily responsible for uptake of the bacteria that initiated the infection in this boy?

- A. Endothelial cells (11%)
- B. Enteroendocrine cells (4%)
- C. Goblet cells (3%)
- ✓ D. Microfold (M) cells (65%)
- E. Paneth cells (7%)
- F. Polymorphonuclear cells (6%)

Omitted
Correct answer
D

65%
Answered correctly

02 secs
Time Spent

01/27/2020
Last Updated

Explanation

Shigellosis is an infectious form of hemorrhagic diarrhea that can be caused by a variety of *Shigella* species (*S dysenteriae, S flexneri, S boydii, S sonnei*); shigellosis is most commonly due to *S sonnei* in industrialized nations (80%).

Explanation

Shigellosis is an infectious form of hemorrhagic diarrhea that can be caused by a variety of *Shigella* species (*S dysenteriae, S flexneri, S boydii, S sonnei*); shigellosis is most commonly due to *S sonnei* in industrialized nations (80%).

Shigella cannot bind all intestinal cells. *Shigella* exhibits specificity for the **microfold (M) cells** at the base of mucosal villi within a **Peyer patch** region of the ileal mucosa. M cells sample gut lumen contents and transfer antigens to their basal lamina within endosomes. At the base of the cell, macrophages and lymphocytes ready to mount an immune response await within a special pocket (microfold).

Shigella penetrates the mucous membrane by passing through M cells via **endocytosis**. It subsequently lyses the endosome, multiplies, and spreads laterally into other epithelial cells. This results in denuding and ulceration of the mucosa and subsequent leakage of blood, inflammatory elements, and mucus into the intestinal lumen. Patients pass frequent stools mixed with **blood and mucus**. Stools are frequent and loose due to water absorption inhibition.

(Choice A) Endothelial cells form the innermost lining of blood vessels. The Shiga-like toxin of *Escherichia coli* O157:H7 can cause toxicity to renal endothelial cells, leading to renal insufficiency and uremia.

(Choice B) Enteroendocrine cells in the gastrointestinal tract secrete hormones such as somatostatin and cholecystokinin.

(Choice C) Goblet cells are responsible for mucus secretion into the gut lumen. Mucus release is increased in inflammatory states; stool will have visible mucus in conditions such as inflammatory diarrhea, giardiasis, and Crohn disease.

(Choice E) Paneth cells, which occur in small groups at the base of intestinal crypts, are both phagocytic and secretory, thereby providing first-line immune defense against microorganisms. They secrete lysozyme (an enzyme that dissolves the cell walls of many bacteria) and defensins (polypeptides with antimicrobial properties).

(Choice F) In patients with diarrhea, stool is tested for fecal leukocytes (polymorphonuclear cells) when it is unclear whether the etiology is noninflammatory (enterotoxigenic *E coli*, enteroaggregative *E coli, Vibrio cholerae, Clostridium perfringens, Rotavirus*) or inflammatory (*Shigella*, enterohemorrhagic *E coli*, enteroinvasive *E coli, Clostridium difficile, Campylobacter jejuni*).

Educational objective:

spreads laterally into other epithelial cells. This results in denuding and ulceration of the mucosa and subsequent leakage of blood, inflammatory elements, and mucus into the intestinal lumen. Patients pass frequent stools mixed with **blood and mucus**. Stools are frequent and loose due to water absorption inhibition.

(Choice A) Endothelial cells form the innermost lining of blood vessels. The Shiga-like toxin of *Escherichia coli* O157:H7 can cause toxicity to renal endothelial cells, leading to renal insufficiency and uremia.

(Choice B) Enteroendocrine cells in the gastrointestinal tract secrete hormones such as somatostatin and cholecystokinin.

(Choice C) Goblet cells are responsible for mucus secretion into the gut lumen. Mucus release is increased in inflammatory states; stool will have visible mucus in conditions such as inflammatory diarrhea, giardiasis, and Crohn disease.

(Choice E) Paneth cells, which occur in small groups at the base of intestinal crypts, are both phagocytic and secretory, thereby providing first-line immune defense against microorganisms. They secrete lysozyme (an enzyme that dissolves the cell walls of many bacteria) and defensins (polypeptides with antimicrobial properties).

(Choice F) In patients with diarrhea, stool is tested for fecal leukocytes (polymorphonuclear cells) when it is unclear whether the etiology is noninflammatory (enterotoxigenic *E coli*, enteroaggregative *E coli*, *Vibrio cholerae*, *Clostridium perfringens*, *Rotavirus*) or inflammatory (*Shigella*, enterohemorrhagic *E coli*, enteroinvasive *E coli*, *Clostridium difficile*, *Campylobacter jejuni*).

Educational objective:
Shigellosis is an infectious disease that can be caused by variety of *Shigella* species; *S sonnei* is the most common cause of shigellosis in industrialized nations. *Shigella* invades the gastrointestinal mucosa by gaining access to microfold cells in ileal Peyer patches through endocytosis. *Shigella* subsequently lyses the endosome and spreads laterally into other epithelial cells, causing cell death and ulceration with hemorrhage and diarrhea.

Pathology	Gastrointestinal & Nutrition	Acute diarrhea
Subject	System	Topic

Copyright © UWorld. All rights reserved.

A 42-year-old man comes to the emergency department after a syncopal episode preceded by palpitations and lightheadedness. The patient has no significant medical history and takes no medications. He does not use tobacco, alcohol, or illicit drugs. The patient is a computer programmer and spends most of his time indoors. Vital signs are within normal limits with no orthostatic changes. Heart and lung sounds are normal. The liver span is increased with no tenderness. The skin appears darkly tanned. ECG demonstrates sinus node dysfunction, and echocardiography reveals abnormal diastolic relaxation of the left ventricle. Which of the following is the most likely cause of this patient's condition?

- A. Amyloid deposition
- B. Cortisol deficiency
- C. Granuloma formation
- D. Human leukocyte antigen gene mutation
- E. Iron accumulation
- F. Lysosomal glycogen accumulation

Submit

A 42-year-old man comes to the emergency department after a syncopal episode preceded by palpitations and lightheadedness. The patient has no significant medical history and takes no medications. He does not use tobacco, alcohol, or illicit drugs. The patient is a computer programmer and spends most of his time indoors. Vital signs are within normal limits with no orthostatic changes. Heart and lung sounds are normal. The liver span is increased with no tenderness. The skin appears darkly tanned. ECG demonstrates sinus node dysfunction, and echocardiography reveals abnormal diastolic relaxation of the left ventricle. Which of the following is the most likely cause of this patient's condition?

- A. Amyloid deposition (5%)
- B. Cortisol deficiency (9%)
- C. Granuloma formation (1%)
- D. Human leukocyte antigen gene mutation (3%)
- ✓ E. Iron accumulation (79%)
- F. Lysosomal glycogen accumulation (1%)

Omitted
Correct answer
E

Collecting Statistics

02 secs
Time Spent

07/06/2020
Last Updated

Explanation

Cardiac hemochromatosis	
	• Excess intestinal iron absorption

Cardiac hemochromatosis	
Pathophysiology	• Excess intestinal iron absorption • Deposition of iron (ferritin, hemosiderin, free iron) in myocardium • Oxidative injury to myocytes
Cardiomyopathy	• Early: diastolic left ventricular dysfunction (restrictive pattern) • Later: cardiac remodeling & dilated cardiomyopathy
Conduction system disease	• Sinus node dysfunction (sick sinus syndrome) • Atrial & ventricular arrhythmias • Sudden cardiac death

This patient has syncope associated with diastolic dysfunction, **hepatomegaly**, and skin **hyperpigmentation**. This presentation is suggestive of **hereditary hemochromatosis** (HH), an autosomal recessive disorder characterized by excessive intestinal iron absorption with **accumulation of the excess iron** in parenchymal tissues.

Cardiac manifestations of HH include heart failure and conduction system disease. In early stages, myocardial iron overload is expressed as **diastolic left ventricular (LV) dysfunction** with a restrictive filling pattern. As the disease advances, progressive ventricular remodeling leads to **dilated cardiomyopathy** and reduced LV ejection fraction. Iron deposition can also affect the cardiac conduction system. **Sinus node dysfunction** (ie, sick sinus syndrome) can lead to presyncope or syncope; malignant arrhythmias with sudden cardiac death occasionally occur.

On light microscopy, cardiac hemochromatosis is visible as brown, granular deposits (arrow) in myocytes that stain strongly with Prussian blue. Cardiomyopathy can be the first presenting manifestation of HH, although careful assessment can usually find evidence of iron deposition elsewhere (eg, elevated hepatic transaminases, hepatomegaly). Treatment includes therapeutic phlebotomy to remove excess iron stores, which can lead to regression of cardiomyopathy in some patients.

(Choice A) Amyloidosis is caused by extracellular deposition of misfolded amyloid proteins. Multiorgan involvement (eg, cardiomyopathy, hepatomegaly) is common, but amyloidosis frequently involves the kidney (eg, nephrotic syndrome), nerves (eg, neuropathy), and muscles (eg,

1 2 3 4 5 6 7 8 9 10 11 12 13 14 15 16 17 18 19 20 21 22 23 24 25 26 27 28 29 30

dilated cardiomyopathy and reduced LV ejection fraction. Iron deposition can also affect the cardiac conduction system. **Sinus node dysfunction** (ie, sick sinus syndrome) can lead to presyncope or syncope; malignant arrhythmias with sudden cardiac death occasionally occur.

On light microscopy, cardiac hemochromatosis is visible as brown, granular deposits (arrow) in myocytes that stain strongly with Prussian blue. Cardiomyopathy can be the first presenting manifestation of HH, although careful assessment can usually find evidence of iron deposition elsewhere (eg, elevated hepatic transaminases, hepatomegaly). Treatment includes therapeutic phlebotomy to remove excess iron stores, which can lead to regression of cardiomyopathy in some patients.

(Choice A) Amyloidosis is caused by extracellular deposition of misfolded amyloid proteins. Multiorgan involvement (eg, cardiomyopathy, hepatomegaly) is common, but amyloidosis frequently involves the kidney (eg, nephrotic syndrome), nerves (eg, neuropathy), and muscles (eg, macroglossia). It is not associated with hyperpigmentation.

(Choice B) Primary adrenal insufficiency (ie, cortisol deficiency) can cause hyperpigmentation due to cosecretion of melanocyte-stimulating hormone with ACTH (both derived from proopiomelanocortin). However, hepatomegaly is not seen, and although hypotension is common, sinus node and diastolic dysfunction are not.

(Choice C) Sarcoidosis results from widespread formation of noncaseating granulomas. Cardiac infiltration can cause conduction blockade, and liver involvement may result in hepatomegaly. However, lung symptoms (eg, dyspnea, cough) are more common, and skin manifestations include papules and nodules rather than hyperpigmentation.

(Choice D) HH is associated with mutations in the *HFE* gene; the HFE protein binds to the transferrin receptor and regulates intestinal and hepatic iron uptake. Human leukocyte antigen (HLA) mutations are associated with autoimmune disorders (eg, celiac disease, type 1 diabetes).

(Choice F) Glycogen storage disease type II (ie, Pompe disease) is caused by a deficiency in alpha-glucosidase (acid maltase). It manifests shortly after birth with hypertrophic cardiomyopathy, hepatomegaly, muscle weakness, and failure to thrive. Skin hyperpigmentation is not typical.

Educational objective:
Hereditary hemochromatosis is characterized by excessive intestinal iron absorption with deposition of iron in parenchymal tissues. Cardiac manifestations include diastolic dysfunction (initial), dilated cardiomyopathy (later), and conduction system disease (eg, sinus node dysfunction).

Pathology | Gastrointestinal & Nutrition | Hemochromatosis

1 2 3 4 5 6 7 8 9 10 11 12 13 14 15 16 17 18 19 20 21 22 23 24 25 26 27 28 29 30

dilated cardiomyopathy and reduced LV ejection fraction. Iron deposition can also affect the cardiac conduction system. **Sinus node dysfunction** (ie, sick sinus syndrome) can lead to presyncope or syncope; malignant arrhythmias with sudden cardiac death occasionally occur.

On light microscopy, cardiac hemochromatosis is visible as brown, granular deposits (arrow) in myocytes that stain strongly with Prussian blue. Cardiomyopathy can be the first presenting manifestation of HH, although careful assessment can usually find evidence of iron deposition elsewhere (eg, elevated hepatic transaminases, hepatomegaly). Treatment includes therapeutic phlebotomy to remove excess iron stores, which can lead to regression of cardiomyopathy in some patients.

(Choice A) Amyloidosis is caused by extracellular deposition of misfolded amyloid proteins. Multiorgan involvement (eg, cardiomyopathy, hepatomegaly) is common, but amyloidosis frequently involves the kidney (eg, nephrotic syndrome), nerves (eg, neuropathy), and muscles (eg, macroglossia). It is not associated with hyperpigmentation.

(Choice B) Primary adrenal insufficiency (ie, cortisol deficiency) can cause hyperpigmentation due to cosecretion of melanocyte-stimulating hormone with ACTH (both derived from proopiomelanocortin). However, hepatomegaly is not seen, and although hypotension is common, sinus node and diastolic dysfunction are not.

(Choice C) Sarcoidosis results from widespread formation of noncaseating granulomas. Cardiac infiltration can cause conduction blockade, and liver involvement may result in hepatomegaly. However, lung symptoms (eg, dyspnea, cough) are more common, and skin manifestations include papules and nodules rather than hyperpigmentation.

(Choice D) HH is associated with mutations in the *HFE* gene; the HFE protein binds to the transferrin receptor and regulates intestinal and hepatic iron uptake. Human leukocyte antigen (HLA) mutations are associated with autoimmune disorders (eg, celiac disease, type 1 diabetes).

(Choice F) Glycogen storage disease type II (ie, Pompe disease) is caused by a deficiency in alpha-glucosidase (acid maltase). It manifests shortly after birth with hypertrophic cardiomyopathy, hepatomegaly, muscle weakness, and failure to thrive. Skin hyperpigmentation is not typical.

Educational objective:
Hereditary hemochromatosis is characterized by excessive intestinal iron absorption with deposition of iron in parenchymal tissues. Cardiac manifestations include diastolic dysfunction (initial), dilated cardiomyopathy (later), and conduction system disease (eg, sinus node dysfunction).

Pathology | Gastrointestinal & Nutrition | Hemochromatosis

Settings

1 2 3 4 5 6 7 8 9 10 11 12 13 14 15 16 17 18 19 20 21 22 23 24 25 26 27 28 29 30

Item 31 of 40
Question Id: 394

Mark | Previous | Next | Full Screen | Tutorial | Lab Values | Notes | Calculator | Reverse Color | Text Zoom | Settings

the excess iron in parenchymal tissues.

Exhibit Display

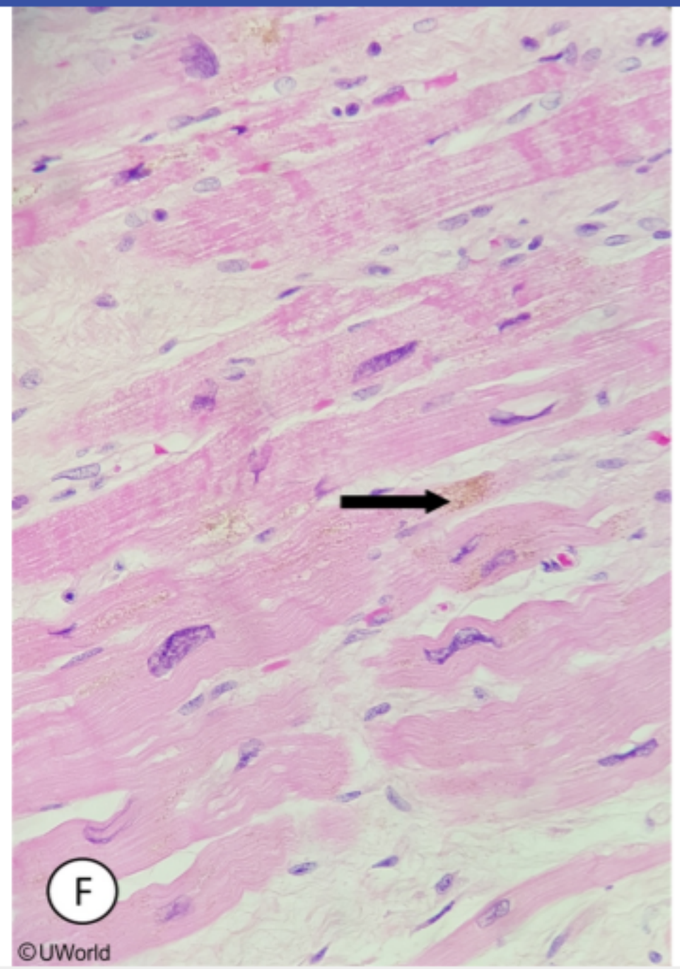

Zoom In | Zoom Out | Reset | Add To New Card | Existing Card

Hereditary hemochromatosis is characterized by excessive intestinal iron absorption with deposition of iron in parenchymal tissues. Cardiac

Block Time Remaining: 00:01:16
TUTOR

3 | Feedback | Suspend | End Block

1 2 3 4 5 6 7 8 9 10 11 12 13 14 15 16 17 18 19 20 21 22 23 24 25 26 27 28 29 30

the excess iron in parenchymal tissues.

Exhibit Display

HFE protein mutations and hemochromatosis

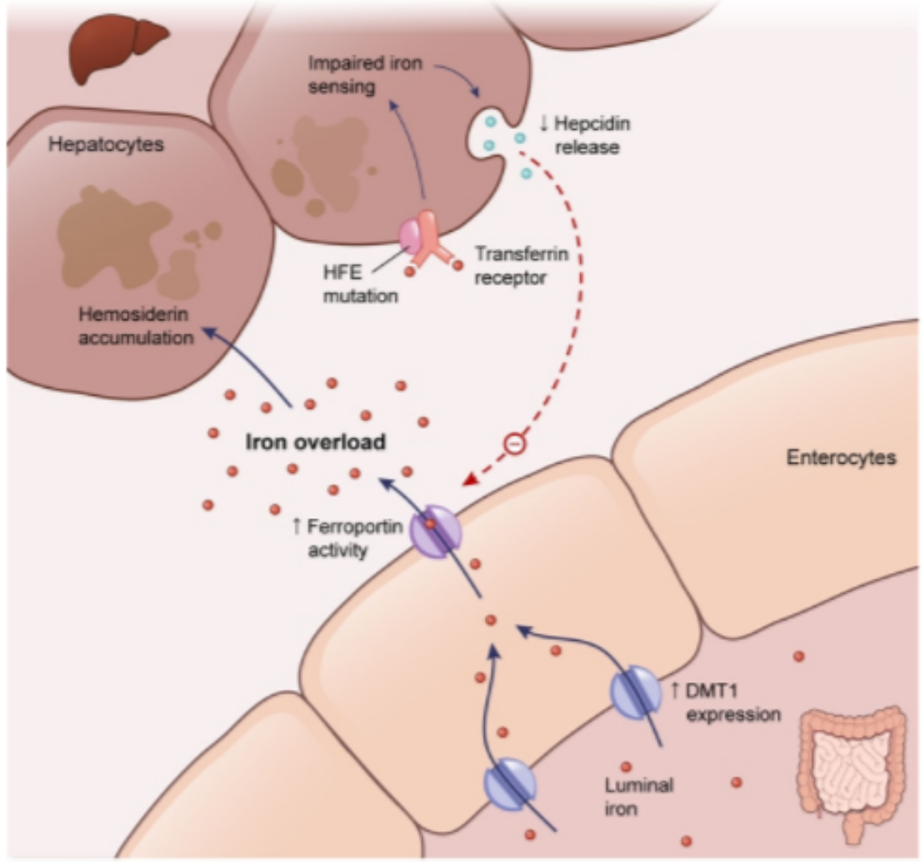

DMT1 = divalent metal transporter 1.
©UWorld

Zoom In | Zoom Out | Reset | Add To New Card | Existing Card

Hereditary hemochromatosis is characterized by excessive intestinal iron absorption with deposition of iron in parenchymal tissues. Cardiac

A 68-year-old woman comes to the office for a preventive visit. The patient feels well, and recently lost 4 kg (8.8 lb) on a new diet and exercise regimen. She has no recent history of abdominal pain, jaundice, or changes in her stools. Past medical history is notable for hypertension and hypercholesterolemia, for which the patient takes appropriate medications. She does not use tobacco, alcohol, or illicit drugs. Vital signs are normal. On examination, the abdomen is soft and nontender, and no hepatosplenomegaly is noted. However, a firm mass is palpated in the right upper quadrant. CT scan of the abdomen is ordered and is shown below.

Settings

1 2 3 4 5 6 7 8 9 10 11 12 13 14 15 16 17 18 19 20 21 22 23 24 25 26 27 28 29 30

Item 32 of 40
Question Id: 87

Mark | Previous | Next | Full Screen | Tutorial | Lab Values | Notes | Calculator | Reverse Color | Text Zoom | Settings

This patient is at elevated risk for which of the following conditions?

- A. Ascending cholangitis
- B. Cholangiocarcinoma
- C. Gallbladder adenocarcinoma
- D. Hepatocellular carcinoma
- E. Liver cirrhosis

Submit

Block Time Remaining: 00:01:19
TUTOR

4 | Feedback | Suspend | End Block

Settings

1 2 3 4 5 6 7 8 9 10 11 12 13 14 15 16 17 18 19 20 21 22 23 24 25 26 27 28 29 30

Item 32 of 40
Question Id: 87

Mark | Previous | Next | Full Screen | Tutorial | Lab Values | Notes | Calculator | Reverse Color | Text Zoom | Settings

This patient is at elevated risk for which of the following conditions?

A. Ascending cholangitis (13%)

B. Cholangiocarcinoma (24%)

✓ C. Gallbladder adenocarcinoma (47%)

D. Hepatocellular carcinoma (11%)

E. Liver cirrhosis (2%)

Omitted
Correct answer

47%
Answered correctly

08 secs
Time Spent

02/06/2020
Last Updated

Block Time Remaining: 00:01:21
TUTOR

4 | Feedback | Suspend | End Block

This patient, with a firm, palpable gallbladder and extensive calcification throughout the gallbladder wall, has typical findings of **porcelain gallbladder**. Patients with this condition may present with right upper quadrant abdominal pain but many are asymptomatic, with findings detected incidentally on imaging done for other reasons. Radiographic features may include a **thickened gallbladder wall** with a rim of patchy or uniform **calcification**.

Porcelain gallbladder is a potential manifestation of **chronic cholecystitis** and is often found in association with multiple gallstones. The pathogenesis is due to dystrophic intramural deposition of calcium salts in the setting of chronic inflammation. Gross findings include a bluish, brittle, thickened gallbladder wall with a "crunchy" texture. Microscopic findings can include calcified plaques within the muscularis or spotty calcification in the mucosa. Porcelain gallbladder is associated with an increased risk of **adenocarcinoma of the gallbladder**.

(Choice A) Acute ascending cholangitis is typically due to gram-negative infection of the intrahepatic biliary tree. It is a consequence of biliary

This patient, with a firm, palpable gallbladder and extensive calcification throughout the gallbladder wall, has typical findings of **porcelain gallbladder**. Patients with this condition may present with right upper quadrant abdominal pain but many are asymptomatic, with findings detected incidentally on imaging done for other reasons. Radiographic features may include a **thickened gallbladder wall** with a rim of patchy or uniform **calcification**.

Porcelain gallbladder is a potential manifestation of **chronic cholecystitis** and is often found in association with multiple gallstones. The pathogenesis is due to dystrophic intramural deposition of calcium salts in the setting of chronic inflammation. Gross findings include a bluish, brittle, thickened gallbladder wall with a "crunchy" texture. Microscopic findings can include calcified plaques within the muscularis or spotty calcification in the mucosa. Porcelain gallbladder is associated with an increased risk of **adenocarcinoma of the gallbladder**.

(Choice A) Acute ascending cholangitis is typically due to gram-negative infection of the intrahepatic biliary tree. It is a consequence of biliary obstruction (eg, choledocholithiasis) and presents with fever, right upper quadrant abdominal pain, and jaundice.

(Choice B) The risk of cholangiocarcinoma is increased in fibrotic diseases of the bile ducts, such as primary sclerosing cholangitis, congenital fibropolycystic diseases, and chronic infection with *Opisthorchis sinensis* (liver fluke).

(Choices D and E) The risk of hepatocellular carcinoma is increased in many chronic inflammatory diseases of the liver, especially those progressing to cirrhosis. Common conditions include chronic viral hepatitis and alcoholic liver disease.

Educational objective:
Porcelain gallbladder is a potential manifestation of chronic cholecystitis and is often found in association with multiple gallstones. It is due to dystrophic intramural deposition of calcium salts in the setting of chronic inflammation. Porcelain gallbladder is associated with an increased risk of adenocarcinoma of the gallbladder.

Pathology	Gastrointestinal & Nutrition	Porcelain gallbladder
Subject	System	Topic

Copyright © UWorld. All rights reserved.

A 53-year-old man with nocturnal cough undergoes an upper endoscopy with esophageal biopsy. Light microscopy of the tissue specimen shows elongation of the lamina propria papillae with several eosinophils and neutrophils scattered within the squamous epithelium. The patient takes metformin and enalapril for diabetes mellitus and hypertension, respectively. He is started on pantoprazole, and after 2 weeks his cough symptoms resolve. Which of the following was the most likely cause of his symptoms?

A. Absent esophageal peristaltic movements

B. Allergen-mediated esophageal disease

C. Gastroesophageal junction incompetence

D. Mucosal disruption from fungal infection

E. Mucosal disruption from viral infection

F. Pill-induced esophageal mucosa damage

Submit

A 53-year-old man with nocturnal cough undergoes an upper endoscopy with esophageal biopsy. Light microscopy of the tissue specimen shows elongation of the lamina propria papillae with several eosinophils and neutrophils scattered within the squamous epithelium. The patient takes metformin and enalapril for diabetes mellitus and hypertension, respectively. He is started on pantoprazole, and after 2 weeks his cough symptoms resolve. Which of the following was the most likely cause of his symptoms?

- A. Absent esophageal peristaltic movements (1%)
- B. Allergen-mediated esophageal disease (14%)
- ✓ C. Gastroesophageal junction incompetence (64%)
- D. Mucosal disruption from fungal infection (7%)
- E. Mucosal disruption from viral infection (1%)
- F. Pill-induced esophageal mucosa damage (10%)

Omitted
Correct answer
C

64%
Answered correctly

01 sec
Time Spent

01/26/2020
Last Updated

Explanation

Gastroesophageal reflux disease (GERD) is a very common condition that usually manifests with heartburn, regurgitation, and dysphagia. However, patients can have **extraesophageal symptoms** (eg, nocturnal **cough**, hoarseness) in the absence of heartburn ("silent GERD").

Gastroesophageal junction incompetence is the primary pathophysiologic mechanism responsible for GERD. This incompetence is most commonly caused by transient lower esophageal sphincter relaxation resulting in the reflux of acidic gastric contents back into the esophagus

Gastroesophageal reflux disease (GERD) is a very common condition that usually manifests with heartburn, regurgitation, and dysphagia. However, patients can have **extraesophageal symptoms** (eg, nocturnal **cough**, hoarseness) in the absence of heartburn ("silent GERD").

Gastroesophageal junction incompetence is the primary pathophysiologic mechanism responsible for GERD. This incompetence is most commonly caused by transient lower esophageal sphincter relaxation resulting in the reflux of acidic gastric contents back into the esophagus. Irritation of the esophageal mucosa leads to an inflammatory reaction with epithelial regeneration. Mucosal erythema/edema can be observed macroscopically in the distal esophagus, and erosions/ulcerations may develop in severe cases. Characteristic histologic findings include basal zone hyperplasia, elongation of the lamina propria papillae, and scattered eosinophils and neutrophils.

(Choice A) Absent esophageal peristaltic movements can be seen with achalasia and systemic sclerosis. The distinctive histopathologic findings of systemic sclerosis involving the esophagus include atrophy of the muscularis with collagenous fibrosis.

(Choice B) Eosinophilic esophagitis is an immune/antigen-mediated disease that typically presents with dysphagia and food impaction in atopic adults. It is characterized histologically by **numerous** superficially located intraepithelial eosinophils, which can help differentiate it from reflux esophagitis. In addition, proton pump inhibitors (eg, pantoprazole) do not usually result in symptomatic improvement.

(Choice D) *Candida albicans* is the most common cause of infectious esophagitis in HIV and immunocompromised patients. Endoscopy typically shows white plaques on an erythematous mucosa, and light microscopy demonstrates pseudohyphae and budding spores embedded in necrotic debris.

(Choice E) Herpes simplex virus (HSV) and cytomegalovirus (CMV) are other common causes of infectious esophagitis in immunocompromised patients. HSV usually shows punched-out ulcers on endoscopy with eosinophilic nuclear inclusions on biopsy. In contrast, CMV produces shallow/linear ulcers with nuclear/cytoplasmic viral inclusions.

(Choice F) Pill-induced esophagitis is commonly seen with tetracycline antibiotics, potassium chloride, and bisphosphonates. Metformin and enalapril do not cause esophagitis.

Educational objective:
Gastroesophageal reflux disease is caused primarily by gastroesophageal junction incompetence and can be associated with extraesophageal symptoms (eg, nocturnal cough) in the absence of heartburn. Acidic gastric contents irritate the esophageal mucosa, leading to characteristic histologic findings that include basal zone hyperplasia, elongation of the lamina propria papillae, and scattered eosinophils.

Settings

1
2
3
4
5
6
7
8
9
10
11
12
13
14
15
16
17
18
19
20
21
22
23
24
25
26
27
28
29
30

Item 33 of 40
Question Id: 286

Mark | Previous | Next | Full Screen | Tutorial | Lab Values | Notes | Calculator | Reverse Color | Text Zoom | Settings

Gastroesophageal reflux disease (GERD) is a very common condition that usually manifests with heartburn, regurgitation, and dysphagia.

Exhibit Display

Zoom In | Zoom Out | Reset | Add To New Card | Existing Card

histologic findings that include basal zone hyperplasia, elongation of the lamina propria papillae, and scattered eosinophils.

Block Time Remaining: 00:01:22
TUTOR

7 | Feedback | Suspend | End Block

Settings

1 2 3 4 5 6 7 8 9 10 11 12 13 14 15 16 17 18 19 20 21 22 23 24 25 26 27 28 29 30

Item 33 of 40
Question Id: 286

Mark | Previous | Next | Full Screen | Tutorial | Lab Values | Notes | Calculator | Reverse Color | Text Zoom | Settings

Gastroesophageal reflux disease (GERD) is a very common condition that usually manifests with heartburn, regurgitation, and dysphagia.

Exhibit Display

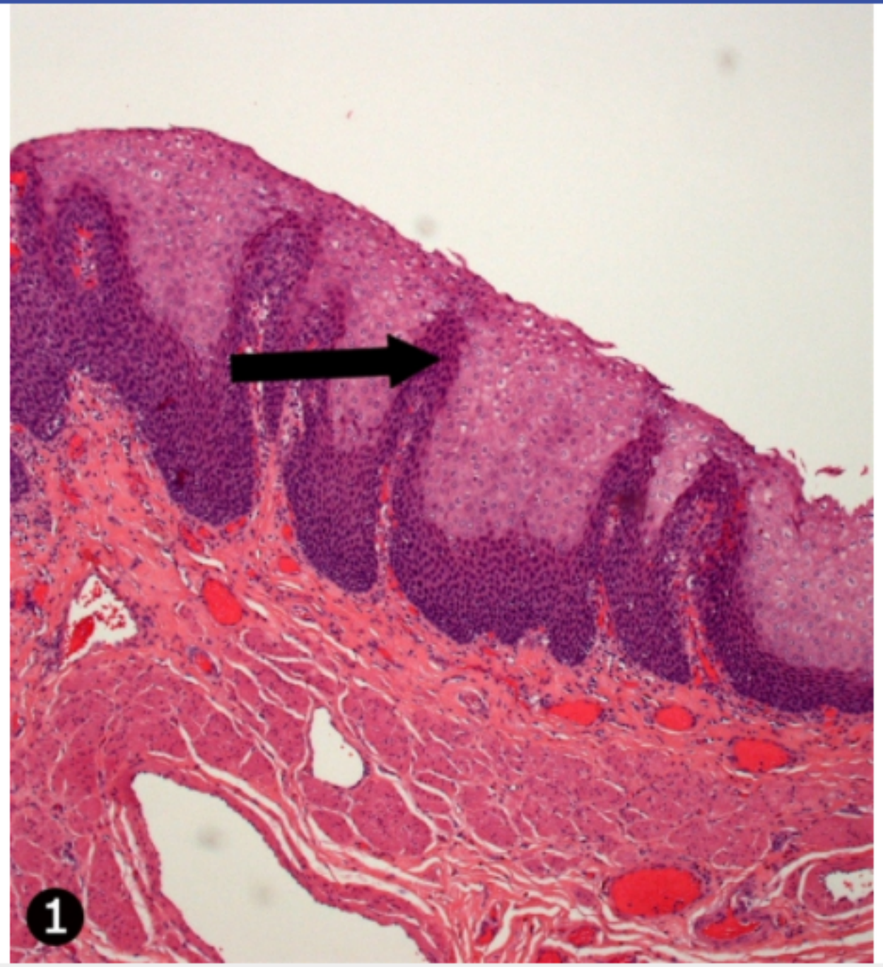

Zoom In | Zoom Out | Reset | Add To New Card | Existing Card

histologic findings that include basal zone hyperplasia, elongation of the lamina propria papillae, and scattered eosinophils.

Block Time Remaining: 00:01:22
TUTOR

7 | Feedback | Suspend | End Block

Settings

1
2
3
4
5
6
7
8
9
10
11
12
13
14
15
16
17
18
19
20
21
22
23
24
25
26
27
28
29
30

Item 33 of 40
Question Id: 286

Mark | Previous | Next | Full Screen | Tutorial | Lab Values | Notes | Calculator | Reverse Color | Text Zoom | Settings

Gastroesophageal reflux disease (GERD) is a very common condition that usually manifests with heartburn, regurgitation, and dysphagia.

Exhibit Display

Zoom In | Zoom Out | Reset | Add To New Card | Existing Card

histologic findings that include basal zone hyperplasia, elongation of the lamina propria papillae, and scattered eosinophils.

Block Time Remaining: 00:01:22
TUTOR

7 | Feedback | Suspend | End Block

Settings

1 2 3 4 5 6 7 8 9 10 11 12 13 14 15 16 17 18 19 20 21 22 23 24 25 26 27 28 29 30

Item 33 of 40
Question Id: 286

Mark | Previous | Next | Full Screen | Tutorial | Lab Values | Notes | Calculator | Reverse Color | Text Zoom | Settings

Gastroesophageal reflux disease (GERD) is a very common condition that usually manifests with heartburn, regurgitation, and dysphagia.

Exhibit Display

Candida Candida esophagitis

Zoom In | Zoom Out | Reset | Add To New Card | Existing Card

histologic findings that include basal zone hyperplasia, elongation of the lamina propria papillae, and scattered eosinophils.

Block Time Remaining: 00:01:22
TUTOR

7 | Feedback | Suspend | End Block

Settings

1 2 3 4 5 6 7 8 9 10 11 12 13 14 15 16 17 18 19 20 21 22 23 24 25 26 27 28 29 30

Item 33 of 40
Question Id: 286

Mark | Previous | Next | Full Screen | Tutorial | Lab Values | Notes | Calculator | Reverse Color | Text Zoom | Settings

Gastroesophageal reflux disease (GERD) is a very common condition that usually manifests with heartburn, regurgitation, and dysphagia.

Exhibit Display

Candida Candida esophagitis

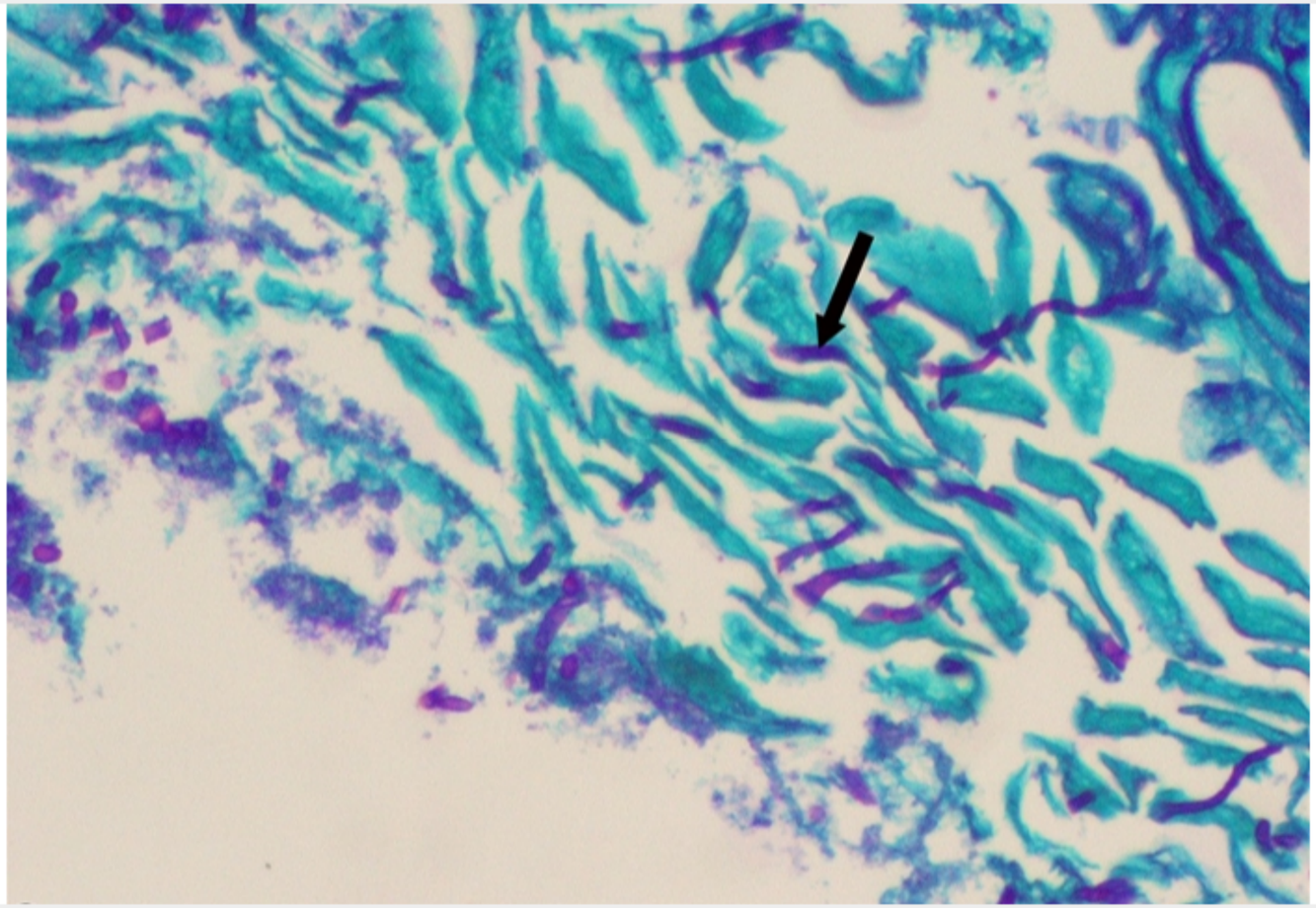

Zoom In | Zoom Out | Reset | Add To New Card | Existing Card

histologic findings that include basal zone hyperplasia, elongation of the lamina propria papillae, and scattered eosinophils.

Block Time Remaining: 00:01:22
TUTOR

7 | Feedback | Suspend | End Block

Settings

1 2 3 4 5 6 7 8 9 10 11 12 13 14 15 16 17 18 19 20 21 22 23 24 25 26 27 28 29 30

Item 33 of 40
Question Id: 286

Mark | Previous | Next | Full Screen | Tutorial | Lab Values | Notes | Calculator | Reverse Color | Text Zoom | Settings

Gastroesophageal reflux disease (GERD) is a very common condition that usually manifests with heartburn, regurgitation, and dysphagia.

Exhibit Display

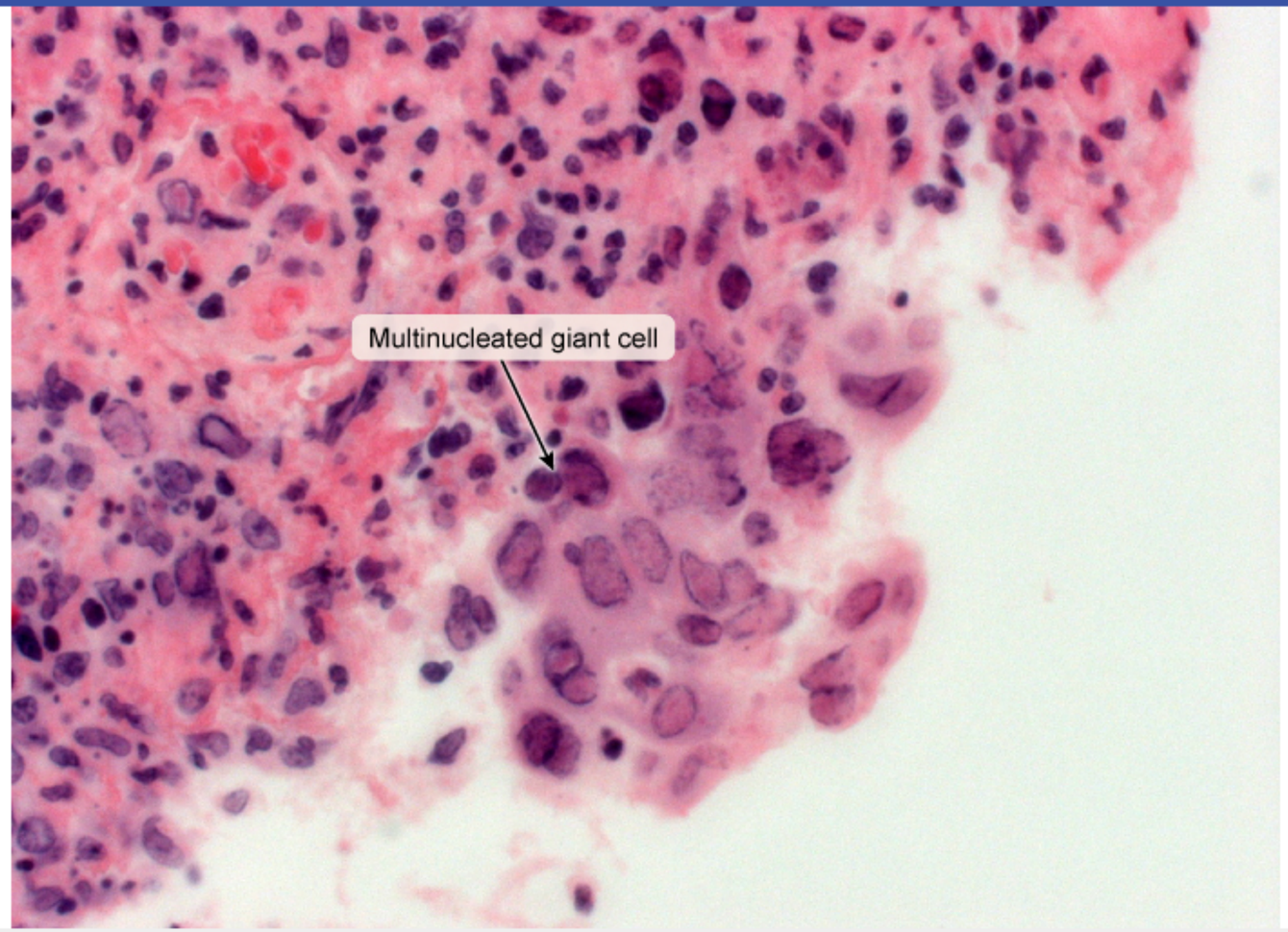

Zoom In | Zoom Out | Reset | Add To New Card | Existing Card

histologic findings that include basal zone hyperplasia, elongation of the lamina propria papillae, and scattered eosinophils.

Block Time Remaining: 00:01:22
TUTOR

7 | Feedback | Suspend | End Block

of systemic sclerosis involving the esophagus include atrophy of the muscularis with collagenous fibrosis.

(Choice B) Eosinophilic esophagitis is an immune/antigen-mediated disease that typically presents with dysphagia and food impaction in atopic adults. It is characterized histologically by **numerous** superficially located intraepithelial eosinophils, which can help differentiate it from reflux esophagitis. In addition, proton pump inhibitors (eg, pantoprazole) do not usually result in symptomatic improvement.

(Choice D) *Candida albicans* is the most common cause of infectious esophagitis in HIV and immunocompromised patients. Endoscopy typically shows white plaques on an erythematous mucosa, and light microscopy demonstrates pseudohyphae and budding spores embedded in necrotic debris.

(Choice E) Herpes simplex virus (HSV) and cytomegalovirus (CMV) are other common causes of infectious esophagitis in immunocompromised patients. HSV usually shows punched-out ulcers on endoscopy with eosinophilic nuclear inclusions on biopsy. In contrast, CMV produces shallow/linear ulcers with nuclear/cytoplasmic viral inclusions.

(Choice F) Pill-induced esophagitis is commonly seen with tetracycline antibiotics, potassium chloride, and bisphosphonates. Metformin and enalapril do not cause esophagitis.

Educational objective:
Gastroesophageal reflux disease is caused primarily by gastroesophageal junction incompetence and can be associated with extraesophageal symptoms (eg, nocturnal cough) in the absence of heartburn. Acidic gastric contents irritate the esophageal mucosa, leading to characteristic histologic findings that include basal zone hyperplasia, elongation of the lamina propria papillae, and scattered eosinophils.

References

- Histology in the diagnosis of reflux esophagitis.
- Microscopic esophagitis in gastro-esophageal reflux disease: individual lesions, biopsy sampling, and clinical correlations.

Pathology	Gastrointestinal & Nutrition	Gastroesophageal reflux disease
Subject	System	Topic

Copyright © UWorld. All rights reserved.

A 65-year-old woman has had several months of progressive fatigue, diminished appetite, and unintentional weight loss. The patient has no chronic medical conditions. She has not received medical care in many years and has not had recommended cancer screening. The patient suddenly dies while undergoing evaluation. Autopsy reveals abnormal liver findings, as shown in the exhibit below.

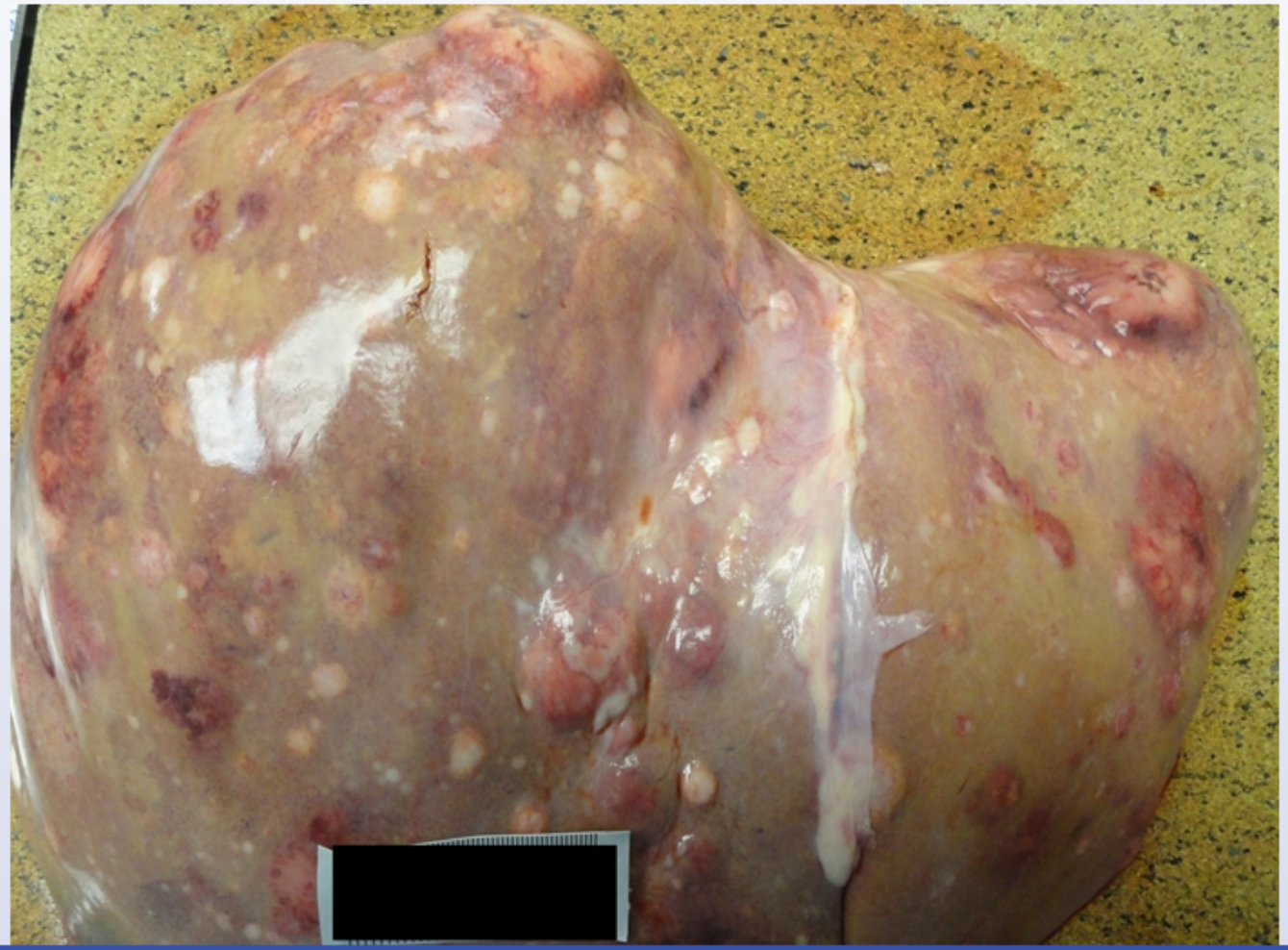

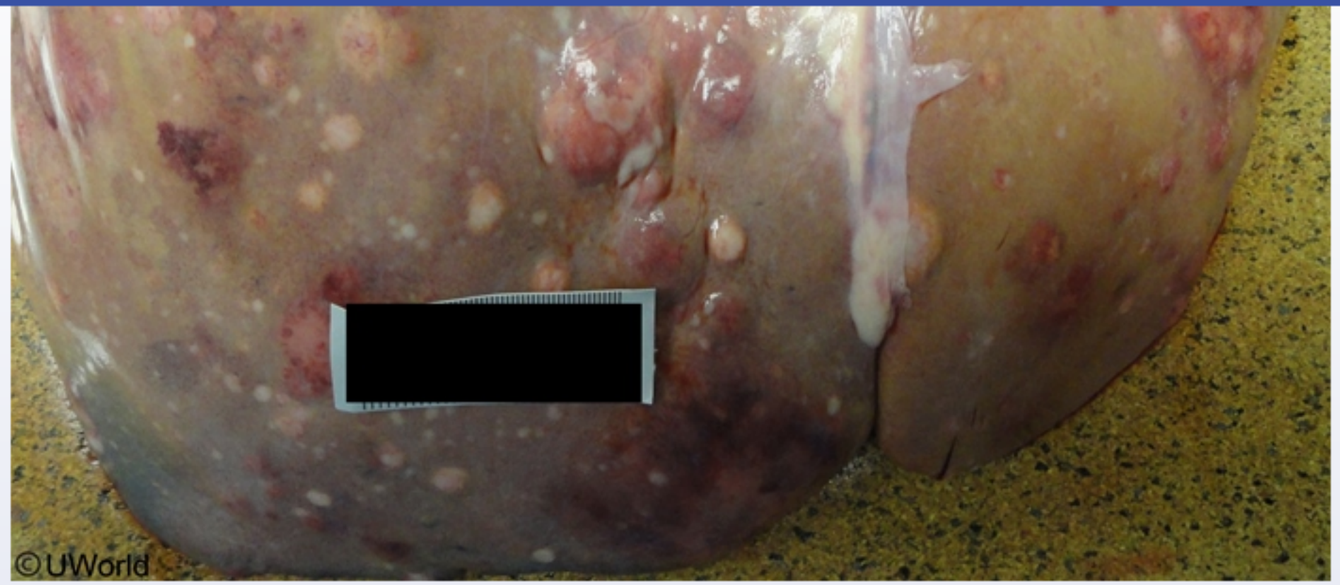

Microscopic evaluation of the lesions reveals neoplastic cells. Which of the following is the most likely cause of this patient's liver lesions?

- A. Lymphatic spread of a malignancy
- B. Malignancy metastasizing via the hepatic veins
- C. Malignancy spreading through the portal circulation
- D. Primary neoplastic transformation of hepatocytes
- E. Transcoelomic spread of a malignancy

Submit

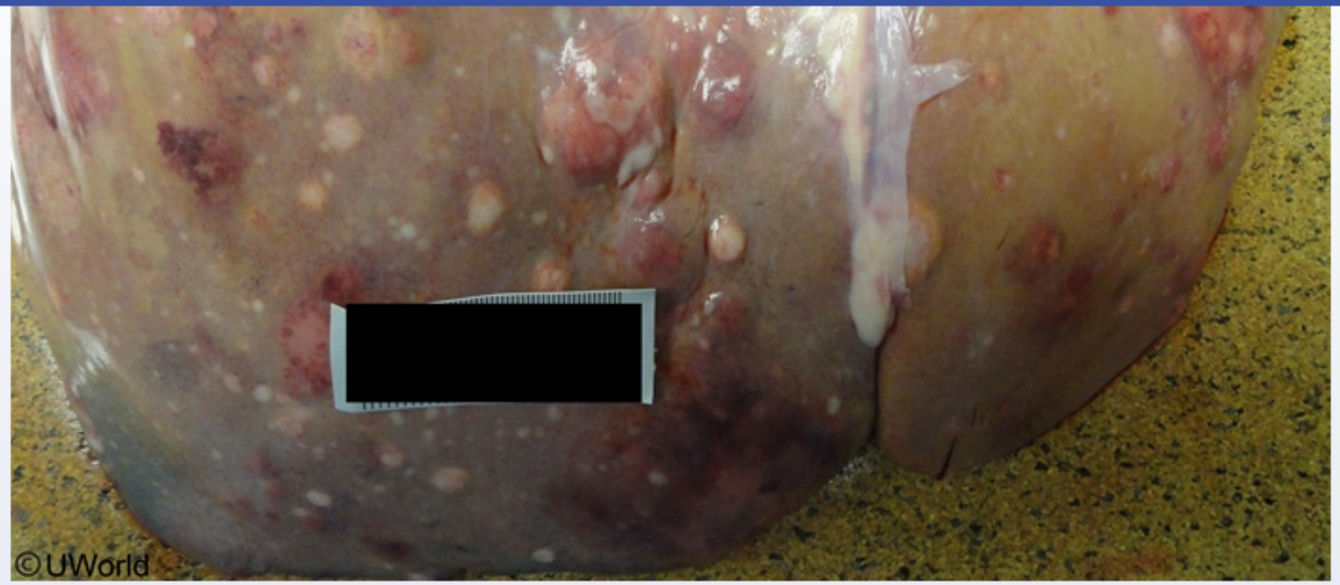

Microscopic evaluation of the lesions reveals neoplastic cells. Which of the following is the most likely cause of this patient's liver lesions?

- A. Lymphatic spread of a malignancy (11%)
- B. Malignancy metastasizing via the hepatic veins (12%)
- ✓ C. Malignancy spreading through the portal circulation (67%)
- D. Primary neoplastic transformation of hepatocytes (4%)
- E. Transcoelomic spread of a malignancy (4%)

Omitted
Correct answer

67%
Answered correctly

05 secs
Time Spent

02/15/2020
Last Updated

Settings

1
2
3
4
5
6
7
8
9
10
11
12
13
14
15
16
17
18
19
20
21
22
23
24
25
26
27
28
29
30

Item 34 of 40
Question Id: 15012

Mark | Previous | Next | Full Screen | Tutorial | Lab Values | Notes | Calculator | Reverse Color | Text Zoom | Settings

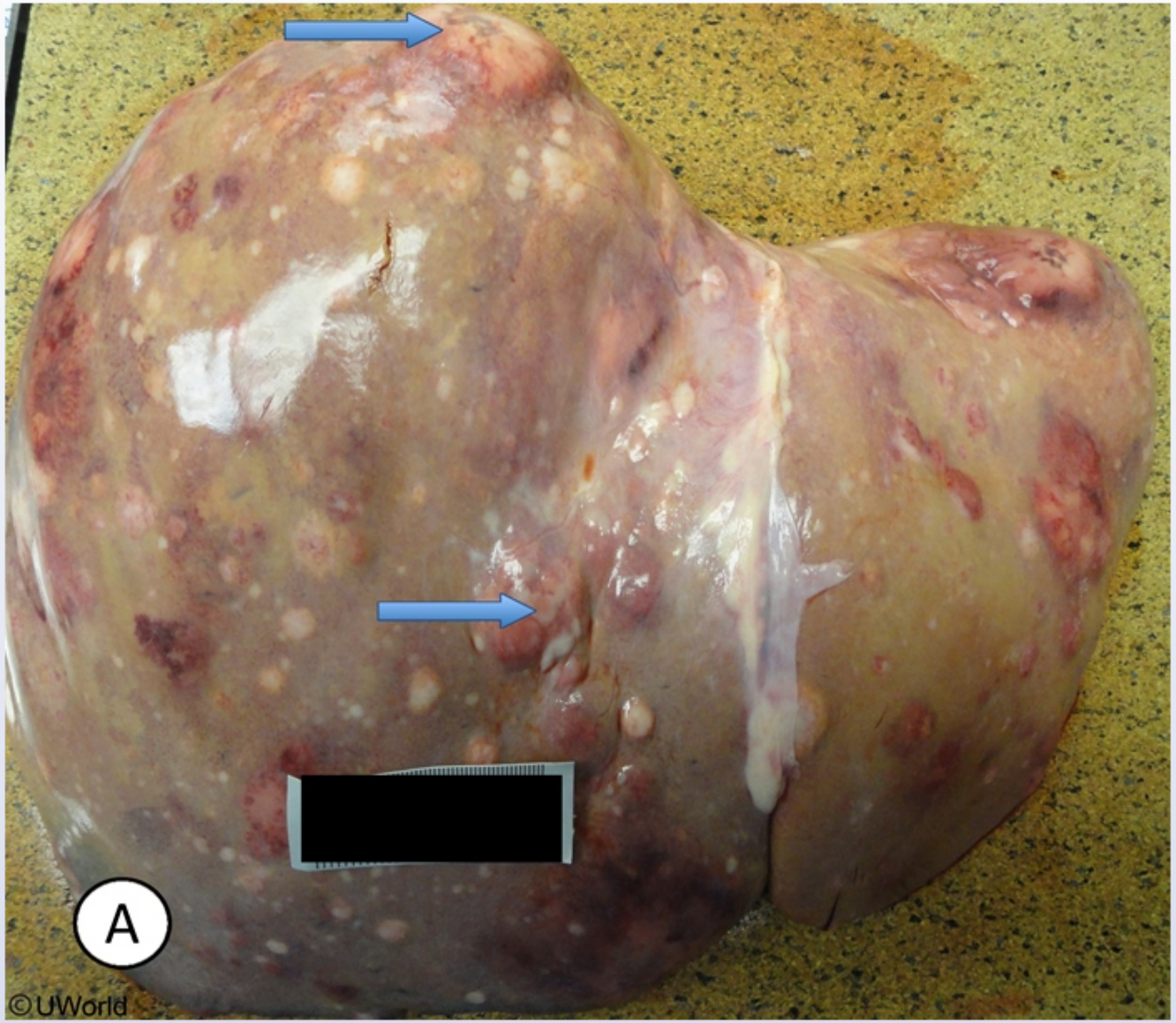

Block Time Remaining: 00:01:27
TUTOR

3 | Feedback | Suspend | End Block

©UWorld

Liver neoplasms are most often due to **metastases** from distant tumors rather than primary liver cancer (eg, hepatocellular carcinoma). Metastatic disease to the liver is particularly likely when **multiple tumors** are present (as seen in this case) and there is no history of underlying hepatic disease such as alcoholic cirrhosis or hepatitis C. The liver is vulnerable to the metastatic spread of cancer due to the following anatomic considerations:

- The presence of **fenestrated hepatic sinusoidal epithelium**, which allows tumor cells to easily pass from the bloodstream through to the parenchyma.
- **Dual blood supply** from the portal and systemic circulation, which increases the likelihood of circulating tumor cells depositing in the liver.

The most common cause of liver metastases is **colorectal cancer**, which spreads directly from the colon or superior rectum through the **portal venous system** to the liver. This patient, who has not received recommended cancer screening (eg, colonoscopy), likely developed hepatic metastases from colorectal cancer. Gastric and pancreatic cancers also frequently spread through the portal system to the liver.

(Choice A) Lymphatic spread of tumor cells is a common mechanism of metastases, but it is not the primary source of most metastatic liver lesions.

(Choice B) Tumors (eg, breast, lung, melanoma) can spread to the liver through the systemic circulation via the hepatic artery (rather than the portal circulation). The hepatic vein drains out of the liver; it does not bring blood into the liver.

(Choice D) Primary hepatic cancer is thirtyfold less common than metastatic disease. Most primary lesions are solitary tumors and arise in individuals with underlying liver disease. This patient, who did not have recommended cancer screening (eg, colonoscopy) and has multiple liver tumors, most likely has metastatic disease.

(Choice E) Although gastrointestinal cancers can spread to the peritoneum and then invade the liver, this is much less common than hematogenous dissemination through the portal system. Metastasis through the peritoneal space most commonly occurs with ovarian cancer and gastric (Krukenberg) tumors.

Educational objective:
Most hepatic neoplasms are due to metastatic disease from a distant site. Colorectal cancer is the most common cause of hepatic metastases due to direct blood flow from the colon (and superior rectum) to the liver via the portal venous circulation.

hepatic disease such as alcoholic cirrhosis or hepatitis C. The liver is vulnerable to the metastatic spread of cancer due to the following anatomic considerations:

- The presence of **fenestrated hepatic sinusoidal epithelium**, which allows tumor cells to easily pass from the bloodstream through to the parenchyma.
- **Dual blood supply** from the portal and systemic circulation, which increases the likelihood of circulating tumor cells depositing in the liver.

The most common cause of liver metastases is **colorectal cancer**, which spreads directly from the colon or superior rectum through the **portal venous system** to the liver. This patient, who has not received recommended cancer screening (eg, colonoscopy), likely developed hepatic metastases from colorectal cancer. Gastric and pancreatic cancers also frequently spread through the portal system to the liver.

(Choice A) Lymphatic spread of tumor cells is a common mechanism of metastases, but it is not the primary source of most metastatic liver lesions.

(Choice B) Tumors (eg, breast, lung, melanoma) can spread to the liver through the systemic circulation via the hepatic artery (rather than the portal circulation). The hepatic vein drains out of the liver; it does not bring blood into the liver.

(Choice D) Primary hepatic cancer is thirtyfold less common than metastatic disease. Most primary lesions are solitary tumors and arise in individuals with underlying liver disease. This patient, who did not have recommended cancer screening (eg, colonoscopy) and has multiple liver tumors, most likely has metastatic disease.

(Choice E) Although gastrointestinal cancers can spread to the peritoneum and then invade the liver, this is much less common than hematogenous dissemination through the portal system. Metastasis through the peritoneal space most commonly occurs with ovarian cancer and gastric (Krukenberg) tumors.

Educational objective:
Most hepatic neoplasms are due to metastatic disease from a distant site. Colorectal cancer is the most common cause of hepatic metastases due to direct blood flow from the colon (and superior rectum) to the liver via the portal venous circulation.

Pathology	Gastrointestinal & Nutrition	Colorectal cancer
Subject	System	Topic

A 48-year-old man comes to the emergency department due to 3 days of progressively worsening retrosternal burning chest pain, dysphagia, and odynophagia. His medical problems include hypertension and end-stage renal disease. He underwent cadaveric renal allograft transplantation 8 months ago. The patient's temperature is 38.3 C (101 F), blood pressure is 130/80 mm Hg, and pulse is 94/min. His BMI is 31 kg/m^2. The oral mucosa is pink and moist without ulcerations. Cardiopulmonary examination is normal. The abdomen is soft with mild epigastric tenderness. The patient's leukocyte count is 4,200/mm^3. An esophagogastroduodenoscopy demonstrates linear, shallow ulceration in the lower esophagus. Which of the following is the most likely finding on an esophageal biopsy sample?

A. Enlarged cells with intranuclear inclusions

B. Metaplastic columnar epithelium

C. Mucosal tear without acute inflammation

D. Urease-producing organisms

E. Yeast with polysaccharide capsule

Submit

A 48-year-old man comes to the emergency department due to 3 days of progressively worsening retrosternal burning chest pain, dysphagia, and odynophagia. His medical problems include hypertension and end-stage renal disease. He underwent cadaveric renal allograft transplantation 8 months ago. The patient's temperature is 38.3 C (101 F), blood pressure is 130/80 mm Hg, and pulse is 94/min. His BMI is 31 kg/m^2. The oral mucosa is pink and moist without ulcerations. Cardiopulmonary examination is normal. The abdomen is soft with mild epigastric tenderness. The patient's leukocyte count is 4,200/mm^3. An esophagogastroduodenoscopy demonstrates linear, shallow ulceration in the lower esophagus. Which of the following is the most likely finding on an esophageal biopsy sample?

- ✓ A. Enlarged cells with intranuclear inclusions (56%)
- B. Metaplastic columnar epithelium (16%)
- C. Mucosal tear without acute inflammation (13%)
- D. Urease-producing organisms (5%)
- E. Yeast with polysaccharide capsule (7%)

Omitted
Correct answer
A

56%
Answered correctly

02 secs
Time Spent

01/14/2020
Last Updated

Explanation

This patient's presentation suggests **cytomegalovirus (CMV) esophagitis**, which can occur in immunocompromised patients (eg, HIV, transplant, on immunosuppressant drugs). CMV can be transmitted to **transplant recipients** from the donor organ, or infection can occur subsequently due to chronic immunosuppression. Patients can be asymptomatic or develop a viral prodrome (eg, fever, malaise, myalgias) before organ involvement (eg, esophagitis, pneumonitis, colitis).

This patient's presentation suggests **cytomegalovirus (CMV) esophagitis**, which can occur in immunocompromised patients (eg, HIV, transplant, on immunosuppressant drugs). CMV can be transmitted to **transplant recipients** from the donor organ, or infection can occur subsequently due to chronic immunosuppression. Patients can be asymptomatic or develop a viral prodrome (eg, fever, malaise, myalgias) before organ involvement (eg, esophagitis, pneumonitis, colitis).

CMV esophagitis usually presents with **odynophagia** (pain with swallowing) or **dysphagia** (difficulty swallowing) that can be accompanied by fever or burning chest pain. Endoscopy typically shows **linear and shallow ulcerations** in the lower esophagus that sometimes diffusely involve the esophagus. Tissue biopsy usually shows enlarged cells with basophilic or eosinophilic **intranuclear inclusion bodies**.

(Choice B) Metaplastic columnar epithelium is seen in Barrett's esophagus, which is usually due to prolonged gastroesophageal reflux disease (GERD). Histology typically shows tongue-like projections of intestinal columnar epithelium extending from the distal esophagus to the gastroesophageal junction. The absence of chronic GERD symptoms in this patient makes this less likely.

(Choice C) A Mallory-Weiss tear typically presents with burning chest pain after repeated retching or vomiting. Histology can show a mucosal tear without acute inflammation. However, this patient has no retching or vomiting.

(Choice D) *Helicobacter pylori* is a urease-producing organism that can be associated with gastric or duodenal ulcers. It usually does not cause significant esophageal disease.

(Choice E) *Cryptococcus neoformans* is a yeast with a polysaccharide capsule that can be detected microscopically with India ink stain. Although disseminated cryptococcosis can involve almost any organ, *Candida* esophagitis is more common and presents with odynophagia. However, *Candida* does not have a polysaccharide capsule.

Educational objective:
Cytomegalovirus esophagitis can occur in transplant patients and usually presents with odynophagia or dysphagia that can be accompanied by fever or burning chest pain. Endoscopy typically shows linear and shallow ulcerations in the lower esophagus, and histology usually shows enlarged cells with intranuclear inclusions.

References

- Cytomegalovirus infection of the upper gastrointestinal tract: a clinical and pathological study of 30 cases.

Settings

1 2 3 4 5 6 7 8 9 10 11 12 13 14 15 16 17 18 19 20 21 22 23 24 25 26 27 28 29 30

Item 35 of 40
Question Id: 11548

Mark | Previous | Next | Full Screen | Tutorial | Lab Values | Notes | Calculator | Reverse Color | Text Zoom | Settings

Exhibit Display

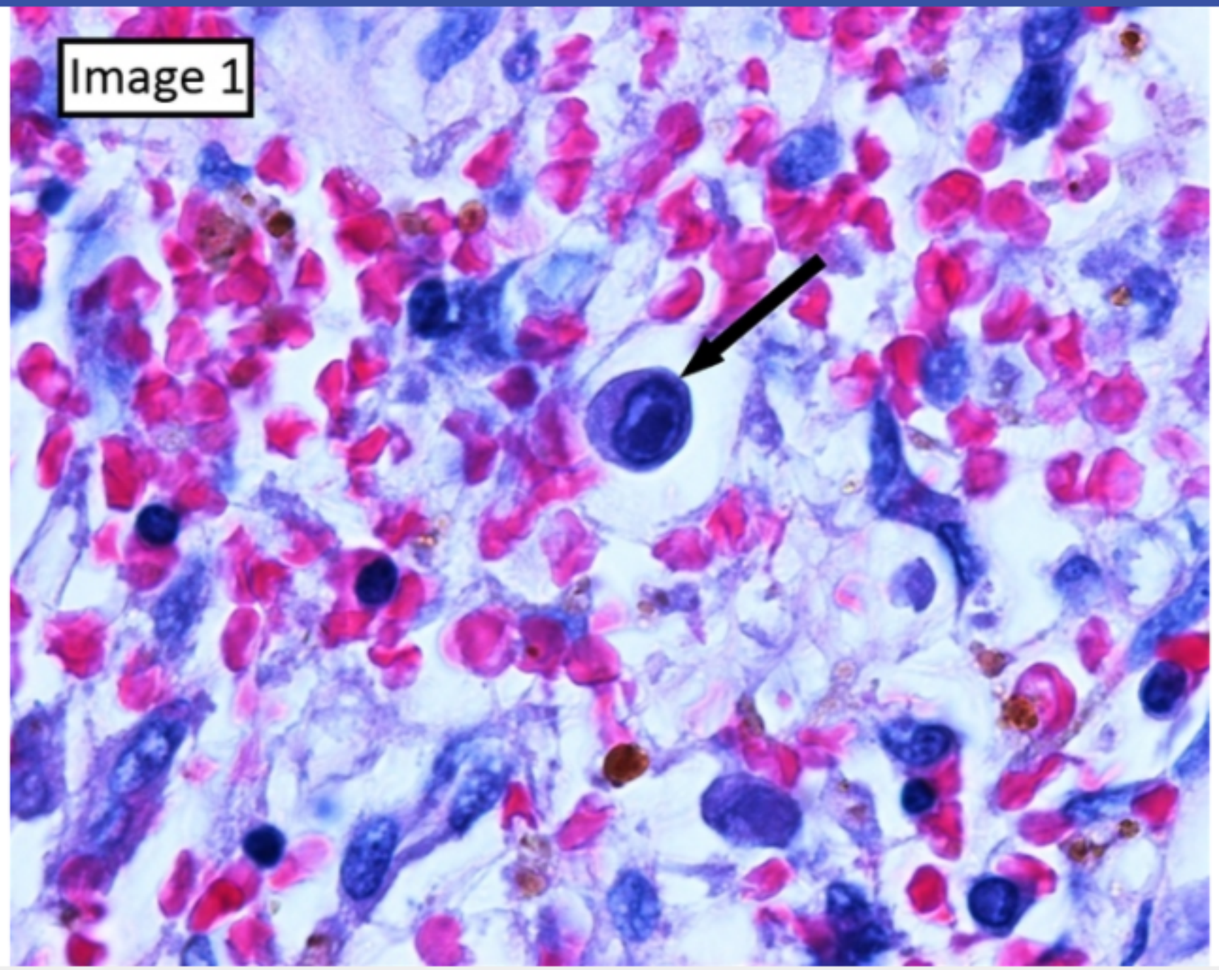

Zoom In | Zoom Out | Reset | Add To New Card | Existing Card

- Cytomegalovirus infection of the upper gastrointestinal tract: a clinical and pathological study of 30 cases.

Block Time Remaining: 00:01:29
TUTOR

3 | Feedback | Suspend | End Block

Settings

1
2
3
4
5
6
7
8
9
10
11
12
13
14
15
16
17
18
19
20
21
22
23
24
25
26
27
28
29
30

Item 35 of 40
Question Id: 11548

Mark | Previous | Next | Full Screen | Tutorial | Lab Values | Notes | Calculator | Reverse Color | Text Zoom | Settings

Exhibit Display

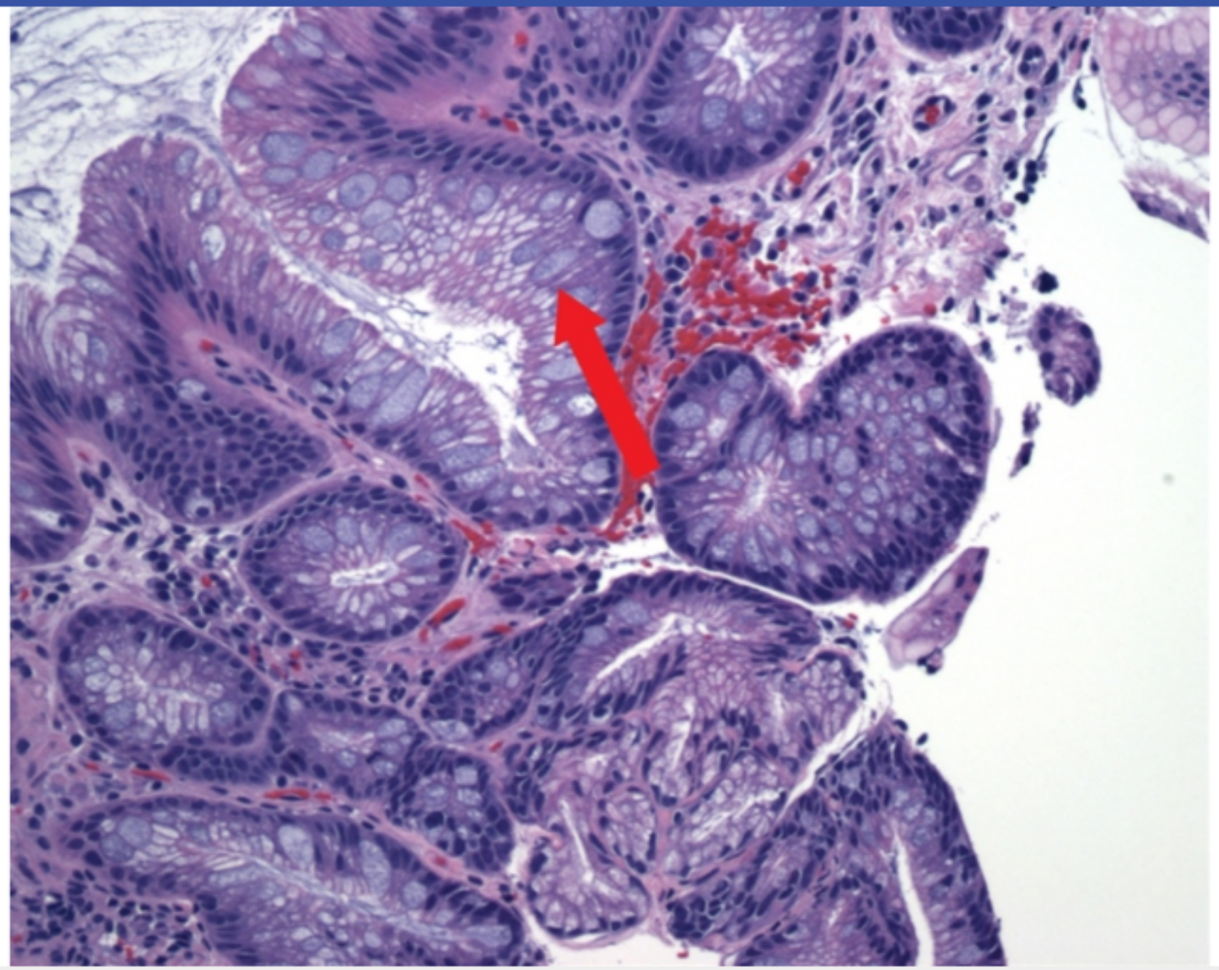

Zoom In | Zoom Out | Reset | Add To New Card | Existing Card

- Cytomegalovirus infection of the upper gastrointestinal tract: a clinical and pathological study of 30 cases.

Block Time Remaining: 00:01:29
TUTOR

3 | Feedback | Suspend | End Block

Settings

1
2
3
4
5
6
7
8
9
10
11
12
13
14
15
16
17
18
19
20
21
22
23
24
25
26
27
28
29
30

Item 35 of 40
Question Id: 11548

Mark | Previous | Next | Full Screen | Tutorial | Lab Values | Notes | Calculator | Reverse Color | Text Zoom | Settings

Exhibit Display

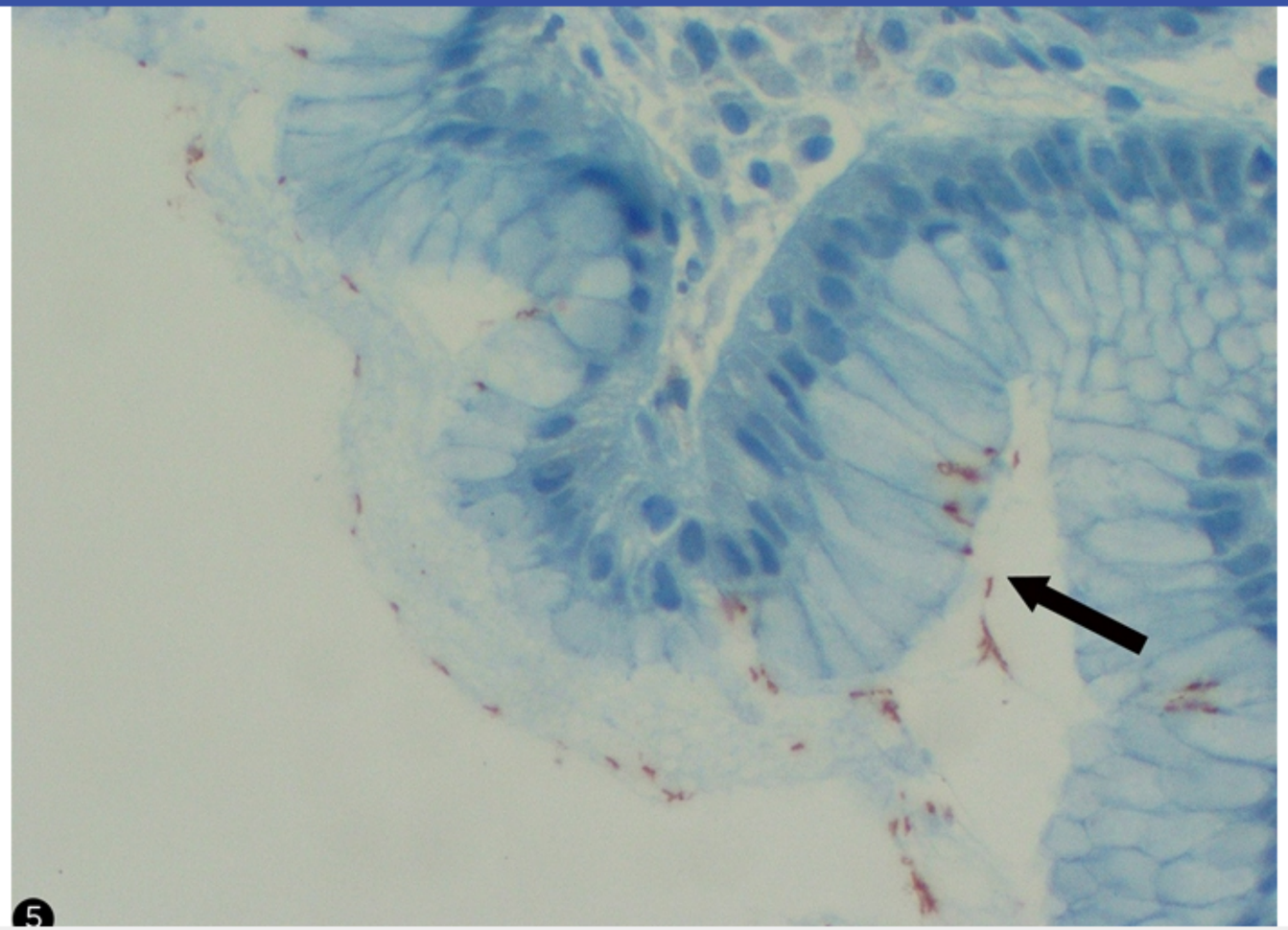

Zoom In | Zoom Out | Reset | Add To New Card | Existing Card

- Cytomegalovirus infection of the upper gastrointestinal tract: a clinical and pathological study of 30 cases.

Block Time Remaining: 00:01:29
TUTOR

3 | Feedback | Suspend | End Block

Settings

1 2 3 4 5 6 7 8 9 10 11 12 13 14 15 16 17 18 19 20 21 22 23 24 25 26 27 28 29 30

Item 35 of 40
Question Id: 11548

Mark | Previous | Next | Full Screen | Tutorial | Lab Values | Notes | Calculator | Reverse Color | Text Zoom | Settings

Exhibit Display

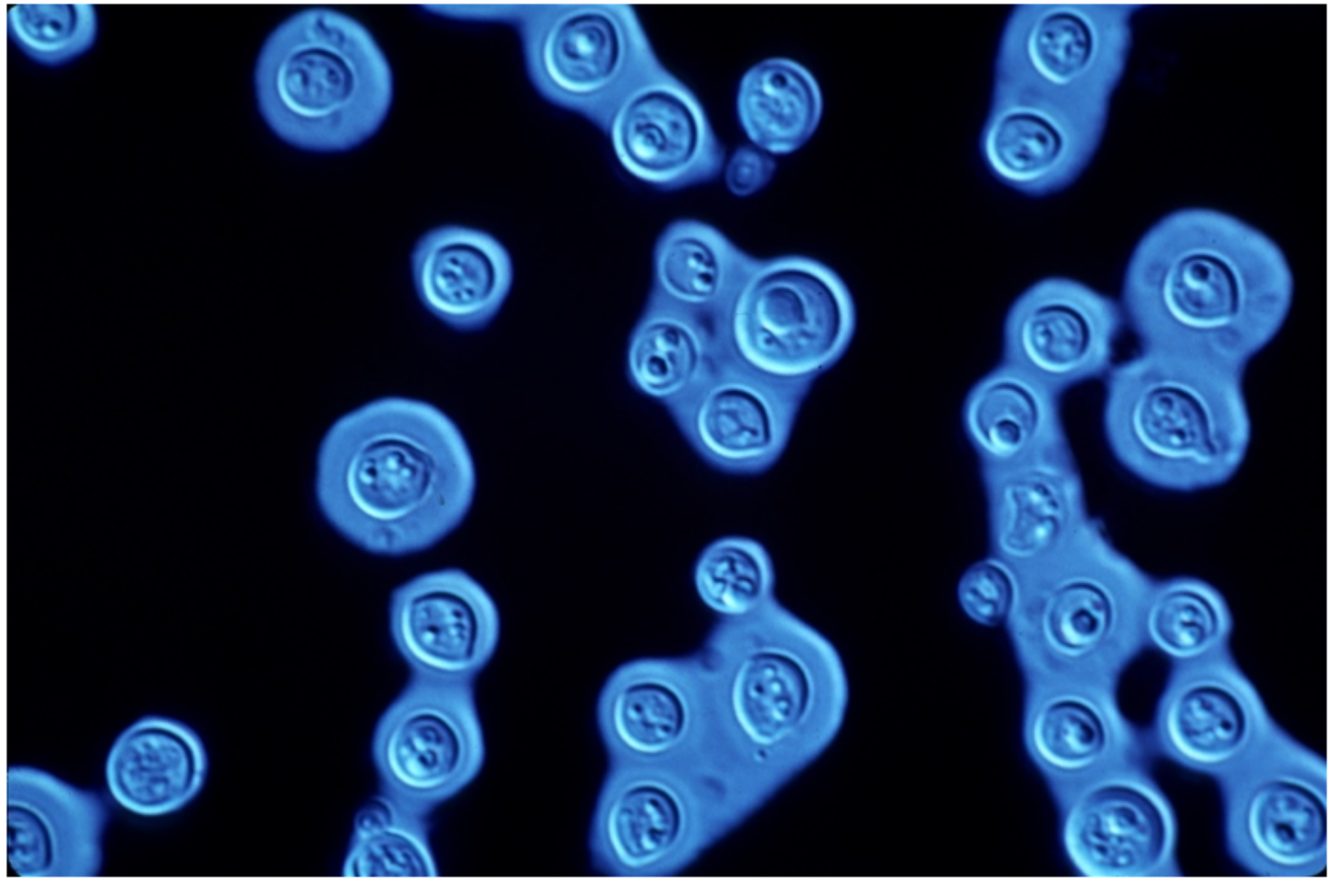

Zoom In | Zoom Out | Reset | Add To New Card | Existing Card

- Cytomegalovirus infection of the upper gastrointestinal tract: a clinical and pathological study of 30 cases.

Block Time Remaining: 00:01:29
TUTOR

3 | Feedback | Suspend | End Block

A 21-year-old woman is hospitalized for elective subtotal colectomy with ileo-rectal anastomosis due to abnormal colonoscopic findings. She underwent screening colonoscopy because of family history of colon cancer. Her maternal grandfather died of metastatic colon cancer, and her mother was also recently diagnosed with colon cancer. The patient has no other medical problems, takes no medications, and does not use tobacco, alcohol, or illicit drugs. The surgery is performed with no operative complications. Numerous lesions are present throughout the resected colon, some of which are shown in the histopathology exhibit below.

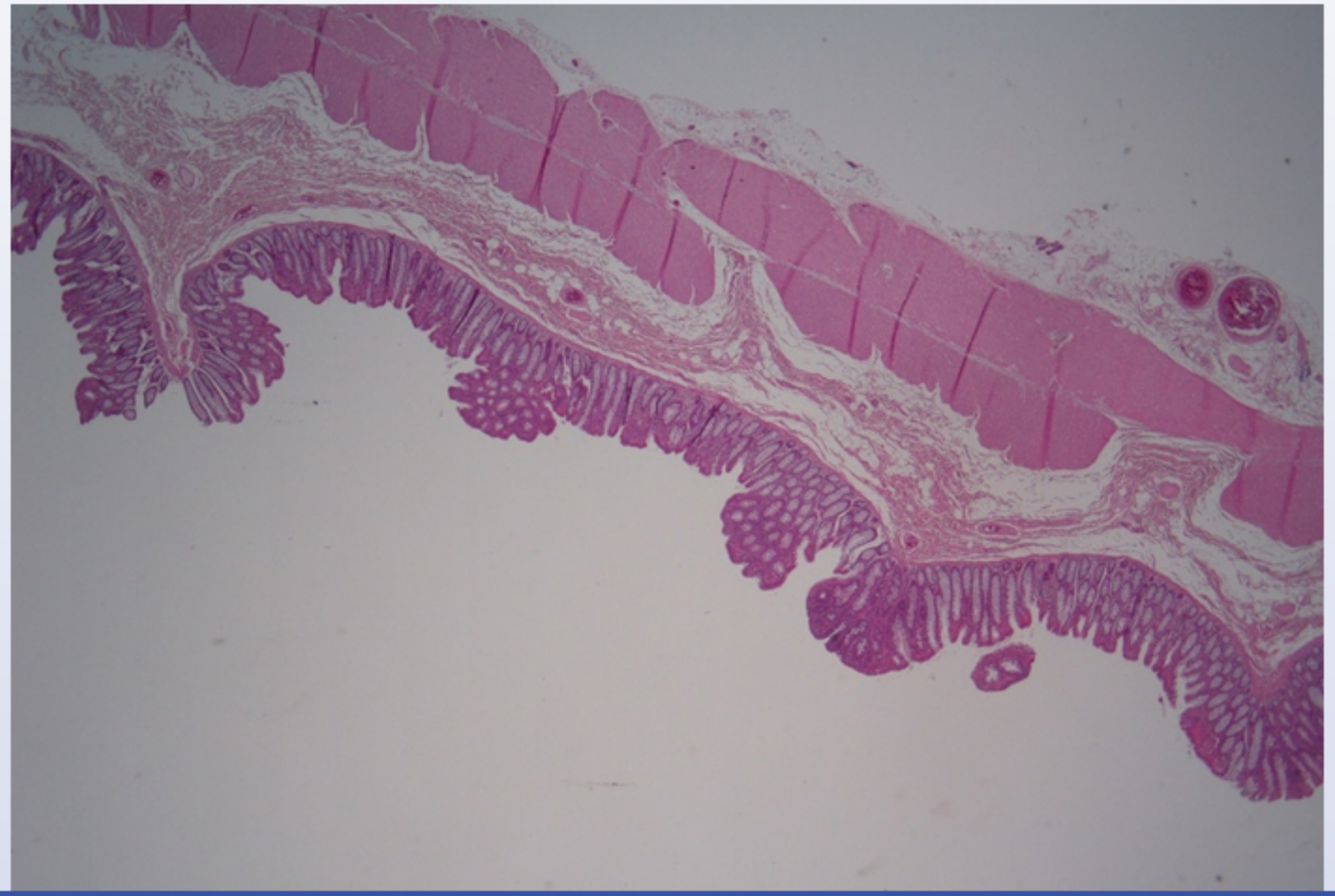

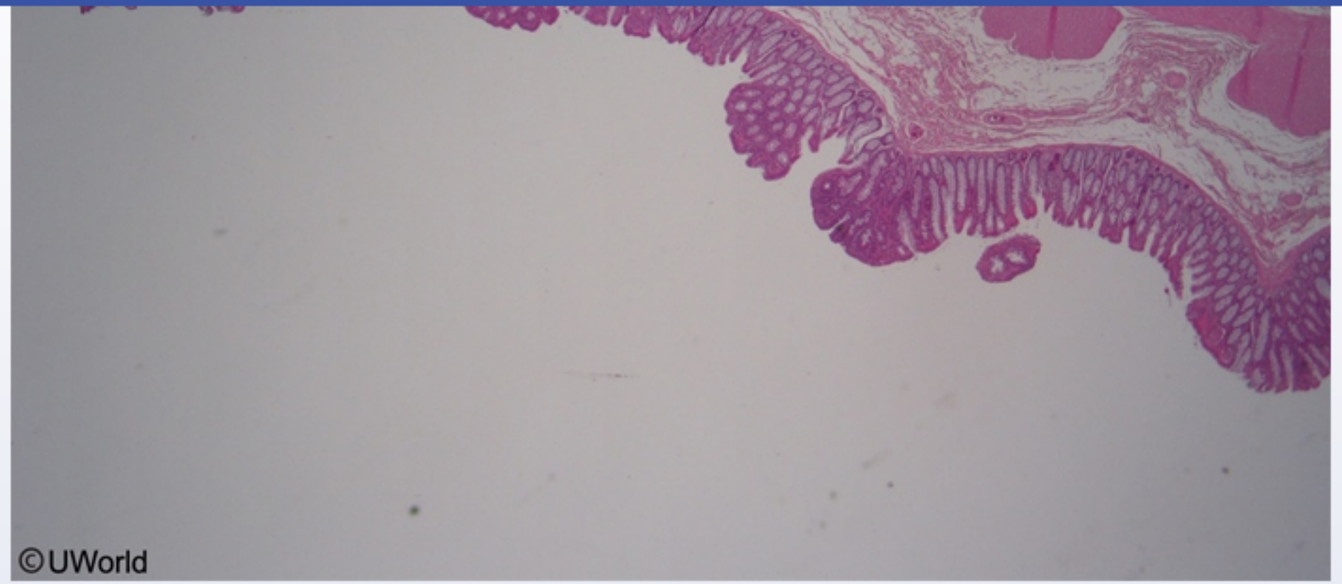

This patient's condition is most likely caused by a genetic mutation leading to which of the following?

- A. Abnormality of RAS signaling protein
- B. Absence of regulatory *TP53* protein
- C. Defective repair of DNA mismatches
- D. Increase in cellular telomerase activity
- E. Loss of functional APC protein

Submit

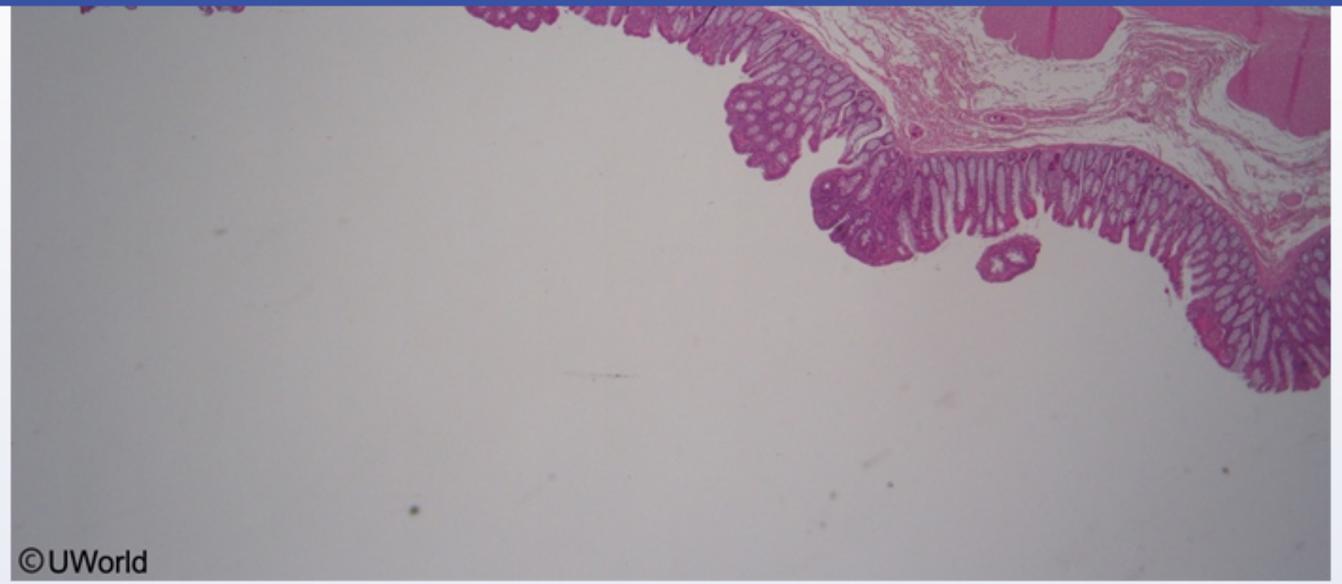

This patient's condition is most likely caused by a genetic mutation leading to which of the following?

A. Abnormality of RAS signaling protein (5%)

B. Absence of regulatory *TP53* protein (5%)

C. Defective repair of DNA mismatches (15%)

D. Increase in cellular telomerase activity (0%)

✓ E. Loss of functional APC protein (73%)

Omitted
Correct answer

73%
Answered correctly

09 secs
Time Spent

01/29/2020
Last Updated

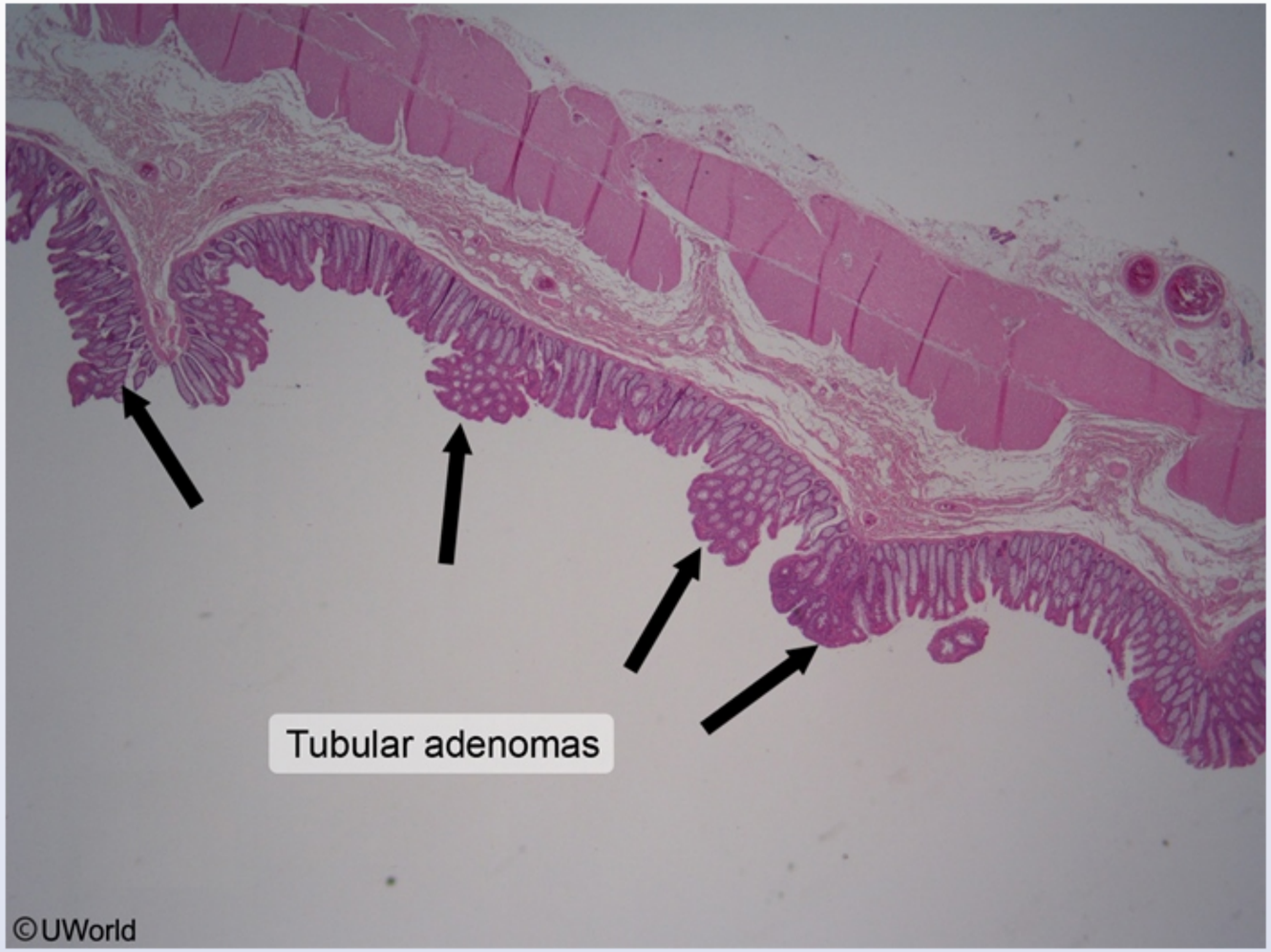

This young patient has evidence of multiple adenomas on colonic biopsy, raising strong suspicion for the autosomal dominant disorder **familial adenomatous polyposis** (FAP). Patients with FAP usually develop **innumerable colonic polyps** in the second or third decade of life. The lifetime risk that ≥1 of these polyps will transform to **invasive colon cancer** is nearly 100%. Therefore, prophylactic colectomy is usually advised.

This young patient has evidence of multiple adenomas on colonic biopsy, raising strong suspicion for the autosomal dominant disorder **familial adenomatous polyposis** (FAP). Patients with FAP usually develop **innumerable colonic polyps** in the second or third decade of life. The lifetime risk that ≥1 of these polyps will transform to **invasive colon cancer** is nearly 100%. Therefore, prophylactic colectomy is usually advised.

FAP is caused by a germline mutation to the tumor suppressor gene ***adenomatous polyposis coli*** (APC). Although it is an autosomal dominant disorder, a spontaneous mutation to the other (wild-type) *APC* gene is required for expression (which usually occurs in the patient's teens or twenties). *APC* encodes for a protein that degrades beta-catenin. Loss of function of the APC protein increases cellular concentrations of beta-catenin, which activates transcriptional proteins that lead to intestinal crypt proliferation and the subsequent development of polyps.

APC plays a crucial role in generation of both hereditary and spontaneous forms of colon cancer. Nearly 80% of spontaneous colon cancer has spontaneous mutations to both sets of *APC* genes; the remainder typically has activating mutations to downstream products of the pathway.

(Choice A) *RAS* oncogene mutations lead to constitutively active growth signal transduction. *RAS* mutations (particularly *KRAS*) are present in approximately 50% of sporadic colon cancers. FAP is not due to mutations in *RAS*.

(Choice B) *TP53* acts as a transcriptional activator of genes that inhibit cellular growth. *TP53* mutations are the most common genetic abnormality seen in all cancers, and they are present in approximately 75% of colorectal cancers. Germline mutation to *TP53* is associated with Li Fraumeni syndrome; these patients have increased risk of many tumor types but, for unclear reasons, are not at particularly increased risk for colorectal cancer.

(Choice C) Lynch syndrome is associated with hereditary nonpolyposis colorectal cancer due to germline mutation to one of the DNA mismatch repair genes (eg, *MSH2/6*, *MLH1*). These patients do not have extensive polyposis in the colon but are very likely to develop colon cancer (from dysplasia in flat colonic mucosa).

(Choice D) Telomerase prevents the shortening of telomeres during cellular division, which extends the life of the cell. Telomerase activity is increased in many cancer types but is not especially linked to colorectal cancer.

Educational objective:
Familial adenomatous polyposis is an autosomal-dominant hereditary disorder that results in the formation of innumerable colonic polyps and a nearly 100% risk of colorectal cancer. It arises due to germline mutation to the tumor suppressor gene, *adenomatous polyposis coli*.

disorder, a spontaneous mutation to the other (wild-type) *APC* gene is required for expression (which usually occurs in the patient's teens or twenties). *APC* encodes for a protein that degrades beta-catenin. Loss of function of the APC protein increases cellular concentrations of beta-catenin, which activates transcriptional proteins that lead to intestinal crypt proliferation and the subsequent development of polyps.

APC plays a crucial role in generation of both hereditary and spontaneous forms of colon cancer. Nearly 80% of spontaneous colon cancer has spontaneous mutations to both sets of *APC* genes; the remainder typically has activating mutations to downstream products of the pathway.

(Choice A) *RAS* oncogene mutations lead to constitutively active growth signal transduction. *RAS* mutations (particularly *KRAS*) are present in approximately 50% of sporadic colon cancers. FAP is not due to mutations in *RAS*.

(Choice B) *TP53* acts as a transcriptional activator of genes that inhibit cellular growth. *TP53* mutations are the most common genetic abnormality seen in all cancers, and they are present in approximately 75% of colorectal cancers. Germline mutation to *TP53* is associated with Li Fraumeni syndrome; these patients have increased risk of many tumor types but, for unclear reasons, are not at particularly increased risk for colorectal cancer.

(Choice C) Lynch syndrome is associated with hereditary nonpolyposis colorectal cancer due to germline mutation to one of the DNA mismatch repair genes (eg, *MSH2/6*, *MLH1*). These patients do not have extensive polyposis in the colon but are very likely to develop colon cancer (from dysplasia in flat colonic mucosa).

(Choice D) Telomerase prevents the shortening of telomeres during cellular division, which extends the life of the cell. Telomerase activity is increased in many cancer types but is not especially linked to colorectal cancer.

Educational objective:
Familial adenomatous polyposis is an autosomal-dominant hereditary disorder that results in the formation of innumerable colonic polyps and a nearly 100% risk of colorectal cancer. It arises due to germline mutation to the tumor suppressor gene, *adenomatous polyposis coli*.

Pathology	Gastrointestinal & Nutrition	Familial adenomatous polyposis
Subject	System	Topic

Copyright © UWorld. All rights reserved.

A 28-year-old woman at 32 weeks gestation is seen in the office for a routine prenatal visit. The patient has had burning, squeezing pain in the middle of her chest that lasts for minutes to hours at a time and usually occurs after meals. The pain is occasionally accompanied by small amounts of sour-tasting material in the back of her throat. The patient does not have any abdominal pain, emesis, or visible blood in the stool. Her pregnancy has been complicated by gestational diabetes mellitus, which has been well controlled with nutritional therapy and exercise. She does not use alcohol, tobacco, or illicit drugs. Vital signs are normal. Fundal height is 32 cm and fetal heart tones are normal. Which of the following is the most likely cause of the patient's symptoms?

A. Decreased lower esophageal sphincter tone

B. Delayed gastric emptying

C. Diffuse spasm of the esophageal smooth muscle

D. *Helicobacter pylori* infection

E. Increased gastric acid production

Submit

A 28-year-old woman at 32 weeks gestation is seen in the office for a routine prenatal visit. The patient has had burning, squeezing pain in the middle of her chest that lasts for minutes to hours at a time and usually occurs after meals. The pain is occasionally accompanied by small amounts of sour-tasting material in the back of her throat. The patient does not have any abdominal pain, emesis, or visible blood in the stool. Her pregnancy has been complicated by gestational diabetes mellitus, which has been well controlled with nutritional therapy and exercise. She does not use alcohol, tobacco, or illicit drugs. Vital signs are normal. Fundal height is 32 cm and fetal heart tones are normal. Which of the following is the most likely cause of the patient's symptoms?

- ✓ A. Decreased lower esophageal sphincter tone (71%)
- B. Delayed gastric emptying (18%)
- C. Diffuse spasm of the esophageal smooth muscle (3%)
- D. *Helicobacter pylori* infection (1%)
- E. Increased gastric acid production (4%)

Omitted
Correct answer
A

71%
Answered correctly

01 sec
Time Spent

01/24/2020
Last Updated

Explanation

Gastroesophageal reflux is characterized by the retrograde movement of acidic stomach contents through the lower esophageal sphincter (LES) into the esophagus. Manifestations are most common in the minutes or hours after eating and typically include burning, squeezing pain in the retrosternal area, and the regurgitation of acidic (sour-tasting) stomach contents into the mouth.

Gastroesophageal reflux is characterized by the retrograde movement of acidic stomach contents through the lower esophageal sphincter (LES) into the esophagus. Manifestations are most common in the minutes or hours after eating and typically include burning, squeezing pain in the retrosternal area, and the regurgitation of acidic (sour-tasting) stomach contents into the mouth.

Reflux occurs in most **pregnant women** and is common in all trimesters. The major underlying cause is **elevated estrogen and progesterone levels**, which relax the smooth muscle of the LES leading to **decreased LES tone** and reduced sensitivity to contractile stimuli (eg, high-protein meal). Later in pregnancy, reflux can also occur when the gravid uterus compresses the stomach and results in an altered LES angle or increased gastric pressure.

(Choice B) Delayed gastric emptying is common in those with poorly controlled diabetes mellitus due to autonomic neuropathy. It usually presents with nausea, vomiting, early satiety, and a sensation of postprandial fullness. Patients who have short periods of diabetes mellitus (eg, gestational diabetes) are unlikely to develop the autonomic damage that leads to delayed gastric emptying.

(Choice C) Diffuse esophageal spasm presents with difficulty swallowing solids and liquids and a sensation of food getting "stuck" in the esophagus. Pregnancy does not increase the risk of esophageal spasm.

(Choice D) *Helicobacter pylori* infection can cause gastritis and peptic ulcer disease, which typically present with epigastric or abdominal pain 2–5 hours after eating (when acid is in the stomach with no food buffer). *H pylori* is not considered a predominant cause of reflux.

(Choice E) Increased gastric acid production is seen in Zollinger-Ellison syndrome, which is caused by the secretion of gastrin from a pancreatic or duodenal neuroendocrine tumor. Patients usually have abdominal pain (from peptic ulcers) and diarrhea. Gastric acid levels are not increased in pregnancy.

Educational objective:
Pregnant women often develop gastroesophageal reflux disease (GERD) due to elevated levels of estrogen and progesterone, which relax the smooth muscle of the lower esophageal sphincter (LES). Later in pregnancy, GERD can also develop when the gravid uterus presses on the stomach and leads to an altered LES angle or increased gastric pressure.

References

- Review article: the management of heartburn in pregnancy.

meal). Later in pregnancy, reflux can also occur when the gravid uterus compresses the stomach and results in an altered LES angle or increased gastric pressure.

(Choice B) Delayed gastric emptying is common in those with poorly controlled diabetes mellitus due to autonomic neuropathy. It usually presents with nausea, vomiting, early satiety, and a sensation of postprandial fullness. Patients who have short periods of diabetes mellitus (eg, gestational diabetes) are unlikely to develop the autonomic damage that leads to delayed gastric emptying.

(Choice C) Diffuse esophageal spasm presents with difficulty swallowing solids and liquids and a sensation of food getting "stuck" in the esophagus. Pregnancy does not increase the risk of esophageal spasm.

(Choice D) *Helicobacter pylori* infection can cause gastritis and peptic ulcer disease, which typically present with epigastric or abdominal pain 2–5 hours after eating (when acid is in the stomach with no food buffer). *H pylori* is not considered a predominant cause of reflux.

(Choice E) Increased gastric acid production is seen in Zollinger-Ellison syndrome, which is caused by the secretion of gastrin from a pancreatic or duodenal neuroendocrine tumor. Patients usually have abdominal pain (from peptic ulcers) and diarrhea. Gastric acid levels are not increased in pregnancy.

Educational objective:
Pregnant women often develop gastroesophageal reflux disease (GERD) due to elevated levels of estrogen and progesterone, which relax the smooth muscle of the lower esophageal sphincter (LES). Later in pregnancy, GERD can also develop when the gravid uterus presses on the stomach and leads to an altered LES angle or increased gastric pressure.

References

- Review article: the management of heartburn in pregnancy.
- Gastroenterology consultations in pregnancy.

Pathology	Gastrointestinal & Nutrition	Gastroesophageal reflux disease
Subject	System	Topic

Copyright © UWorld. All rights reserved.

A 34-year-old man comes to the office due to 2 days of anorexia, nausea, and dark-colored urine. He travels frequently for business and recently returned from a trip to Mexico. The patient has a history of asthma and occasionally uses inhaled albuterol for symptom management. His temperature is 37.8 C (100.2 F), blood pressure is 125/70 mm Hg, and pulse is 94/min. Cardiopulmonary examination is normal. There is mild right upper quadrant abdominal tenderness with no guarding or rebound. Serologic testing for *Entamoeba histolytica* is negative. Which of the following findings is most likely to be seen on liver biopsy in this patient?

A. Fibrinoid necrosis

B. Hepatocyte swelling

C. Liquefactive necrosis

D. Malignant cells

E. Regenerative nodules

Submit

A 34-year-old man comes to the office due to 2 days of anorexia, nausea, and dark-colored urine. He travels frequently for business and recently returned from a trip to Mexico. The patient has a history of asthma and occasionally uses inhaled albuterol for symptom management. His temperature is 37.8 C (100.2 F), blood pressure is 125/70 mm Hg, and pulse is 94/min. Cardiopulmonary examination is normal. There is mild right upper quadrant abdominal tenderness with no guarding or rebound. Serologic testing for *Entamoeba histolytica* is negative. Which of the following findings is most likely to be seen on liver biopsy in this patient?

- A. Fibrinoid necrosis (6%)
- ✓ B. Hepatocyte swelling (80%)
- C. Liquefactive necrosis (5%)
- D. Malignant cells (1%)
- E. Regenerative nodules (6%)

Omitted
Correct answer
B

80%
Answered correctly

02 secs
Time Spent

01/13/2020
Last Updated

Explanation

This patient's presentation with low-grade fever, anorexia/nausea, dark-colored urine, and right upper quadrant abdominal tenderness is highly suggestive of **acute viral hepatitis**. Hepatitis A virus (HAV) is most likely responsible as it is the most common cause of acute viral hepatitis in young adults and this patient has just returned from an endemic region.

Although liver biopsy is not required to make the diagnosis, the hallmark histologic findings of acute viral hepatitis include hepatocyte necrosis and

This patient's presentation with low-grade fever, anorexia/nausea, dark-colored urine, and right upper quadrant abdominal tenderness is highly suggestive of **acute viral hepatitis**. Hepatitis A virus (HAV) is most likely responsible as it is the most common cause of acute viral hepatitis in young adults and this patient has just returned from an endemic region.

Although liver biopsy is not required to make the diagnosis, the hallmark histologic findings of acute viral hepatitis include hepatocyte necrosis and apoptosis with mononuclear infiltration. **Hepatocyte necrosis** is characterized by **cellular swelling** and **cytoplasmic emptying** (eg, "ballooning degeneration") likely caused by ATP depletion and disruption of the intermediate filament network. In severe cases, regions of adjacent lobules are interconnected by swaths of dead hepatocytes called "bridging necrosis." **Hepatocyte apoptosis** is characterized by **cellular shrinkage** and nuclear fragmentation with intense **eosinophilia** (eg, Councilman bodies) and is likely caused by mitochondrial oxidative damage. The presence of virally infected and dying hepatocytes promotes mononuclear inflammation in the sinusoids and portal tracts.

(Choice A) Fibrinoid necrosis is characterized by the deposition of amorphous, proteinaceous material in the walls of blood vessels affected by immune vasculitis or malignant hypertension.

(Choice C) Severe viral hepatitis can cause coagulative necrosis of hepatocytes. However, liquefactive necrosis classically occurs in the central nervous system due to enzymatic degradation of tissue. Amebic liver abscesses caused by *Entamoeba histolytica* infection may also produce liquefactive necrosis, but this is unlikely in the setting of negative serologic testing.

(Choice D) HAV is not associated with an increased risk of hepatocellular cancer. However, hepatitis B and C infections, aflatoxin B exposure, and all other forms of chronic hepatocyte injury are associated with increased incidence of hepatocellular carcinoma.

(Choice E) Nodular regeneration of hepatocytes is generally found in patients with cirrhosis due to chronic hepatitis. HAV does not cause chronic hepatitis, but HBV and HCV are associated with chronic hepatitis that can result in cirrhosis.

Educational objective:
Acute hepatitis due to most hepatotropic viruses causes hepatocyte ballooning degeneration and apoptosis with mononuclear cell infiltration.

References

- Ballooned hepatocytes in steatohepatitis: the value of keratin immunohistochemistry for diagnosis.
- Pathology of acute hepatitis A in humans. Comparison with acute hepatitis B.

Settings

1 2 3 4 5 6 7 8 9 10 11 12 13 14 15 16 17 18 19 20 21 22 23 24 25 26 27 28 29 30

Item 38 of 40
Question Id: 1863

Mark | Previous | Next | Full Screen | Tutorial | Lab Values | Notes | Calculator | Reverse Color | Text Zoom | Settings

This patient's presentation with low-grade fever, anorexia/nausea, dark-colored urine, and right upper quadrant abdominal tenderness is highly

Exhibit Display

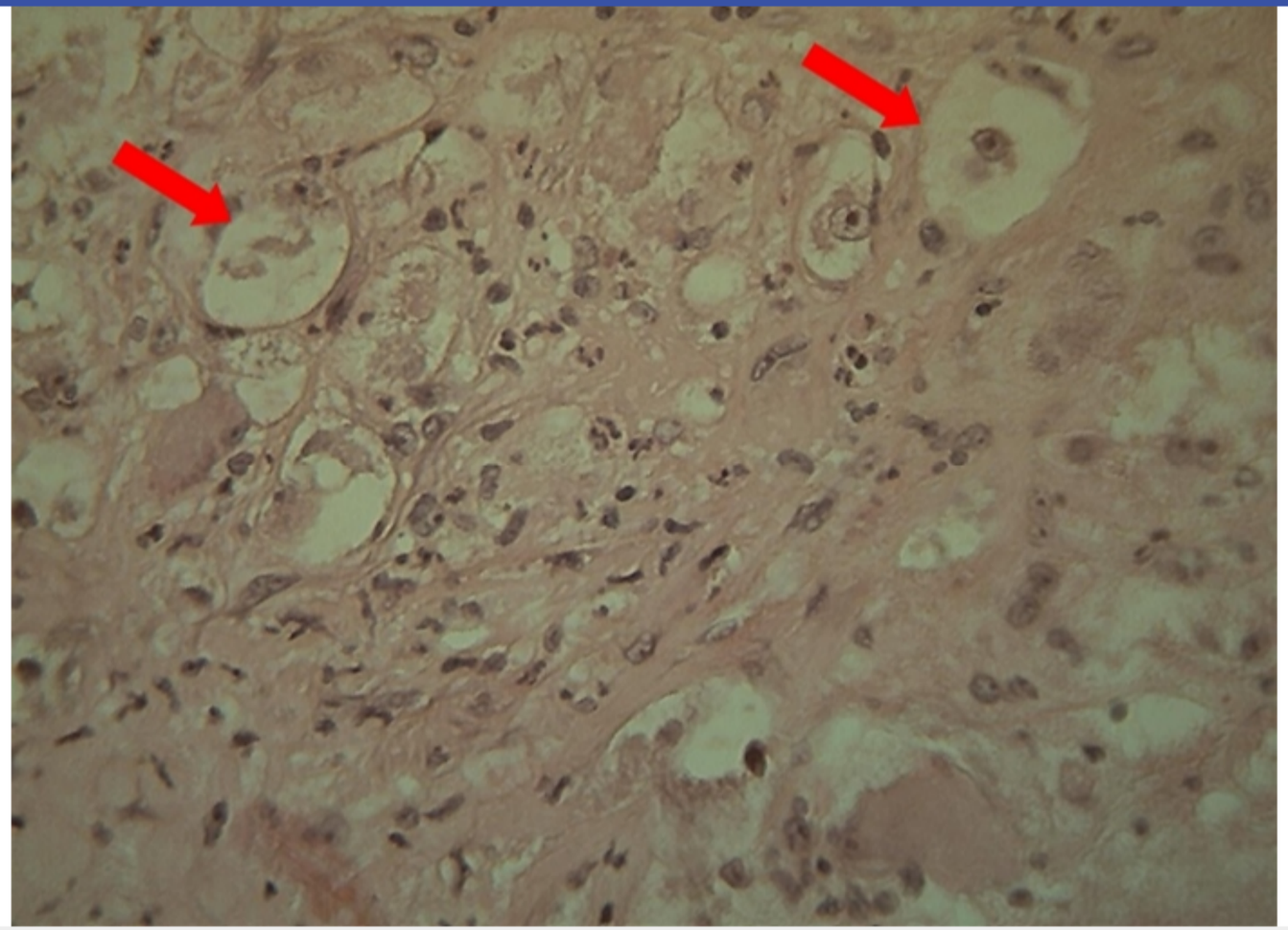

Zoom In | Zoom Out | Reset | Add To New Card | Existing Card

Block Time Remaining: 00:01:42
TUTOR

4 | Feedback | Suspend | End Block

Settings

1 2 3 4 5 6 7 8 9 10 11 12 13 14 15 16 17 18 19 20 21 22 23 24 25 26 27 28 29 30

Item 38 of 40
Question Id: 1863

Mark | Previous | Next | Full Screen | Tutorial | Lab Values | Notes | Calculator | Reverse Color | Text Zoom | Settings

This patient's presentation with low-grade fever, anorexia/nausea, dark-colored urine, and right upper quadrant abdominal tenderness is highly

Exhibit Display

Acute hepatitis Acute hepatitis

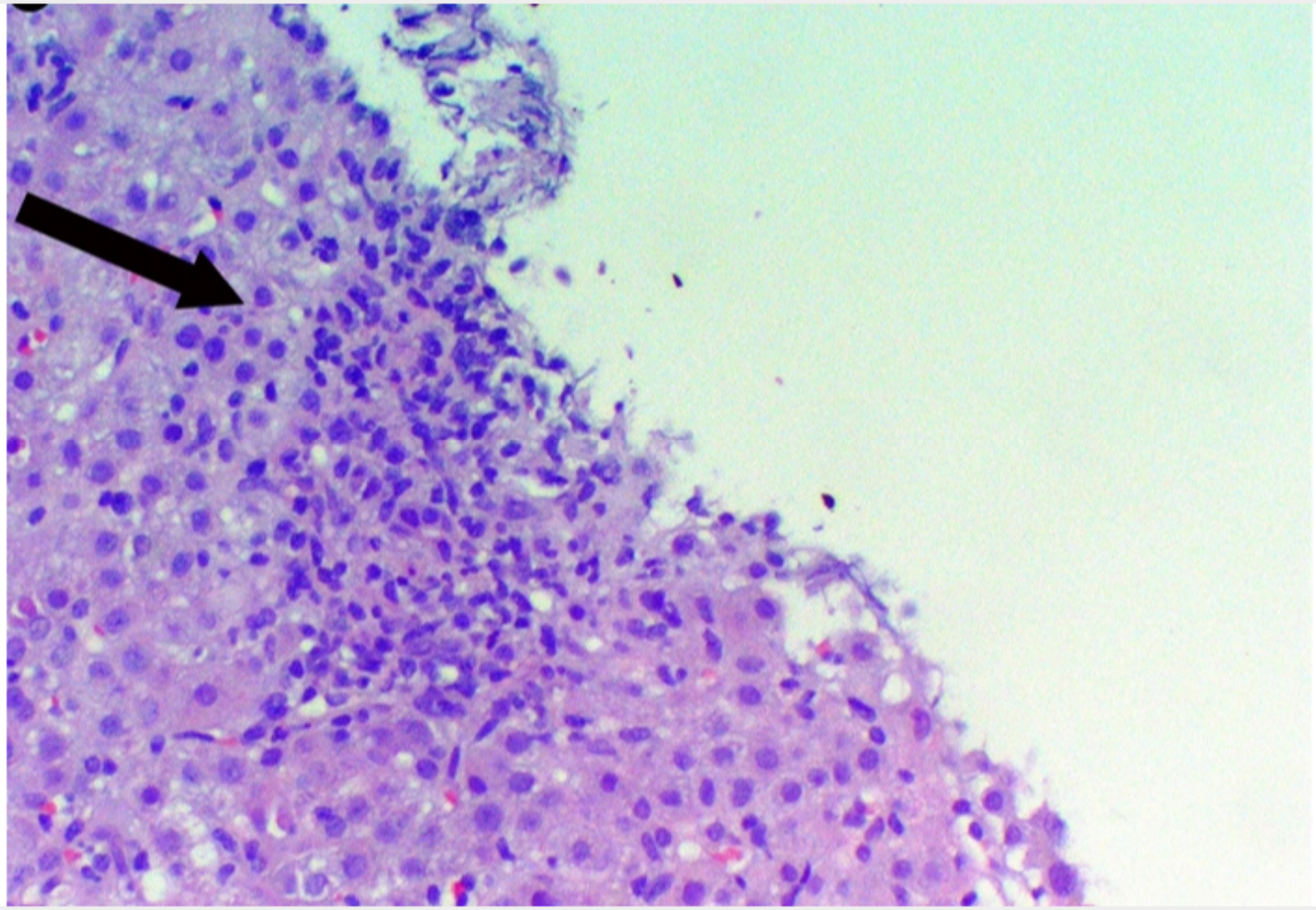

Zoom In | Zoom Out | Reset | Add To New Card | Existing Card

Block Time Remaining: 00:01:42
TUTOR

4 | Feedback | Suspend | End Block

Settings

1 2 3 4 5 6 7 8 9 10 11 12 13 14 15 16 17 18 19 20 21 22 23 24 25 26 27 28 29 30

Item 38 of 40
Question Id: 1863

Mark | Previous | Next | Full Screen | Tutorial | Lab Values | Notes | Calculator | Reverse Color | Text Zoom | Settings

This patient's presentation with low-grade fever, anorexia/nausea, dark-colored urine, and right upper quadrant abdominal tenderness is highly

Exhibit Display

Acute hepatitis Acute hepatitis

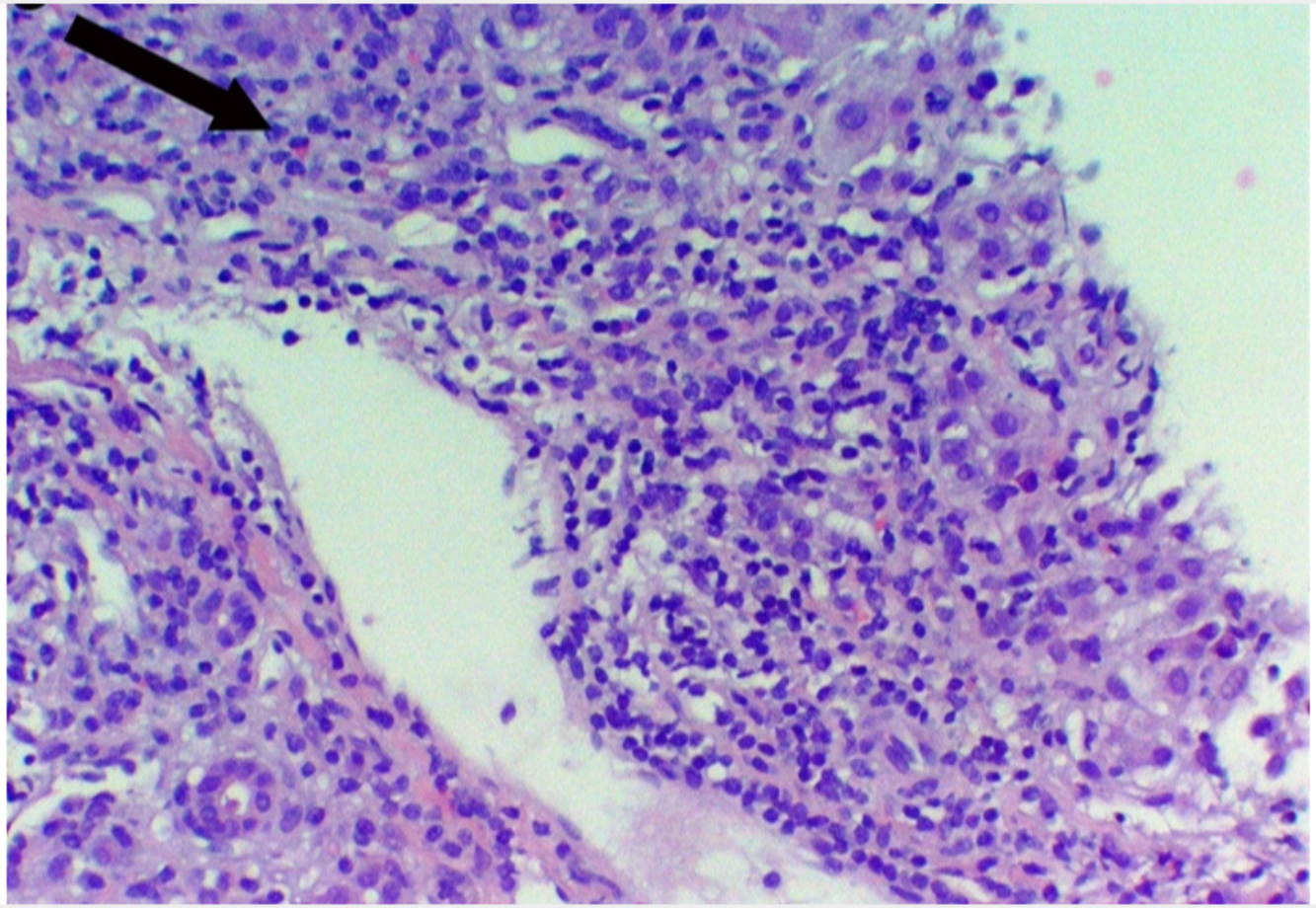

Zoom In | Zoom Out | Reset | Add To New Card | Existing Card

Block Time Remaining: 00:01:42
TUTOR

4 | Feedback | Suspend | End Block

Settings

1 2 3 4 5 6 7 8 9 10 11 12 13 14 15 16 17 18 19 20 21 22 23 24 25 26 27 28 29 30

Item 38 of 40
Question Id: 1863

Mark | Previous | Next | Full Screen | Tutorial | Lab Values | Notes | Calculator | Reverse Color | Text Zoom | Settings

This patient's presentation with low-grade fever, anorexia/nausea, dark-colored urine, and right upper quadrant abdominal tenderness is highly

Exhibit Display

Acute hepatitis Acute hepatitis

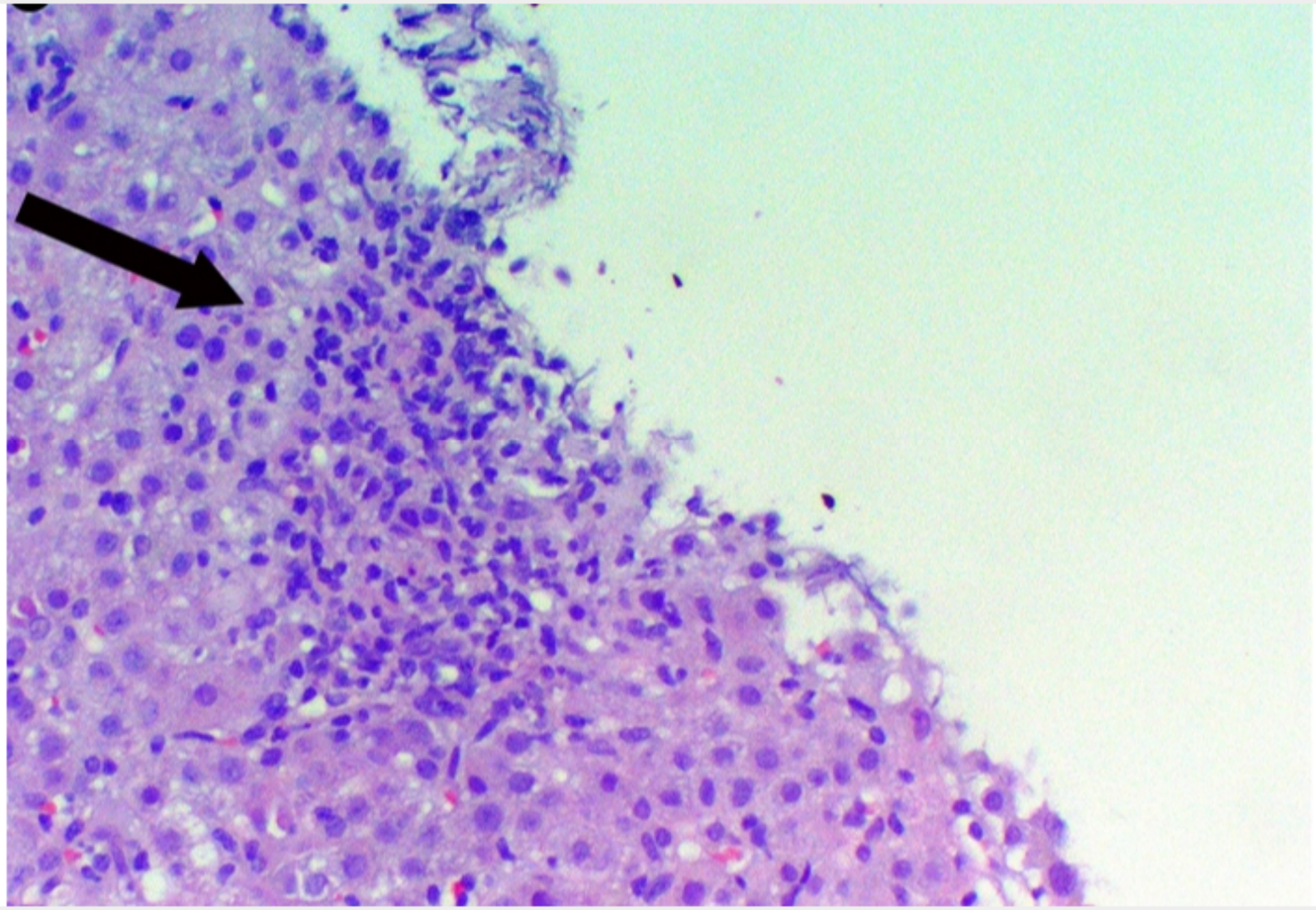

Zoom In | Zoom Out | Reset | Add To New Card | Existing Card

Block Time Remaining: 00:01:42
TUTOR

4 | Feedback | Suspend | End Block

Settings

1 2 3 4 5 6 7 8 9 10 11 12 13 14 15 16 17 18 19 20 21 22 23 24 25 26 27 28 29 30

Item 38 of 40
Question Id: 1863

Mark | Previous | Next | Full Screen | Tutorial | Lab Values | Notes | Calculator | Reverse Color | Text Zoom | Settings

This patient's presentation with low-grade fever, anorexia/nausea, dark-colored urine, and right upper quadrant abdominal tenderness is highly

Exhibit Display

Acute hepatitis Acute hepatitis

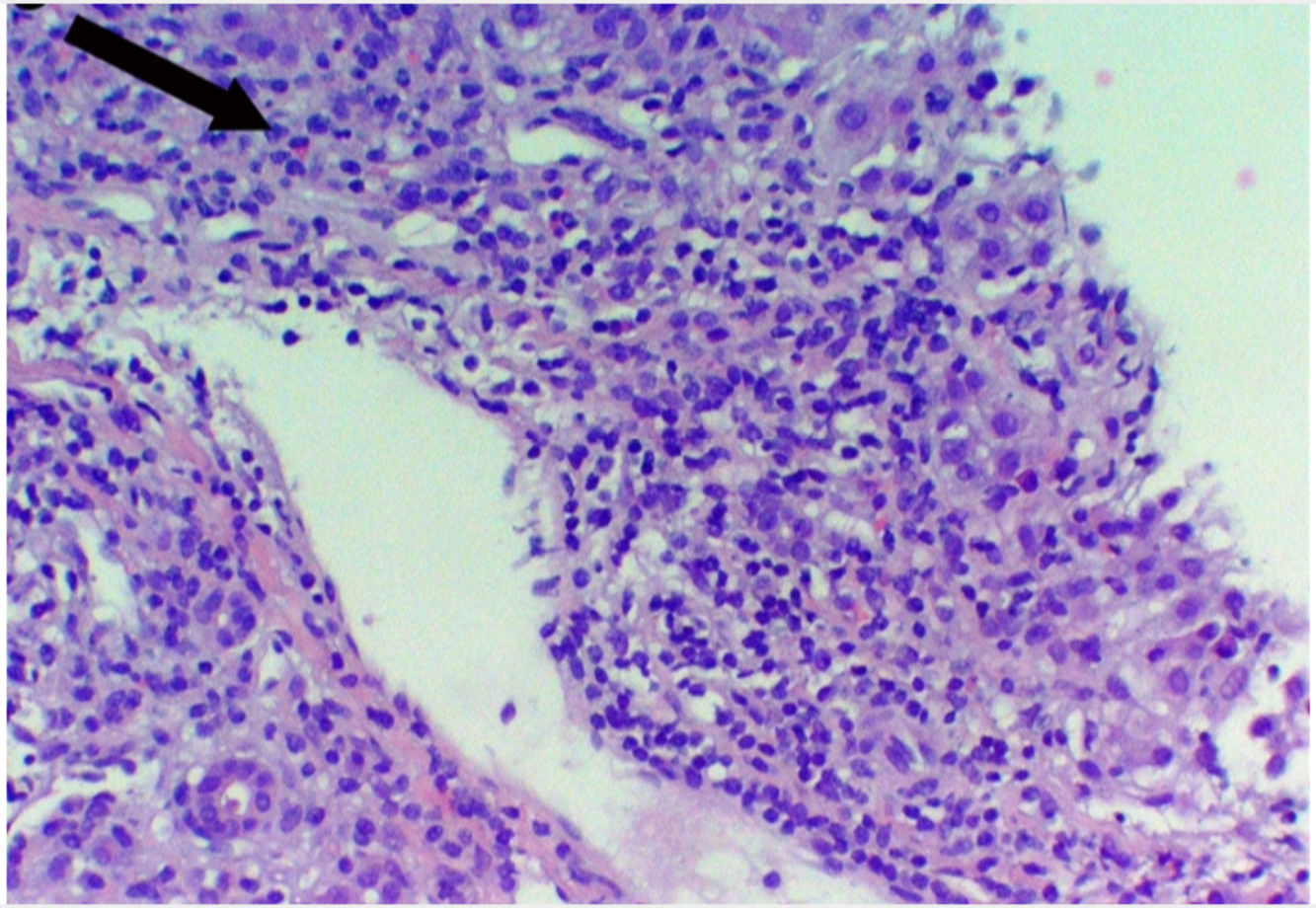

Zoom In | Zoom Out | Reset | Add To New Card | Existing Card

Block Time Remaining: 00:01:42
TUTOR

4 | Feedback | Suspend | End Block

A 69-year-old man is evaluated for abdominal pain. Upper gastrointestinal endoscopy shows a single shallow, 1-cm ulcer in the duodenal bulb and mild gastric erythema. Biopsy specimens from the gastric antrum do not show *Helicobacter pylori*, and stool testing for *H pylori* antigen is negative. Which of the following parts of the history is most likely to reveal the cause of this patient's current condition?

- A. Family history
- B. Food diary
- C. Medication use
- D. Recent travel
- E. Seasonal allergies

Submit

A 69-year-old man is evaluated for abdominal pain. Upper gastrointestinal endoscopy shows a single shallow, 1-cm ulcer in the duodenal bulb and mild gastric erythema. Biopsy specimens from the gastric antrum do not show *Helicobacter pylori*, and stool testing for *H pylori* antigen is negative. Which of the following parts of the history is most likely to reveal the cause of this patient's current condition?

- A. Family history (13%)
- B. Food diary (6%)
- ✓ C. Medication use (76%)
- D. Recent travel (2%)
- E. Seasonal allergies (0%)

Omitted
Correct answer
C

76%
Answered correctly

02 secs
Time Spent

02/12/2020
Last Updated

Explanation

NSAID-induced gastrointestinal bleeding

COX-1 inhibition

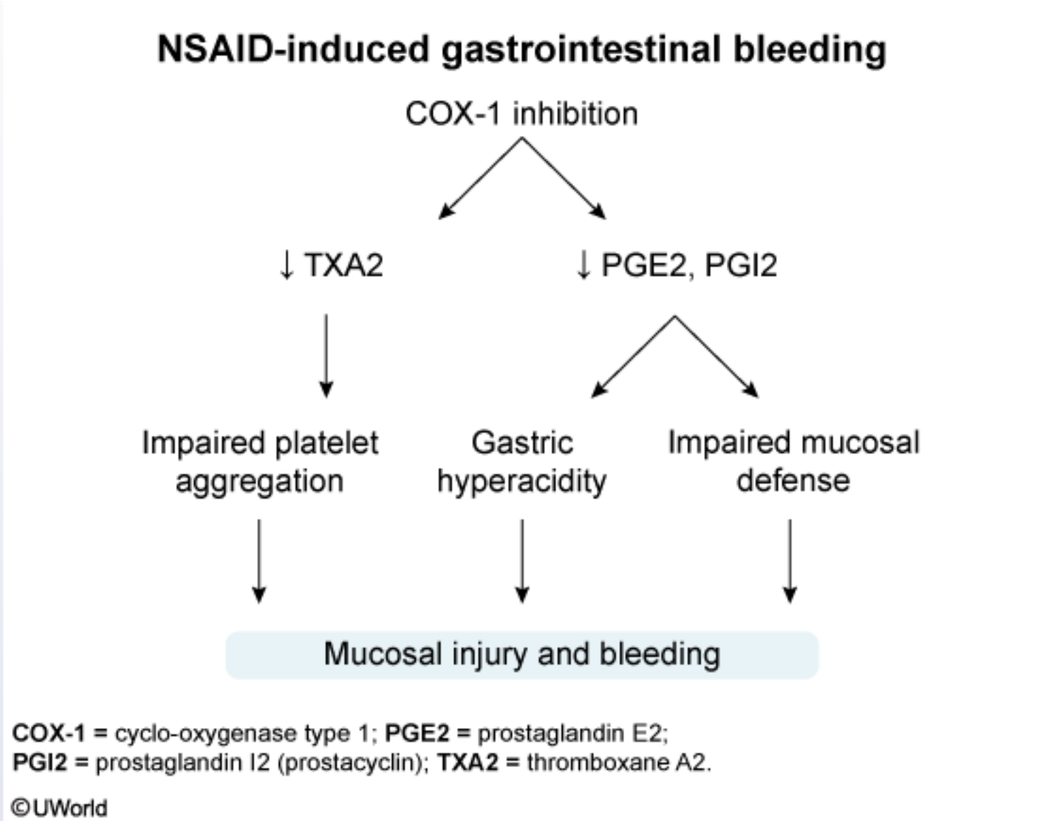

Peptic ulcers (defects in the stomach or duodenal mucosa) are most commonly due to *Helicobacter pylori* infection or **nonsteroidal anti-inflammatory drug (NSAID) use**. The majority of duodenal ulcers are associated with *H pylori* infection, but the prevalence is decreasing in the United States due to improved hygienic practices. *H pylori* has been adequately ruled out in this patient; therefore, he most likely has an NSAID-related duodenal ulcer.

Nonselective NSAIDs (eg, ibuprofen, naproxen, aspirin) exert analgesic, anti-inflammatory, and antipyretic effects through the inhibition of both forms of the cyclo-oxygenase (COX) enzyme. In the gastrointestinal tract, the COX-1 subtype is responsible for the synthesis of prostaglandins, which are critical for the maintenance of intestinal mucosa. **Inhibition of COX-1** leads to increased gastric acid formation, decreased mucosal

Peptic ulcers (defects in the stomach or duodenal mucosa) are most commonly due to *Helicobacter pylori* infection or **nonsteroidal anti-inflammatory drug (NSAID) use**. The majority of duodenal ulcers are associated with *H pylori* infection, but the prevalence is decreasing in the United States due to improved hygienic practices. *H pylori* has been adequately ruled out in this patient; therefore, he most likely has an NSAID-related duodenal ulcer.

Nonselective NSAIDs (eg, ibuprofen, naproxen, aspirin) exert analgesic, anti-inflammatory, and antipyretic effects through the inhibition of both forms of the cyclo-oxygenase (COX) enzyme. In the gastrointestinal tract, the COX-1 subtype is responsible for the synthesis of prostaglandins, which are critical for the maintenance of intestinal mucosa. **Inhibition of COX-1** leads to increased gastric acid formation, decreased mucosal bicarbonate production, and decreased mucosal blood flow, which can increase the risk for gastritis and peptic ulcer formation. Patients who are age >65 or those on long-term or high-dose NSAID therapy are at the highest risk.

(Choice A) Multiple endocrine neoplasia type 1 is a rare hereditary disorder that presents with pituitary, parathyroid, and pancreatic tumors, including gastrinomas. Gastrinomas manifest as peptic ulcer disease, but patients typically develop multiple ulcers and often have evidence of other neoplasias (eg, hypercalcemia from hyperparathyroidism, visual field defects from pituitary adenomas).

(Choices B and E) Diet and seasonal allergies are not associated with peptic ulcer disease, although certain foods (eg, spicy) may exacerbate ulcer-related dyspepsia and abdominal pain.

(Choice D) Travel to a resource-limited country increases the risk of *H pylori* infection; however, *H pylori was* ruled out in this patient.

Educational objective:
Peptic ulcers are most commonly caused by *Helicobacter pylori* infection or nonsteroidal anti-inflammatory drug (NSAID) use. NSAIDs inhibit cyclo-oxygenase-1, leading to increased gastric acid formation, decreased mucosal bicarbonate production, and decreased mucosal blood flow, which promote mucosal injury and ulcer formation.

Pathology	Gastrointestinal & Nutrition	Peptic ulcer disease
Subject	System	Topic

Copyright © UWorld. All rights reserved.

A 62-year-old man comes to the office due to worsening dysphagia. Three months ago, the patient started having difficulty swallowing large bites of solid food, and now he can swallow only liquids and mashed food. He has lost 9.1 kg (20 lb) since the onset of his symptoms. Medical history is significant for type 2 diabetes mellitus, hypercholesterolemia, and hypertension. The patient recently reduced the doses of his diabetic medications due to weight loss and normal blood sugar. He has no recent travel outside of the United States. Vital signs are normal. BMI is 29 kg/m^2. Physical examination is normal. A barium swallow study reveals an esophageal mass that significantly narrows the lumen. Endoscopic biopsy reveals moderately differentiated tumor cells with keratin nests and pearls. This patient's condition is most likely related to which of the following risk factors?

A. Alcohol consumption and tobacco smoking

B. Cold beverage consumption

C. Gastroesophageal reflux disease and esophagitis

D. *Helicobacter pylori* infection

E. Obesity and metabolic syndrome

Submit

A 62-year-old man comes to the office due to worsening dysphagia. Three months ago, the patient started having difficulty swallowing large bites of solid food, and now he can swallow only liquids and mashed food. He has lost 9.1 kg (20 lb) since the onset of his symptoms. Medical history is significant for type 2 diabetes mellitus, hypercholesterolemia, and hypertension. The patient recently reduced the doses of his diabetic medications due to weight loss and normal blood sugar. He has no recent travel outside of the United States. Vital signs are normal. BMI is 29 kg/m^2. Physical examination is normal. A barium swallow study reveals an esophageal mass that significantly narrows the lumen. Endoscopic biopsy reveals moderately differentiated tumor cells with keratin nests and pearls. This patient's condition is most likely related to which of the following risk factors?

- ✓ A. Alcohol consumption and tobacco smoking (88%)
- B. Cold beverage consumption (0%)
- C. Gastroesophageal reflux disease and esophagitis (9%)
- D. *Helicobacter pylori* infection (0%)
- E. Obesity and metabolic syndrome (1%)

Omitted
Correct answer
A

88%
Answered correctly

01 sec
Time Spent

04/30/2020
Last Updated

Explanation

Risk factors for esophageal cancer	

Risk factors for esophageal cancer	
Squamous cell carcinoma	**Adenocarcinoma**
• Alcohol use • Tobacco smoking • N-nitroso–containing foods • Underlying esophageal disease (achalasia, prior injury)	• Barrett esophagus • Gastroesophageal reflux disease • Obesity • Tobacco use

This patient has **squamous cell carcinoma** (SCC), which is characterized by flattened polyhedral or ovoid epithelial cells with eosinophilic cytoplasm, keratin nests or "pearls" within or between cells, and intercellular bridging. Esophageal squamous cell carcinoma typically presents with progressive solid-food dysphagia and weight loss. Chronic gastrointestinal blood loss may result in iron deficiency anemia.

The incidence of esophageal SCC is decreasing in the United States, with the highest incidence occurring in middle-aged and older individuals (age >50) of African heritage. The most significant risk factors for SCC in the United States include **cigarette smoking** and **alcohol intake**. In Asia, the chewing of betel nuts and consumption of foods containing N-nitroso compounds (often found in preserved or pickled vegetables) are commonly associated with SCC. Other risk factors include preexisting esophageal disease (eg, achalasia, caustic injury) and ingestion of high-temperature liquids **(Choice B)**.

(Choice C) Chronic gastroesophageal reflux disease and esophagitis can lead to Barrett metaplasia and can increase the risk for esophageal adenocarcinoma.

(Choice D) *Helicobacter pylori* infection, a common cause of gastritis, is associated with an increased risk of gastric adenocarcinoma. However, it is not associated with increased risk of the development of Barrett esophagus, esophageal adenocarcinoma, or esophageal SCC.

(Choice E) Obesity and metabolic syndrome are associated with increased risk of esophageal adenocarcinoma, likely because of increased acid reflux into the esophagus due to anatomic abnormalities.

Educational objective:
Major risk factors for esophageal squamous cell carcinoma include smoking, excessive alcohol consumption, and intake of foods containing N-

Settings

1 2 3 4 5 6 7 8 9 10 11 12 13 14 15 16 17 18 19 20 21 22 23 24 25 26 27 28 29 30

Item 40 of 40
Question Id: 122

Mark | Previous | Next | Full Screen | Tutorial | Lab Values | Notes | Calculator | Reverse Color | Text Zoom | Settings

Exhibit Display

Keratinizing invasive squamous cell carcinoma

© UWorld

Zoom In | Zoom Out | Reset | Add To New Card | Existing Card

Block Time Remaining: 00:01:45
TUTOR

4 | Feedback | Suspend | End Block

1 2 3 4 5 6 7 8 9 10 11 12 13 14 15 16 17 18 19 20 21 22 23 24 25 26 27 28 29 30

Exhibit Display

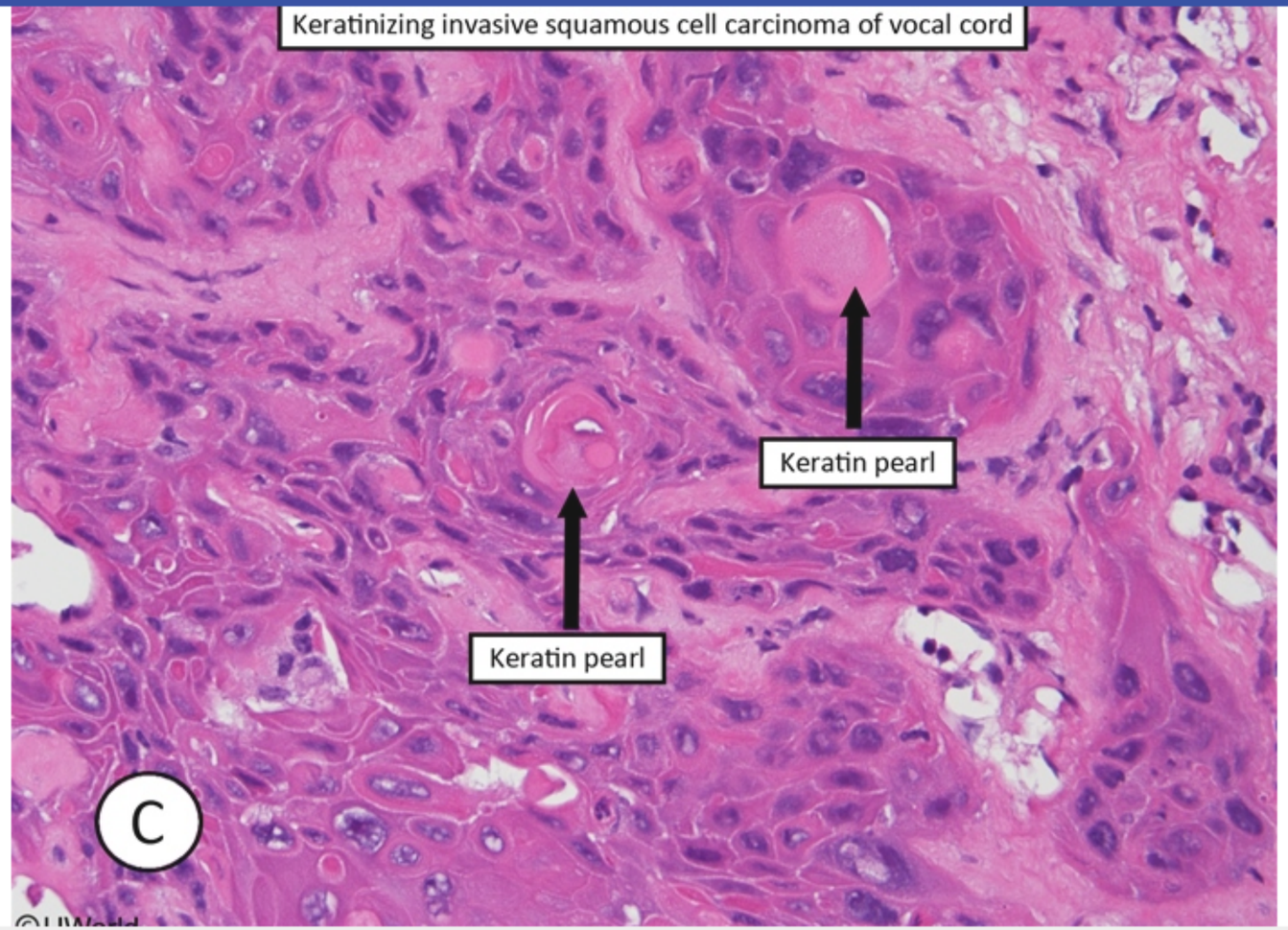

Zoom In | Zoom Out | Reset | Add To New Card | Existing Card

cytoplasm, keratin nests or "pearls" within or between cells, and intercellular bridging. Esophageal squamous cell carcinoma typically presents with progressive solid-food dysphagia and weight loss. Chronic gastrointestinal blood loss may result in iron deficiency anemia.

The incidence of esophageal SCC is decreasing in the United States, with the highest incidence occurring in middle-aged and older individuals (age >50) of African heritage. The most significant risk factors for SCC in the United States include **cigarette smoking** and **alcohol intake**. In Asia, the chewing of betel nuts and consumption of foods containing N-nitroso compounds (often found in preserved or pickled vegetables) are commonly associated with SCC. Other risk factors include preexisting esophageal disease (eg, achalasia, caustic injury) and ingestion of high-temperature liquids **(Choice B)**.

(Choice C) Chronic gastroesophageal reflux disease and esophagitis can lead to Barrett metaplasia and can increase the risk for esophageal adenocarcinoma.

(Choice D) *Helicobacter pylori* infection, a common cause of gastritis, is associated with an increased risk of gastric adenocarcinoma. However, it is not associated with increased risk of the development of Barrett esophagus, esophageal adenocarcinoma, or esophageal SCC.

(Choice E) Obesity and metabolic syndrome are associated with increased risk of esophageal adenocarcinoma, likely because of increased acid reflux into the esophagus due to anatomic abnormalities.

Educational objective:
Major risk factors for esophageal squamous cell carcinoma include smoking, excessive alcohol consumption, and intake of foods containing N-nitroso compounds.

References

- Alcohol drinking, cigarette smoking, and the development of squamous cell carcinoma of the esophagus: Epidemiology, clinical findings, and prevention.

Pathology	Gastrointestinal & Nutrition	Esophageal cancer
Subject	System	Topic

Copyright © UWorld. All rights reserved.